महाराष्ट्र वन विभाग

ONLINE INTERNATIONAL CONFERENCE: WILDCON-2020

Insights into wildlife conflicts, rescue and rehabilitation: Challenges & Opportunities for conservation

&

14th Annual Convention of Association of Indian Zoo and Wildlife Veterinarians

WILDCON 2020

18- 20 December, 2020

Souvenir & Abstracts

Organized by

Wildlife Research & Training Centre, Gorewada Nagpur
Maharashtra Animal & Fishery Sciences University, Nagpur
Forest Development Corporation of Maharashtra Ltd, Nagpur
Department of Forest, Government of Maharashtra
Association of Indian Zoo and Wildlife Veterinarians (AIZ&WV)

MAHARASHTRA ANIMAL & FISHERY SCIENCES UNIVERSITY, NAGPUR

WILDLIFE RESEARCH & TRAINING CENTRE,

FOREST DEVELOPMENT CORPORATION OF MAHARASHTRA

GOREWADA RESCUE CENTRE, GOREWADA, NAGPUR

महाराष्ट्र वन विभाग

ONLINE INTERNATIONAL CONFERENCE: WILDCON-2020

Insights into wildlife conflicts, rescue and rehabilitation: Challenges & Opportunities for conservation

&

14th Annual Convention of Association of Indian Zoo and Wildlife Veterinarians

WILDCON 2020

18- 20 December, 2020

Souvenir & Abstracts

Organized by

Wildlife Research & Training Centre, Gorewada Nagpur
Maharashtra Animal & Fishery Sciences University, Nagpur
Forest Development Corporation of Maharashtra Ltd, Nagpur
Department of Forest, Government of Maharashtra
Association of Indian Zoo and Wildlife Veterinarians (AIZ&WV)

BHAGAT SINGH KOSHYARI
GOVERNOR OF MAHARASHTRA

सत्यमेव जयते

RAJ BHAVAN
Malabar Hill
Mumbai 400 035
Tel. : 022-2363 2660
Fax. : 022-2368 0505

09 December 2020

MESSAGE

I am pleased to know that the Wildlife Research and Training Centre (WRTC), Gorewada Rescue Centre and the Association of Indian Zoo and Wild life Veterinarians (AIZ &WV) are jointly organizing 'WILDCON 2020' – an Online International Conference on 'Insights into Wildlife Conflicts, Rescue and Rehabilitation: Challenges and Opportunities for Conservation' and the 14th Annual Convention of AIZ & WV during December 18-20, 2020.

It is gratifying to note that the Conference is aimed at bringing expertise in the arena of wildlife on a common platform. I am sure, the discussion at 'WILDCON 2020' will allow professionals working in different parts of the world to share their experience with fellow participants. With shrinking areas of forests, there have been growing incidents of man-animal conflict. It is necessary to create safe and caring spaces for wildlife so as to minimize such conflict and conserve wildlife.

I congratulate the organizers of 'WILDCON 2020' and wish the participants fruitful deliberations.

(Bhagat Singh Koshyari)

सत्यमेव जयते

DEPUTY CHIEF MINISTER
MAHARASHTRA STATE

Date: 10 Dec, 2020

MESSEGE

I am glad to be informed that Maharashtra Animal & Fishery Sciences University, Nagpur through Wildlife Research & Training Centre, Nagpur and Associates of India Zoo and Wildlife Veterinarians (AIZ & WV) is organizing Online International Wildlife Conferences WILDCON 2020 &14th Annual Convention of Association of Indian Zoo and Wildlife Veterinarians (AIZ & WV) during 18-20 December , 2020.

Maharashtra Animal & Fishery Sciences University, Nagpur has contributed immensely to the advancement of veterinary science in the state of Maharashtra. I am happy to see them contribute to the cause of Wildlife in the state of Maharashtra. Vidharbha region of Maharashtra is home to many endangered species of Wildlife. As a result the location of Wildlife Research & Training Centre, Nagpur in the campus of Gorewada Wildlife Rescue Centre has proved to be a boon to the wildlife in distress.

I hope the discussions and inputs provided by the expert gathering will advance therapy and practices pertaining to wildlife in the country.

My best wishes to the Online International Wildlife Conference WILDCON 2020.

(Ajit Pawar)

जा.क्र.मा. मंत्री/पशुसं, दुग्धवि, क्रिडा व युवक कल्याण / नागपूर/ /२०२०
2927

सत्यमेव जयते

SUNIL KEDAR
MINISTER
Animal Husbandry, Dairy Development, Sports and Youth Welfare

4th December, 2020

MESSAGE

I am extremely delighted to learn about the organization of Online International Wildlife Conference WILDCON 2020 by Wildlife Research & Training Centre, Gorewada, Nagpur under the patronage of Maharashtra Animal and Fishery Sciences University, Nagpur. The University has always been in the forefront in facilitating novel projects and ideas in Animal Husbandry Sector. I am happy to see the university furthering the cause of wildlife protection by organizing WILDCON 2020.

I am excited to see MAFSU's Wildlife Research & Training Centre, Gorewada, Nagpur excel in care, management, rehabilitation of wildlife at Govewada Rescue Centre, Nagpur. The confluence of MAFSU, Nagpur and FDCM Ltd., Nagpur has brought technical knowledge, skill and ultimate beneficiaries under one roof. The success of the project to deliver in arena of wildlife conservation is highly encouraging.

Wildlife conservation is the need of the hour. Fast reclining species of wildlife are in need of a patronage to save them from being extinct. There is a need to scientifically intervene for the subsistence of species that are fast approaching extinction. There is a definite deficite of knowledge in the habitat, conservation and disease of wildlife, basic research in the areas will further the understanding of the interventions to be undertaken to save a reclining species.

Professionals from different background must collaborate and understand their role in the field of wildlife conservation. An online conference is a great podium for experts all around the world to discuss issues of concern and provide solutions for the same. I am hopeful that the scientific discussions undertaken in the Conference will provide important inputs for the management of wildlife in the wild.

I extend my sincere best wishes to the team of WILDCON 2020.

(Sunil Kedar)

Office : Room No. 201, Mantralaya, Mumbai - 400 032.
☎ : Mumbai Office:022-22831983, 022-22025313 Nagpur Office:0712- 2720611, 2726508
sunil.kedar@gov.in www.maharashtra.gov.in

सत्यमेव जयते

Sanjay Dulichand Rathod
Minister
Forest, Earthquake Rehabilitation
Government of Maharashtra

MESSAGE

Warm Greetings.

I am extremely happy to comprehend that Wildlife Research & Training Centre, Nagpur under the auspices of Maharashtra Animal & Fishery Sciences University, Nagpur, FDCM Ltd., Nagpur and Association of Indian Zoo and Wildlife Veterinarians (AIZ & WV) have announced the organization of Online International Wildlife Conference WILDCON 2020 during 18-20 December, 2020. I am extremely happy to know that Department of Forest, Government of Maharashtra is a collaborating partner in this event.

I am glad to know that the conference has decided to embrace the theme on rescue, conflict, and rehabilitation of wildlife. I must put on records the contribution of Maharashtra Animal & Fishery Sciences University, Nagpur through Wildlife Research & Training Centre in the management of conflict animals at Wildlife Rescue Centre, Gorewada. The impeccable spirit to serve the wildlife under distress is clearly evident. Wildlife Research & Training Centre, Gorewada, Nagpur is confluence of MAFSU, Nagpur and Forest Development Corporation of Maharashtra Ltd., Nagpur. The success of Veterinary University and Forest Department Model will give impetus to health care, management and research in wildlife which is very encouraging.

Wildlife conservation is a social responsibility and until conservation becomes a peoples' movement it cannot meet its ends. Professionals like veterinarians, biologists, ecologists, zoologists, scientists etc. need to collaborate and provide precious inputs on the ways to preserve the dwindling biodiversity. A conference like this can provide a platform to scientifically discuss and share the possibilities of positive interventions for wildlife conservation.

I am satisfied to see an array of speakers from world's best zoos and wildlife parks addressing the gathering of professionals. The world has come closer due to technology interventions and I am glad that Wildlife Research & Training Centre is utilizing this to the benefit of propagation of knowledge during the ongoing COVID-19 pandemic.

I wish the team of Organizers the very best for WILDCON 2020.

(Sanjay Rathod)

Office : Room No. 601- 602, 6th Floor, Annex, Mantralaya, Mumbai - 400032. ☎ : 022- 22886188 / 22886093
Resi.: 022 22817064 / 22817078 **Yavatmal:** 07232 - 243334 **Fax:** 240428 **E-mail:** forestsminister2020@gmail.com

by Post

राज्यमंत्री/सा.बां.,मृद व जलसंधारण,वने,
प.दु.म.,सा.प्र./नोट/१२३६/२०२०

MINISTER OF STATE
PUBLIC WORKS (EXCLUDING PUBLIC UNDERTAKINGS), SOIL AND WATER CONSERVATION, FORESTS, ANIMAL HUSBANDRY, DAIRY DEVELOPMENT AND FISHERIES, GENERAL ADMINISTRATION
MAHARASHTRA STATE
Mantralaya, Mumbai 400 032
www.maharashtra.gov.in

Date : 09 DEC 2020

MESSAGE

I am extremely pleased to learn that Wildlife Research & training Center, Nagpur under the auspices of Maharashtra Animal & Fishery Sciences University, Nagpur and its collaborating partners along with Association of Indian Zoo and Wildlife Veterinarians (AIZ & WV) is organizing Online International Wildlife Conference WILDCON 2020 & 14th Annual Convention of Association of Indian Zoo and Wildlife Veterinarians (AIZ & WV) during 18-20 December, 2020.

Maharashtra is known for its forest and wildlife wealth throughout the country. The tiger reserves and national parks of Maharashtra paint the state with beauty and elegance. It is home to many species of birds and mammals. Recent tiger census of 2018 indicated that there are over 300 tigers in Maharashtra which is a very encouraging sign for the entire state. It is an added honour for me recognize the efforts of Maharashtra Animal & fishery Sciences University, Nagpur and Department of Forest, Government of Maharashtra in creation of Wildlife Research & Training Centre, Gorewada, Nagpur for the advantage of wildlife throughout the state.

Education and extension are important facets of the activities of Wildlife Research & Training Centre, Gorewada, Nagpur. Professional education and development of skilled manpower is extremely important for sustainable conservation efforts. With the advent of technology the world has come closer, and I am appreciate the efforts taken to organize the Online International Wildlife Conference WILDCON 2020 for the advancement of knowledge and skill of professionals engaged in wildlife conservation.

I congratulate the organizers for thoughtfully having a separate session on conservation biotechnology and forensics. In the current era where biotechnology has revolutionized agriculture and health care, wildlife has a lot to expect from the growing field. The list of speakers has authorities in the subject from all over the world.

I hope it will be a great learning opportunity for professionals engaged in wildlife conservation. I congratulate Wildlife Research & Training Centre, Gorewada, Nagpur for this novel initiative in the times of ongoing pandemic COVID-19. I wish you the best for WILDCON 2020.

(Dattatray Bharane)

महाराष्ट्र पशु व मत्स्य विज्ञान विद्यापीठ

फुटाळा तलाव मार्ग, नागपूर - 440001

MAHARASHTRA ANIMAL AND FISHERY SCIENCES UNIVERSITY

Futala Lake Road, Nagpur – 440001, Maharashtra (India)

Phone: +91 712 2511088, 712 2511282 Email: vcmafsu@gmail.com, Web: www.mafsu.in

कर्नल (डॉ.) प्रा. आशिश पातुरकर

कुलगुरू

आणि कर्नल कमांडन्ट एन.सी.सी., माफसू

Col (Dr.) Prof. A. M. Paturkar

M.V.Sc., Ph.D., FIAVPHS, FNAVS

Vice Chancellor

& Colonel Commandant NCC, MAFSU

MESSAGE

I am extremely happy to note that Wildlife Research & Training Centre and Association of Indian Zoo and Wildlife Veterinarians (AIZ & WV) is jointly organizing "WILDCON 2020" Online International Conference on "Insights into wildlife conflicts, rescue and rehabilitation: Challenges and Opportunities for Conservation" & 14th Annual Convention of Association of Indian Zoo and Wildlife Veterinarians (AIZ & WV) during 18th to 20th December 2020.

The conference intends to showcase the current challenges and opportunities in wildlife healthcare and management. The main objective of the conference is to bring expertise working in the area of wildlife under one roof and facilitate a consequential dialogue to streamline conservation efforts. The theme of the conference is prudent to allow professionals working in different parts of the world to share their expertise and experience with fellow mates.

Under the current COVID-19 pandemic restrictions organization of an online conference highlighting the challenges and opportunities in wildlife conservation needs to be appreciated.

It is heartening to know that key speakers from various institute of national and international repute have consented to address diverse gathering of professionals from around the world. I am sure that the deliberations made in this conference would provide a road map for future conservation of wild life and animal welfare.

I extend my warm greetings to the Organizing Committee and wish the conference all success.

(A. M. Paturkar)

दाऊ श्री वासुदेव चंद्राकर कामधेनु विश्वविद्यालय
दुर्ग 491001 (छत्तीसगढ़)
DAU SHRI VASUDEV CHANDRAKAR VISHWAVIDYALAYA
DURG 491001 (CHHATTISGARH)

Ph. : +91-788-2623462
E-mail : vccgkv2012@gmail.com

डॉ. एन.पी. दक्षिणकर
कुलपति
Dr. N.P. DAKSHINKAR
Vice Chancellor

No. HVC/DO/62

Date.10/12/2020

Dear Organizers,

Warm Compliments,

I am extremely delighted to understand that Wildlife Research & Training Centre, Gorewada, Nagpur is hosting Online International Wildlife Conference WILDCON-2020 during 18-20 December, 2020. As a Founder Member and Principal Investigator of the project I am content to see the rise of a dream that was borne by me and my like-minded associates.

The idea in propounding foundation of this novel centre is implying the very principles of 'One Health' for greater public good. Veterinarians are important professionals engaged in the noble cause of wildlife conservation. With a numerous native species of wild animals inching towards extinction, Veterinarians have to step up and contribute to the cause of conservation. Wildlife Research & Training Centre also propagates the philosophy of extension of technical expertise to the professionals engaged at the grass root by capacity building.

In this regard, Online International Conference WILDCON 2020 is a matter of pride and enthusiasm to all associated with it. I congratulate the team for coming up with a novel idea for the exchange of knowledge at international level. In this extraordinary time of COVID-19 an Online conference will provide a stage for efficient exchange of thoughts and will help the cause of wildlife conservation. I also understand that speakers from eminent institution of research in wildlife are participating as presenters, which is a great opportunity for young minds to be inspired.

I wish the organizers of Online International Wildlife Conference WILDCON-2020 the very best for this innovative and novel project.

With Best Wishes.....

(N. P. Dakshinkar)

TAMIL NADU VETERINARY AND ANIMAL SCIENCES UNIVERSITY

Madhavaram Milk Colony, Chennai - 600 051, India

Dr. C.BALACHANDRAN, M.V.Sc., Ph.D., PGDAJ., PGDEVP., DICVP, FAO Fellow, FIAVP, FNAVS, FASAW.

VICE-CHANCELLOR

MESSAGE

I am happy to note that Wildlife Research & Training Centre, Gorewada under the auspices of Maharashtra Animal & Fishery Sciences University, Nagpur and Association of Indian Zoo and Wildlife Veterinarians is organizing an Online International Wildlife Conference "WILDCON 2020 and 14th Annual Convention of AIZ&WA" during 18-20 December 2020 with the theme "Insights into Wildlife Conflicts, Rescue and Rehabilitation, Challenges and Opportunities for Conservation".

I understand that the Wildlife Research & Training Centre, Gorewada is doing the best work in wildlife research in areas of behaviour, clinical science and basic science, with state-of-the-art-facilities in trauma care and rehabilitation.

Considering the major threats to wildlife which include habitat destruction, pollution and climate change and also extinction of many species of animals, this conference may be helpful in addressing the challenges to wildlife animals.

I hope the deliberations of the conference will be useful in conserving the Wildlife population and I wish the event a great success.

I take this opportunity to congratulate the organizing team for the conduct of "WILDCON 2020 and 14th Annual Convention of AIZ&WA".

Date : 07.12.2020
Place : Chennai

(C. BALACHANDRAN)
VICE-CHANCELLOR

Telephone (O) : 0091-44-25551574 / 75 Fax : 0091-44-25551576
Email : vc@tanuvas.org.in; Website : www.tanuvas.ac.in

Kamdhenu University

Our Motto : Welfare of all living beings

(Established by Government of Gujarat vide Gujarat Act No. 9 of 2009)

Dr. N. H. Kelawala
Vice Chancellor

Message for e-Compendium

Online International Wildlife e-Conference 'WILDCON 2020'

December 18-20, 2020

I am glad to read about 'WILDCON 2020' International e-Conference to be held during December 18-20, 2020 under the aegis of MAFSU, Nagpur along with Forest Department, Maharashtra, AIZ&WA and others, I congratulate the organisers for conceptualizing this event.

WRTC, Gorewada, Nagpur is an unique centre catering facilities for molecular and clinical wildlife research, trauma care and rehabilitation of wild animals etc. This Centre located in central India, warrants to be replicated at other four zones of our country. This will facilitate to develop an ecosystem which nurtures Veterinarians and other professionals, dedicated to wildlife, without attrition and develop desirable skill sets.

I am sure policy makers, wildlife experts will dwell on this topic at length to develop and sustain an ecosystem which follows World Organisation for Animal Health (OiE) and International Union for Conservation of Nature (IUCN) guidelines in letter and spirit. In view of COVID-19 pandemic, it is prudent to strictly adhere to the guidelines and follow protocols developed by OiE & IUCN.

I wish "WILDCON - 2020" a grand success !

Jai Hind.

8.12.2020

(N. H. Kelawala)

Karmayogi Bhavan, Block-1, Wing B-1, 4th Floor, Sector 10-A, Gandhinagar – 382010
www.ku-guj.org, E-mail : vc.kamdhenu.university@gmail.com, vc@ku-guj.com
Ph. (O) 079-23220712, Mo. : +91 75730 35101

KERALA VETERINARY & ANIMAL SCIENCES UNIVERSITY

Pookode, Lakkidi. P.O., Wayanad, Kerala - 673 576

Prof.(Dr.) M.R. SASEENDRANATH
M.V.Sc., Ph.D., F.N.A.V.Sc., F.I.S.V.M.
VICE - CHANCELLOR

Phone No : 04936 - 209209, 210
Mobile No : +91 9447236514

MESSAGE

Greetings from Kerala Veterinary and Animal Sciences University!

It is a matter of immense pleasure that WRTC, Gorewada, is organizing an Online International Wildlife Conference, WILDCON 2020, under the auspices of MAFSU, Nagpur, and AIZ&WV during December 18th to 20th. The theme identified for the conference, ie. Human-wildlife conflict, and wildlife rescue and rehabilitation in the context of conservation, is most appropriate for current times when interactions between humans and wild animals are on the rise worldwide, resulting in disease and casualties at each side. These interactions are of special importance in a country like India, with the expanding needs of our growing human population causing an escalation of tensions at the interface between human settlements and our biodiversity rich natural ecosystems. COVID-19 brings to the limelight the importance of these interactions from a disease emergence perspective also, in addition to commonly recognized socio-economic impacts.

There is an urgent requirement for truly multidisciplinary One Health Action, based on social welfare and sustainable development of people, at the human-wild animal-ecosystem interface in all forests and biodiversity rich regions of our country. Scientific methods to reduce the intensity of human-wildlife interactions, disease screening of injured and sick wild animals being rescued and rehabilitated, as well as wildlife forensics, have complementary roles to play in ensuring the health and sustainable development of humans, as the world has learned during the current pandemic.

I extend my wholehearted goodwill and blessings for the success of WILDCON 2020. May this international conference bring the best minds in the identified theme areas together and spread the light of the urgent need for scientific multidisciplinary interventions at the human-wild animal-ecosystem interface, so that our future generations will live healthy lives on a healthier planet.

12/2020

Prof. (Dr). M.R. Saseendranath,
Vice Chancellor

OFFICE OF THE
PRINCIPAL CHIEF CONSERVATOR OF FORESTS
(HEAD OF FOREST FORCE)
MAHARASHTRA STATE
'Vanbhavan', Ramgiri Road, Civil Lines, Nagpur-440 001

Dr. N. Rambabu, IFS
Principal Chief Conservator of Forests
(Head of Forest Force)
Maharashtra State

Dear Organizers,

Warm compliments.

I am extremely happy to understand that Wildlife Research & Training Centre, Gorewada, Nagpur is hoisting Online International Wildlife Conference WILDCON-2020 on 18th& 19th December, 2020. Wildlife Research & Training Centre has been established by a Memorandum of Understanding between Maharashtra Animal & Fishery Sciences University, Nagpur & Forest Development Corporation of Maharashtra Ltd., Nagpur in 2014. Currently, the centre has its campus in the Wildlife Rescue Centre, Gorewada, Nagpur and is one of its kind in the country. The centre has played a vital role in the management, treatment and rehabilitation of wildlife in the entire region. I also would like to put on records the exemplary work of the centre in hand rearing orphans received from the entire state of Maharashtra.

I consider myself very fortunate to have the opportunity to work with the founding members of the centre who conceptualized a specialized centre for the noble cause of wildlife rescue and rehabilitation. Since the approval of the project by Government of Maharashtra to establishment of a centre in the campus of Gorewada Rescue Centre, the centre has come a long way. The confluence of Department of Forest and MAFSU, Nagpur has been fruitful in saving the wildlife in distress.

Research and training are an integral part of the mandate of WRTC, Gorewada, Nagpur. The centre has been a flag bearer in the propagation of knowledge and technical know-how in the field of Wildlife Health & Management. The centre has prudently utilized online platforms to further the cause of knowledge amongst the wildlife veterinarians, administrators, wildlife lovers etc. I am sure in the coming years the centre will be a leading seat of research & training in the country.

In this regard, Online International Conference WILDCON 2020 is a matter of pride and enthusiasm to all associated with it. I congratulate the team for coming up with a novel idea for the exchange of knowledge at international level. In this extraordinary time of COVID-19 an Online conference will provide a stage for efficient exchange of thought and will help the cause of wildlife conservation. I also understand that speakers from eminent institution of research in wildlife are participating as presenters which is a great opportunity for young minds to be inspired.

I wish the organizers of Online International Wildlife Conference WILDCON-2020 the very best for this innovative and novel project.

With Best wishes.

(Dr. N. Rambabu)

Nitin H. Kakodkar, IFS
Principal Chief Conservator of Forests (Wildlife)
Maharashtra State

Office of the Principal Chief Conservator of Forests (Head of Forest Force),
Maharashtra State Nagpur
Vanbhavan, Ramgiri Road,Civil Lines, Nagpur-440 001

Warm Wishes,

India is one of the eighteen mega-biodivers a nation around the world. The country is home to many endangered species of wild flora and fauna. The state of Maharashtra also is blessed with a great biodiversity and the forest of the state have been graced by beauty that can entice the senses of the visitors. With growing anthropogenic pressure, in recent years, wildlife has felt the pressure of dwindling habitats resulting into human animal conflict. We as a society have neared a time where we have to make choices that can be in the best interest of co-existence of all forms of wildlife.

Wildlife Research & Training Centre, Gorewada, Nagpur has been founded by a MoU between Maharashtra Animal & Fishery Sciences University, Nagpur & Forest Development Corporation of Maharashtra Ltd., Nagpur in 2014. The Centre was established to further Research & Training in the field of wildlife health care, management and conservative breeding and the centre has unique confluence of Department of Forest, Government of Maharashtra and MAFSU, Nagpur.

I must put on record the eminent contribution of the centre in the area of conflict animal health care, rehabilitation, management at Gorewada Rescue Centre. The team has done extremely well in hand raising orphans and rehabilitation of seized parakeets. In the time of COVID-19, the centre has organized many webinars for outreach education. I am extremely delighted to know that the centre has announced the organization of an Online International Wildlife Conference WILDCON-2020 on 18th& 19th December, 2020. It is a matter of pride that many presenters from all over the world would be actively participating and I am sure the Conference will facilitate the exchange of knowledge and skills among wildlife professionals.

I am extremely happy to note that a session on wildlife rescue, conflict and rehabilitation has been scheduled. Under the current scenario, a scientific unbiased discussion and brain storming is must to address the issue of human – wild conflict. I hope the Conference will address the needs of wildlife and come up with recommendations to benefit the wildlife.

I conclude with my best wishes and support to this Online International Wildlife Conference WILDCON-2020.

With best wishes.

(Shri. N.H. Kakodkar)

Forest Development Corporation of Maharashtra Ltd.

(A Govt. of Maharashtra Enterprise)
CIN : U45200MH1974SGC017206

FDCM Bhawan, 359/B, Hingna Road, Ambazari, NAGPUR - 440 036.
Website : www.fdcm.nic.in

N. Vasudevan, I.F.S.
Principal Chief Conservator of Forests &
Managing Director

Phone : 0712 - 2811964
E-mail : vasuiist@gmail.com

Dear All,

Warm Greetings.

Forest Development Corporation of Maharashtra Ltd., Nagpur is pleased to announce the organization of Online International Wildlife Conference WILDCON-2020. Wildlife Research & Training Centre, Gorewada, Nagpur is a collaborative institute of Maharashtra Animal & Fishery Sciences University, Nagpur and Forest Development Corporation of Maharashtra Ltd., Nagpur. The centre is based in the campus of Wildlife Rescue Centre, Gorewada, Nagpur and has been shouldering the responsibility to manage and care for the rescued wildlife. The union of FDCM Ltd., Nagpur and MAFSU, Nagpur has resulted into fruitful efforts for wildlife welfare and efficient management.

Training and research in wildlife are prime objectives of Wildlife Research & Training Centre, Gorewada, Nagpur. The centre has been instrumental in engaging veterinarians and allied professionals in various webinars related to wildlife health care and management. The centre has also been resourceful in extending their technical know-how in diagnosis and treatment of wildlife.

The conference embraces the theme 'insights into opportunities and threats in wildlife conservation' in order to highlight the collaborative responsibilities of diverse professionals engaged in wildlife conservation. The conference aims to provide a meaningful confluence of ideas, thoughts and theories that can be implemented at the field level to better wildlife management and conservation.

Forest Development Corporation Maharashtra considers it an honour to be associated with novel initiatives of Wildlife Research & Training Centre, Gorewada, Nagpur. I wish the entire team of WILDCON-2020 a great success.

With best wishes,

N. Vasudevan
Managing Director,
FDCM Ltd., Nagpur

संचालनालय (शिक्षण) तथा अधिष्ठाता (पशुवैद्यक व पशुविज्ञान विद्या शाखा) यांचे कार्यालय
DIRECTORATE (INSTRUCTIONS) & OFFICE OF THE DEAN, FACULTY OF VETERINARY & ANIMAL SCIENCES
महाराष्ट्र पशु व मत्स्य विज्ञान विद्यापीठ,
फुटाळा तलाव मार्ग, नागपूर -४४० ००१
MAHARASHTRA ANIMAL AND FISHERY SCIENCES UNIVERSITY,
Futala Lake Road, NAGPUR – 440 001.
Ph. (O): + 91712-2514669 Website: www.mafsu.in email : didvmafsu@gmail.com

डॉ. आ. पा. सोमकुवर, एम.व्ही.एस.सी., पी.एच.डी.
संचालक (शिक्षण) व अधिष्ठाता (पशुवैद्यक व पशुविज्ञान विद्या शाखा)
Dr. A. P. Somkuwar, M.V.Sc., Ph.D.
Director (Instructions) & Dean (Faculty of Veterinary & Animal Sciences)

No. MAFSU/DV/F.No.148/990 /2020
Date : 14 /12/2020

Message

I am extremely happy to understand that Wildlife Research & Training Centre, Gorewada, Nagpur under the patronage of Maharashtra Animal & Fishery Sciences University, Nagpur, Forest Development Corporation of Maharashtra Ltd., Nagpur; Forest Department, Government of Maharashtra and Association of Indian Zoo & Wildlife Veterinarians (AIZ & WV) are hoisting Online International Wildlife Conference WILDCON-2020 from 18th to 20th December, 2020. Wildlife Research & Training Centre has been established by a Memorandum of Understanding between Maharashtra Animal & Fishery Sciences University, Nagpur & Forest Development Corporation of Maharashtra Ltd., Nagpur on 3rd April, 2014. Currently, the centre has its campus in the Wildlife Rescue Centre, Gorewada, Nagpur and is one of its kind in the country. The centre has played a vital role in the management, treatment and rehabilitation of wildlife in the entire region. I also would like to put on records the exemplary work of the centre in hand rearing orphans received from the entire state of Maharashtra.

Research and training are an integral part of the mandate of WRTC, Gorewada, Nagpur. The centre has been a flag bearer in the propagation of knowledge and technical know-how in the field of Wildlife Health & Management. The centre has prudently utilized online platforms to further the cause of knowledge amongst the wildlife veterinarians, administrators, wildlife lovers etc. I am sure in the coming years the centre will be a leading seat of research & training in the country.

In this regard, Online International Conference WILDCON is a matter of pride and satisfaction to all associated with it. The platform has united expertise from all over the world under one umbrella to brainstorming the possibilities of positive intervention in wildlife conservation. The event will prove to be a seat of knowledge to all participants. I am hopeful that the event will help upgrade practices in wildlife in the country.

I wish the organizers of Online International Wildlife Conference WILDCON-2020 the very best for this innovative and novel project.

With Best wishes.

(A. P. Somkuwar)

Maharashtra Animal & Fishery Sciences University

Futala Lake Road, Nagpur - 440 001

Dr. N. V. Kurkure
Ph.D
Director of Research

Phone : (O): 0712 - 2511282, 2511283
Tele-Fax : 0712 - 2511282
Email : drmafsu@gmail.com
Website : www.mafsu.in

Ref: MAFSU/DR/TO/378/2020 **Dated:** 14.12.2020



Message

I am extremely pleased to learn that Wildlife Research & Training Centre, Nagpur under the auspices of Maharashtra Animal & Fishery Sciences University, Nagpur and its collaborating partners along with the Association of Indian Zoo and Wildlife Veterinarians (AIZ & WV) are organizing Online International Wildlife Conference WILDCON 2020 & 14th Annual Convention of Association of Indian Zoo and Wildlife Veterinarians (AIZ & WA) on 18th & 19th December 2020.

Considering the vast biodiversity of the region the government has accepted the University's proposal to establish Wildlife Research & Training Centre, Gorewada, Nagpur. The foundation of the centre was formalized by a Memorandum of Understanding (MoU) between MAFSU, Nagpur & FDCM Ltd., Nagpur on 3rd April 2014. Accordingly, MAFSU, Nagpur has taken up the role of mentorship in the management, health care, rehabilitation, research, and education for the entire state of Maharashtra.

Wildlife conservation is important on account of the aesthetic and cultural value that the wildlife adds to the region. Apart from this, it is also important from the point of view of public health, wild animals are reservoirs of many diseases of public health importance. It is thus essential to support research gaps and imply principles of *'One health'* to benefit society.

WILDCON 2020, International Online Conference 2020, is a great podium to discuss issues related to wildlife. I am happy to note a session on Conservation Biotechnology & Forensics. The dynamic progress that these fields have seen can prove a boon to the noble cause of wild conservation.

I wish the organizers of the Online International Wildlife Conference WILDCON-2020 the very best.

With Best Wishes.

Director of Research
Maharashtra Animal & Fishery
Sciences University
Seminary Hills, Nagpur-6.

Maharashtra Animal & Fishery Sciences University
Futala Lake Road, Nagpur- 440001 (M S)

Dr. V. D. Aher MVSc, PhD, LL B Director Extension Education		☎:(0712) 2980014 email : mafsudet@yahoo.co.in Website - www.mafsu.in

MESSAGE

I am extremely pleased to learn that Wildlife Research & Training Centre, Nagpur under the auspices of Maharashtra Animal & Fishery Sciences University, Nagpur and its collaborating partners along with Association of Indian Zoo and Wildlife Veterinarians (AIZ & WV) are organizing Online International Wildlife Conference WILDCON 2020 & 14th Annual Convention of Association of Indian Zoo and Wildlife Veterinarians (AIZ & WA) during 18th to 19th December, 2020.

Maharashtra is known for its forest and wildlife wealth throughout the country. The tiger reserves and national parks of Maharashtra illustrate beauty and elegance. Recent tiger census of 2018 indicated that there are over 300 tigers in Maharashtra which is a very encouraging sign for the entire state. Wildlife Research & Training Centre has been established by a Memorandum of Understanding between Maharashtra Animal & Fishery Sciences University, Nagpur & Forest Development Corporation of Maharashtra Ltd., Nagpur on 3rd April, 2014. Currently, the centre has its campus in the Wildlife Rescue Centre, Gorewada, Nagpur and is one of its kind in the country and has played a vital role in the management, treatment and rehabilitation of wildlife in the entire region.

WRTC, Nagpur is a confluence between MAFSU, Nagpur and FDCM Ltd., Nagpur. The symbiosis of two pioneering institutions has led to a win-win association for wildlife conservation. Education is an important element of association mentioned in the MoU. The centre is working dedicatedly to create resourceful manpower by training vets and field staff of forest in areas of health care and management.

In this regard, Online International Conference WILDCON is giant leap in integrating efforts of professionals engaged in the field of wild conservation. There is a need for coordinated professional intervention for the conservation efforts to be fruitful. WILDCON 2020 is a definite platform to unify professionals and enrich technical knowhow utilizing precious inputs arising from discussions and experience sharing.

I wish the organizers of Online International Wildlife Conference WILDCON-2020 the very best for this innovative and novel project.

Director
Extension Education
MAFSU, Nagpur

महाराष्ट्र पशु व मत्स्य विज्ञान विद्यापीठ
फुटाळा तलाव मार्ग, नागपूर - 440001
MAHARASHTRA ANIMAL AND FISHERY SCIENCES UNIVERSITY
Futala Lake Road, Nagpur – 440001, Maharashtra (India)
Ph.: 0712 2511784/85, Fax: 0712 2511273 Email:registrarmafsu@yahoo.com, Web: www.mafsu.in

D. B. Raut
Registrar

MESSAGE

I am extremely pleased to learn that Wildlife Research & Training Centre, Nagpur under the auspices of Maharashtra Animal & Fishery Sciences University, Nagpur and its collaborating partners along with Association of Indian Zoo and Wildlife Veterinarians (AIZ & WV) are organizing Online International Wildlife Conference WILDCON 2020 & 14th Annual Convention of Association of Indian Zoo and Wildlife Veterinarians (AIZ & WA) on 18th& 20th December, 2020.

Wildlife Research & Training Centre has been a seat of learning for professionals of different background. International Conference WILDCON 2020 will be another feather in the cap of this unique centre. The centre has largely contributed to the management of conflict animals and wildlife in distress in the region.

I congratulate the organizers for thoughtfully having a separate session on conservation biotechnology and forensics. In the current era where biotechnology has revolutionized agriculture and health care, wildlife has a lot to expect from the growing field. The list of speakers has authorities in the subject from all over the world.

I hope it will be a great learning opportunity for professionals engaged in wildlife conservation. I congratulate Wildlife Research & Training Centre, Gorewada, Nagpur for this novel initiative in the times of ongoing pandemic COVID-19. I wish you the best for WILDCON 2020.

With Regards,

REGISTRAR
Maharashtra Animal & Fishery Sciences
University, Nagpur

ASSOCIATION OF INDIAN ZOO AND WILDLIFE VETERINARIANS

Registered under Societies Act 1860, Regd No. : 1097 / 1999-2000

Prof (Dr) B.M. Arora
Chairman, AIZWV

MESSAGE

Sustainable development and conservation of the wildlife are the only way forward for the co-existence of man and other forms of life. Wild conservation has many arenas of which rescue, rehabilitation and management are of vital importance. Firm, precise and swift diagnosis is the need of the hour in wildlife health care. Emerging and re-emerging diseases time and again test our preparedness to counter catastrophe and to conserve wildlife. Conservation is versatile and involves a wide array of professionals from biologists to veterinarians and from engineers to administrators. Efforts to conserve the fast fading wildlife diversity have been undertaken at all levels of society, however need of professional collaboration and expertise sharing is essential.

International Conference WILDCON 2020 and 14th Annual Convention of Association of Indian Zoo and Wildlife Veterinarians is being organized through **online mode on the important theme "Insights into wildlife conflicts, rescue and rehabilitation: Challenges and Opportunities for Conservation" during 18-19th December, 2020.** The conference intends to showcase the current challenges and opportunities in wildlife health care and management. The world is united for the conservation of environment and wildlife; however, an extrinsic and intrinsic pressure for conservation of diversity has been increasing rapidly.

I appreciate the efforts made by the organizing team and the MAFS University authorities in order to bring expertise in the arena of wildlife veterinary science under one roof and facilitate a consequential dialogue to streamline conservation efforts at each echelon of its organization. The theme of the conference is devised to allow professionals working in different parts of the world to share their work and experience with fellow mates. I believe that this theme embraces the idea of learning through participation and experience sharing among participants from different countries.

I on behalf of AIZWV welcome the participants and hope this conference will be a stepping stone for the young and mid-career professionals associated in wildlife and allied fields.

B.M. Arora

Regd Office: Association of Indian Zoo and Wildlife Veterinarians (AIZWV), M83 BDA Tibrinath, Bareilly (UP) 243122, India; www.aizwv.org Phone:+91-8077356631; Email: drbmarora@gmail.com

Message

It is heartening to know that the Wildlife Research and Training Centre, Gorewada, in collaboration with Maharashtra Animal and Fishery Sciences University, Nagpur, Forest Development Corporation of Maharashtra Ltd., Nagpur and Association of Indian Zoo and Wildlife Veterinarians (AIZ&WV) are organising the online International Wildlife Conference WILDCON 2020 & 14th Annual Convention of AIZ&WV at Nagpur on 18th to 20th December, 2020.

The organising committee has rightly chooses the theme of the conference "Insights in to Wildlife Conflicts, Rescue & Rehabilitation: Challenges & opportunities for conservation" to be discussed in length in the conference. Leaving aside the Health management and Disease diagnosis of wild animals in one side, the other major facet of wildlife conservation is the Conflict, Rescue and Rehabilitation. Due to explosion of human population together with rapid urbanization, there is increase pressure on wildlife habitats-resulting in conflicts between man and animals. The major man –animal conflict seen in different parts of the country varies with elephant, leopard, nilgai, monkey etc. but how to address/mitigate this –is a big question. Then come rescue and rehabilitation. Many of the rescue animals are unfit to release and the rescued animals which were found fit to release to the wilderness, many a times their fate is unknown. Therefore, the deliberation in the proposed conference with the learned scientists from our country as well as from the foreign countries will be helpful in understanding the related problems and eventually pave the way for meaningful policy decision and future strategies to be undertaken for better wildlife conservation and management.

I would like to congratulate and compliment the organizers for their painstaking efforts in its organization. I wish the conference a grand success.

Dr Apurba Chakraborty
President, AIZ&WV
Retd. Director of Research
Assam Agricultural University
Khanapara, Guwahati781022
Assam

Maharashtra Animal & Fishery Sciences University, Nagpur
Wildlife Research & Training Centre,
Gorewada, Nagpur
Opp. Hindustan Lever Godown Square, Mahurzhari Road, Fetri, Nagpur 441501

Dr. S.V. Upadhye
MVSc., Ph.D., FISVS
Director

e-mail: shirishupadhye@gmail.com
directorwrtc@gmail.com

From the Desk of Organizing Secretary

I am extremely happy to announce the organization of Online International Conference WILDCON-2020 from 18th to 20th December, 2020 by Wildlife Research & Training Centre (WRTC), Gorewada, Nagpur under the auspices of Maharashtra Animal & Fishery Sciences University Nagpur; Forest Development Corporation of Maharashtra Ltd, Nagpur; Department of Forest, Government of Maharashtra and Association of Indian Zoo & Wildlife Veterinarians (AIZ & WV).

WRTC, Gorewada, Nagpur is a joint venture institute that came into existence in the year 2015 through a MoU between MAFSU, Nagpur & FDCM Ltd., Nagpur, with a vision to strengthen veterinary care to wildlife, undertake basic research and extend training to veterinarians, field staff and officers of Forest Department engaged in wildlife conservation. Since inception the centre is also extending services to wildlife rescue, treatment and rehabilitation at Wildlife Rescue Centre, Gorewada, Nagpur.

In current era when the country has seen more than a couple of incidences of major outbreaks emerging from wildlife reservoirs, time has come to identify thrust areas in health and disease monitoring to contain spill overs. Implementing and propagating the principle of **'One Health'** is the only way forward to ensure public health. The centre has a vision wildlife health and contribute to research in the field of conservation, medicine, forensics and conservation breeding.

Education and extension are important mandates of the Centre. At WRTC we understand the importance of community participation in conservation. The centre aims to create awareness among the masses by one-on-one interaction, school visits and informative documentaries. The centre also has prioritized strengthening of man power engaged in forest department to ensure prompt response and care to wild animals in distress. Conservation can receive impetus only if professionals from diverse backgrounds can contribute for a common goal and thus considering the above scenario, WRTC has decided to Organize Online International Conference WILDCON 2020 for stake holders viz veterinarians, forest officials and staff, conservationists, biologists and common masses. Online conference will provide a stage for efficient exchange of thought and will be a podium for inter professional engagement for the betterment of conservation efforts. We have united experts from all corners of the world to share their expertise and experiences in wildlife conservation. We hope this engagement will better the state of practices of wildlife in the country and be a great learning to one and all associated with it.

I whole heartedly welcome you all for the Conference.

(S.V. Upadhye)

ORGANIZING COMMITTEE

Chief Patron

COL.(Dr) Prof. A.M. Paturkar
Hon'ble Vice-Chancellor,
MAFSU, Nagpur

Patron

Dr. N. Rambabu
Hon'ble PCCF (HoFF),
Maharashtra

Patron

Shri. N.H. Kakodkar
Hon'ble PCCF (Wildlife),
Maharashtra

Patron

Shri. N. Vasudevan
Hon'ble Managing Director,
FDCM Ltd., Nagpur

Patron

Dr. A. P. Somkuwar
DI & Dean (Vet.), MAFSU,
Nagpur

Chairman

Prof. (Dr) B.M. Arora
AIZ & WV, Bareilly,
Uttar Pradesh

Organizing Secretary

Dr. S.V. Upadhye
Director, WRTC, Gorewada,
Nagpur

CO - ORGANIZING SECRETARIES

Dr. V. M. Dhoot
Dy. Director, WRTC,
Nagpur

Dr. G. R. Bhojne
Assistant Professor,
VCM, NVC, Nagpur

JOINT ORGANIZING SECRETARIES

Dr. G. S. Khandekar
Professor,
VSR, MVC, Mumbai

Dr. Shalaka Chauhan
Assistant Professor,
VSR, KNPVC, Shirwal

TREASURER

Dr. S. M. Kolangath
SMS (Animal Biotechnology)
WRTC, Gorewada, Nagpur

EXECUTIVE MEMBERS

Shri. P. B. Panchbai
DM, Gorewada Project,
Nagpur

Dr. A. P. Gawande
Dy. Director, WRTC,
Gorewada, Nagpur

Dr. Mayur Pawshe
SMS (ARGO), WRTC,
Gorewada, Nagpur

Dr. Shalini A. S.
SMS (ARGO), WRTC,
Gorewada, Nagpur

Dr. Sunil Bawaskar
Office-in-charge,
Maharaj Bagh Zoo, Nagpur

Shri. Kundan Hate
Member, Wildlife Advisory Board,
Maharashtra

Dr. Subodh Nandagawli
Veterinary Officer,
Forest Department, Nagpur

Dr. Ravi Khobragade
Veterinary Officer, TATR,
Chandrapur

Shri. Vinit Arora
Secretary,
Shrusti Paryavaran Mandal,
Nagpur

Shri. Avinash Londhe
Member, Birds of Vidarbha,
Nagpur

Organizing Committee- WILDCON 2020

Committees of WILDCON 2020 Online International Conference

1. Technical Committee/ Scientific session committee

1	Dr. D. S. Raghuwanshi	Chairman
2	Dr. Sujit Kolangath	Member
3	Dr. Shalaka A. Chauhan	Member
4	Dr. Gauri Khante	Member
5	Dr. Mayur Kate	Member
6	Dr. Syed Bilal Ali Syed Hayat Ali	Member
7	Dr. A. S. Shalini	Member
8	Dr. Mayur Pawshe	Secretary

2. Co- ordination Committee

1	Dr. G. S. Khandekar	Chairman
2	Dr. S. B. Akhare	Member
3	Dr. Ravi Khobragade	Member
4	Dr. Subodh Nandagawali	Member
5	Dr. Chetan Patond	Secretary
6	Dr. P. A. Tembhurne	Member
7	Dr. R.S. Ghadge	Member

3. Committee for Acceptance of Lead papers & abstracts

1	Dr. G. R. Bhojne	Chairman
2	Dr. M. S. Patil	Member
3	Dr. Sujit Kolangath	Secretary
4	Dr. Mayur Pawshe	Member
5	Dr. A. S. Shalini	Member
6	Dr. Kalyani Thakur	Member
7	Dr. Tista Joseph	Member
8	Dr. Ushma Patel	Member
9	Dr. Amit Kshirsagar	Member

4. Souvenir Committee

1	Dr. V. M. Dhoot	Chairman
2	Dr. Sujit Kolangath	Member
3	Dr. A. S. Shalini	Secretary
4	Dr. Mayur Pawshe	Member
5	Dr. Gauri Khante	Member

5. Committee for Online Platform

1	Dr. G.R.Bhojne	Chairman
2	Dr. Arvind Chavhan	Member
3	Shri Kundan Hate	Secretary
4	Shri Nikhilesh Sawarkar	Member

6. Stage Decoration Committee

1	Dr. Shalaka Chavhan	Chairman
2	Dr. Bhagyashree Badane	Member
3	Dr. Gauri Khante	Member
4	Dr. Meenakshi Bawaskar	Member
5	Dr. Prachi Taksande	Member
6	Dr. A.S. Shalini	Secretary
7	Dr. Kalyani Thakur	Member
8	Shri Siddhant More	Member

7. Food/ Refreshment Committee

1	Shri Kundan Hate	Chairman
2	Shri Avinash Londhe	Secretary
3	Shri Samir Neware	Member
4	Shri Siddhant More	Member
5	Shri Saurabh Sukhdeve	Member

8. Purchase Committee

1	Dr. Ajay Gawande	Chairman
2	Dr.V.M.Dhoot	Member
3	Dr. Abhijit Motghare	Member
4	Dr. C.G. Panchabhai	Member
5	Shri Vinit Arora	Member
6	Dr. Mayur Pawshe	Secretary
7	Dr. Sujit Kolangath	Member
8	Dr. A. S. Shalini	Member

9. Publicity Committee

1	Shri Kundan Hate	Chairman
2	Dr. Mayur Pawshe	Member
3	Dr. Sujit Kolangath	Secretary
4	Dr. A. S. Shalini	Member
5	Shri Avinash Londhe	Member
6	Shri Vinit Arora	Member

Executive Committee of Association of Indian Zoo and Wildlife Veterinarians (AIZ &WV)

Chairman	Dr. B. M. Arora
President	Dr. Apurba Chakrabarti
Vice-President	Dr.Munmun Sarma
General Secretary	Dr. M. Haque
Joint Secretary cum Treasurer	Dr. P.J. Deka

DISCLAIMER

Ideas and claims made in the abstract are the sole responsibility of the author. The organizers do not take any responsibility of the authenticity and medical validity of the claims made herein. The organizers believe that all necessary sanctions and permissions from concerned authorities have been duly sought.

Programme Schedule

Online International Conference WILDCON 2020

18th to 20th December, 2020

Sr. No	Particulars / Title	Time	Speaker
Date: 18/12/2020 Friday			
1	Inaugural Programme	09:30 am to 11:30 am	
SESSION - I : THEME			
2	Rescue of Stray & Injured Large Mammals: Elephant, Rhinoceros, Bison etc.	11:30 am to 12:00 pm	Dr. K.K. Sarma Professor, COVS, Guwahati, Assam
3	Capacity Building For Wildlife Health Management	12:00 pm to 12:30 pm	Dr. Pradeep Malik Retd. Professor, WII, Dehradun
SESSION-II : CONFLICT, RESCUE & REHABILITATION			
4	Rhino population threats and orphans rescue and rehabilitation. Information and experience based on white rhinos ***(Ceratotherium simum)*** *and black rhinos* ***(Diceros bicornis).***	12:45 pm to 01:15pm	Dr. Fabiola Quesada CEO, Wild-Spirit, Pretoria, South Africa
5	Contraception Programmes for the Control of Wild Pigs and Macaques in Hong Kong, Techniques, Rationale and Results	01:15 pm to 01:45 pm	Dr. Paolo Martelli Director Veterinary Services, Ocean Park, Hong Kong
6	Integrating Wild Animal Capture Techniques in Wildlife Management and Research	1:45 pm to 2: 15 pm	Dr. Parag Nigam Associate Professor, WII, Dehradun
7	Abstract Presentations	2: 15 pm to 4: 30 pm	
SESSION-III : WILDLIFE HEALTH & MANAGEMENT			
8	Minimally Invasive Surgery in Wildlife	4:30 pm to 5:00 pm	Dr Romain Pizzi
9	Abstract Presentations	5:00 pm to 7:00 pm	
10	Immobilization and Anaesthesia of Lions, Tigers, and Leopards	7: 00 pm to 7:30 pm	Dr. Edward Ramsay Professor, University of Tennessee, USA

Date: 19/12/2020 Saturday			
SESSION-IV : ZOO BIOLOGY & CONSERVATION			
1	Teaching Humane Care: Improving Asian Elephant Welfare	09:00 am to 09:30 am	Steve Koyle Phoenix Zoo
2	From the Killers Snares to Radio-Collared: The Management of Snare Injuries in Tigers (*Panthera tigris*) and studying their dispersal in Tippeshwar Wildlife Sanctuary,	09:30 am to 10:00 am	Dr. Ravikiran Govekar,Field Director, Pench Tiger Res,Nagpur
	Maharashtra, India		Reserve
3	Brittle and Fragile Leopard (*Panthera pardus*) Skin Trophy Restored	10:00 am to 10:30 am	Leena Zilpe Haate Heritage Conservation, Nagpur
4	Is Gurney's pitta Hydrornis gurneyi on the brink of extinction?	11:00 am to 11:30 am	Dr Nay Myo Shwe Conservation Programme Manager, F&F Intl, Myanmar
5	Bat Biology & Conservation	11:30 am to 12:00 pm	Dr. Moe Moe Aung University of Mandalay, Myanmar
6	Abstract Presentations	12: 00 pm to 02: 30 pm	
7	Animal Welfare and Ethical Concerns in Wildlife Veterinary Practice in India	2:30 pm to 3:00 pm	Dr. Arun A Sha WildlifeSOS, Bangalore
8	Challenges of Asian Elephant Conservation in Myanmar	3:00 pm to 3:30 pm	Dr.Khyne U Mar United Kingdom
SESSION-V : CONSERVATION BIOTECHNOLOGY & FORENSICS			
9	Role of DNA Forensics in fight against wildlife crime and illegal trade in India	03:30 pm to 04:00 pm	Dr. Ajay Gaur CCMB, Hyderabad
10	Opportunities and Limitations for Reproductive Science in Species Conservation	04:00 pm to 04:30 pm	Prof. Bill Holt Smithsonian Institute, Washington DC, USA
11	Abstract Presentations (1 to 20)	04:30 pm to 07:30 pm	
12	Assisted Reproduction in Wild Animal Species	07:30 pm to 08:00 pm	Dr. Pierre Comizzoli Smithsonian Institute, Washington DC, USA
Poster Session Online Presentation			
Date: 20/12/2020 Sunday			
	Plenary session	11:00 am	

SESSION- I: THEME PAPER

Sr. No.	INVITED PAPERS	Page No(s)
1	RESCUE OF STRAY AND INJURED LARGE MAMMALS: ELEPHANT, RHINO, BISON ETC. Prof. Kushal Konwar Sarma	1
2	CAPACITY BUILDING FOR WILDLIFE HEALTH MANAGEMENT Dr. Pradeep Malik	
3	INDIA'S ENDANGERED MAMMALIA Dr. B. M. Arora and Bipul Chakrabarty	6

SESSION-II: CONFLICTS, RESCUE AND REHABILITATION

Code	Title and Author(s)	Page No(s)
	LEAD/ INVITED PAPERS	
CRR-LP 1	RHINO POPULATION THREATS ANS ORPHANS RESCUE AND REHABILITATION INFORMATIONAND EXPERIENCE BASED ON WHITE RHINOS (*Ceratotherium simum*) AND BLACK RHINO (*Diceros bicornis*). Fabiola Quesada	15
CRR-LP 2	CONTRACEPTION PROGRAMMES FOR THE CONTROL OF WILD PIGS AND MACAQUES IN HONG KING, TECHNIQUES, RATIONALE AND RESULTS. Paolo Martelli	16
CRR-LP 3	INTEGRATING WILD ANIMAL CAPTURE TECHNIQUES IN MANAGEMENT AND RESEARCH Parag Nigam and Pradeep K. Malik	17
	ABSTRACTS	
CRR-1	AN OVERVIEW OF RESCUE AND REHABILITATION FOR FREE-RANGING ANIMALS PERFORMED BY THE WILD ANIMAL MEDICAL CENTER OF RAKUNO GAKUEN UNIVERSITY SINCE 2004- ITS EDUCATIONAL ACTIVITIES FOR VET STUDENTS Mitsuhiko Asakawa	21
CRR-2	REHABILITATION OF CONFISCATED INDIAN STAR TORTOISE (*Geochelone elegans*) SATHIYAMANGALAM TIGER RESERVES (STR), TAMILNADU A. Manimozhi, K. Sridhar, & Boon Alwin & M. Sekar.	22
CRR-3	IMPORTANCE OF ANAMNESIS TO DISCOVER WILDLIFE CRIME AND THERAPEUTIC MANAGEMENT WITH REHABILITATION OF EMERGENCY CASES OF WILD ALEXANDRINE PARAKEET DUE TO HUMAN CONFLICT Katkhede P.D., Waghmare S.P., Bhikane A.U., Pajai K.S.	23
CRR-4	INCREASING INCIDENCE OF HIMALAYAN BROWN BEAR ATTACK ON LIVESTOCK IN KARGIL Shamim Ali and Mansoor Ali	24
CRR-5	UNDERSTANDING & ADDRESSING THE DRIVERS OF HUMAN WILDLIFE CONFLICT AND RECENT MITIGATION EFFORTS IN UTTARAKHAND Aditi Sharma	25
CRR-6	PHYSICAL ESTIMATION OF CROP LOSS DUE TO BLACK BUCK RAID IN AGRICULTURE FIELD Surjeet Singh and J. M. Chahande	26
CRR-7	RESCUE EFFORT OF A SUB-ADULT FEMALE WOLF IN UMRER TERRITTORIAL FOREST Vinit Arora	27
CRR-8	RESCUE OF STINGLESS BEE COLONIES DURING DEFORESTATION: AN INNOVATIVE METHOD FOR CONSERVATION Jagruti Roy and Ashish Kumar Jha	28

CRR-9	MODELLING OCCUPANCY OF TIGERS (*Panthera tigris*) IN A NON-PROTECTED AREA OF NAGPUR, MAHARASHTRA Dhanusha Kawalkar , Rahul Mungikar and Kundan Hate	29
CRR-10	RETROSPECTIVE STUDY OF RESCUE, TREATMENT AND REHABILITATION OF WILD ANIMAL BY TRANSIT TREATMENT CENTRE, NAGPUR Syed Bilal Ali, Mayur R. Kate, S.V. Upadhye, V.M. Dhoot, G.R. Bhojne, G. Mallikarjuna, Prabhu Nath Shukla and K. Hate	29
CRR-11	SUCCESSFUL RESCUE OF LEOPARD FROM WELL Syed Bilal Ali, Mayur R. Kate, Prabhu Nath Shukla, and K. Hate	29
CRR-12	RESCUE OF INDIAN GAUR FROM HUMAN DOMINATED LANDSCAPE Syed Bilal Ali, A.G. Dubey, S. Nandagawali and Tista Joseph	30
CRR-13	SUCCESSFUL RESCUE AND RELEASE OF MALE LEOPARD USING MONKEY TRAP CAGE Syed Bilal Ali	31
CRR-14	ESTABLISHMENT OF TRANSIT TREATMENT CENTRE, NAGPUR FOREST DIVISION, NAGPUR- A BOON FOR WILDLIFE Kundan M. Hate	31
CRR-15	OUR JOURNEY FROM A KALANDAR MADARI TO PARA-VETERINARIAN IN A DANCING SLOTH BEAR REHABILITATION CENTRE Imam Sab and Saddam Husen	32
CRR-16	HUMAN-ELEPHANT CONFLICTS IN BANKURA DISTRICT, WEST BENGAL Subhasis Mahato and Tulika Panda	32
CRR-17	PROSTHETIC REHABILITATION OF A SOFT-SHELL TURTLE Shobha Jawre, Madhvee Dhairykar, Manoj Reddy and Nidhi Rajput	33
CRR-18	ELEPHANT TRAPPED IN A 50-FOOT WELL RESCUED AFTER 18-HOUR OPERATION IN TAMIL NADU A Prakash	34
CRR-19	RESOLVING HUMAN-BIRD CONFLICT: A CASE STUDY OF THE EDIBLE-NEST SWIFTLETS IN THE ANDAMAN AND NICOBAR ISLANDS, INDIA Shirish S Manchi	35
CRR-20	DANGERS TO WILD LIFE FROM PET AND FERAL ANIMALS Sarabjeet Singh, Anil Kumar Pandey and Utsav Sharma	36
CRR-21	CROSS-PLATFORM APPLICATION FOR RESCUE OPERATIONS Omkar Kekre, Nihal Reddy, Rohit Hazare and Srushti Mehatkar	36
CRR-22	MANAGEMENT OF PARAPARESIS IN AN INDIAN JACKAL (*Canis aureus indicus*): MEDICALMANAGEMENT, PHYSIOTHERAPY & APPLICATION OF BRACES. Upadhye, S.V., Tista Joseph, Kolangath, S.M., V.M. Dhoot, Pawshe M.D, Shalini A.S. and Khante G.S.	37
CRR-23	SUCCESSFUL RELEASE OF SEIZED INDIAN PANGOLIN (*Manis crassicaudata*) TO ITS NATURAL HABITAT S.K. Joshi, R.K.Verma, J.Singh, R.L.Rakesh, Preety Singh, A, Sonwani and B. Shrimali	38
CRR-24	IMUNOCONTRACEPTION AS A MANAGEMENT TOOL IN DEALING WITH HUMAN WILDLIFE CONFLICT IN INDIA Sanath Krishna Muliya, Lallianpuii Kawlni, Kafil Hussain, Priya Gusain, Vishnupriya Kolipakam, Qamar Qureshi and Yadvendradev Jhala	39
CRR-25	MODELING FOR THE ESTABLISHMENT OF A NETWORK OF PROTECTED AREAS IN THE DIFFERENT LAND USE MANAGEMENT SITE OF GONDIA DISTRICT IN MAHARASHTRA (INDIA) Sushilani Chakma, Jagruti Roy and Ashish Kumar Jha	40
CRR-26	RESCUE OF A SPECTACLED COBRA (*Naja naja*) ENTANGLED IN A METALLIC PIPE Devendra Podhade, Ranjeet Harne, Amol Rokde, Nidhi Rajput, Somesh Singh and Shobha Jawre	40
CRR-27	CONFLICTS BETWEEN WILDLIFE CONSERVATION AND THE MAJOR LAND USE PRACTICES IN UMRED TEHSIL IN NAGPUR DISTRICT OF MAHARASHTRA (INDIA) Aniket Dahake, Jagruti Roy and Ashish Kumar Jha	41

SESSION-III
WILDLIFE HEALTH & MANAGEMENT

Code	Title and Author(s)	Page No(s)
	LEAD/ INVITED PAPERS	
WHM-LP 1	MINIMALLY INVASIVE SURGERY IN WILDLIFE Romain Pizzi	43
WHM-LP 2	IMMOBILIZATION AND ANESTHESIA OF LIONS, TIGERS, AND LEOPARDS Edward C. Ramsay	47
	ABSTRACTS	
WHM-1	OPHTHALMIC EXAMINATION FOR REDUCED VISION IN A LEOPARD (*Panthera pardus*) Ankur Sharma, S. Sood, H.R. Bhardwaj, A. Kumar, M. Singh and D.K. Dwivedi	55
WHM-2	HEALTH MONITORING AND FIELD ANESTHESIA OF GOLDEN JACKALS (*Canis aureus*) Atul Gupta, Amol Rokde, Kajal Jadav and Madhvi Dherykar	55
WHM-3	CLINICO-HAEMATOLOGICAL STUDY IN AILING PIGEONS OF NAGPUR CITY Panchbhai C.G., Dhoot V.M., Bhojne G.R., Kalyani Thakur, Kriti Dohre and Sameeksha C.	56
WHM-4	ALVEOLAR BONE ABSCESS DUE TO THE BROKEN CANINE TOOTH IN A ROYAL BENGAL TIGER Tripathi S. D., Gaikwad R.V. and Khandekar G. S.	57
WHM-5	HAEMATOLOGICAL AND BIOCHEMICAL ANALYSIS OF BLOOD AND SERUM SAMPLES OF LIONS OF ALIPORE ZOOLOGICAL GARDEN, KOLKATA, WEST BENGAL Sumit Chowdhury, Uday Sankar Das and Maloy Maity	57
WHM-6	A CASE OF PENILE FRACTURE AND PARTIAL AMPUTATION OF OS PENIS IN A SLOTH BEAR (*Melursus ursinus*) Arun A Sha and Adhithyan N.K	58
WHM-7	THERAPEUTIC MANAGEMENT OF BULLAE IN CAPTIVE ASIAN ELEPHANTS (*Elephas maximas*)- A CASE REPORT Rahul Prasad, Ilayaraja Selvaraj, Arun A. Sha, Pramod Rajput and Srinu S. Maharana	59
WHM-8	THERAPEUTIC MANAGEMENT OF VENTRAL EDEMA IN ASIAN ELEPHANT (*Elephas maximas*)- A CASE REPORT Rahul Prasad, Illayaraja Selvaraj, Arun A Sha and Shivani Sing	59
WHM-9	MANAGEMENT OF INJURED SNAKES: INDIAN COBRAS, RAT SNAKE & ROCK PYTHON CLINICAL CASES Sanjay J. Gaikwad	60
WHM-10	DETECTION OF SPIROMETROSIS IN CAPTIVE ASIATIC LIONS AND ITS SUCCESSFUL TREATMENT AT NANDANKANAN ZOOLOGICAL PARK Santosh Kumar Gupta, Sarat Kumar Sahu, Debabrat Mohapatra, Alok Kumar Das, Niranjan Sahoo, Bijayendranath Mohanty and Shivani Soni	61
WHM-11	SURGICAL MANAGEMENT OF FISHING HOOK INGESTION IN INDIAN FLAP SHELL TURTLE M. R. Kate, Syed Bilal Ali and S. B. Akhare	61
WHM-12	ACUTE RESPIRATORY DISTRESS SYNDROME (ARDS) IN CAPTIVE TIGER WITH TREATMENT AND MANAGEMENT Sujay Suresh, Nikita Salian, Suresh Patel, Ravi Raidurg and Tista Joseph	62
WHM-13	MAIDEN PREVALENCE REPORT OF GASTROINTESTINAL PARASITES WITH THE ASSESSMENT OF ANTHELMINTIC ACTIVITY OF ALBENDAZOLE BY FAECAL EGG REDUCTION TESTS IN WILD ANIMALS OF HARYANA Hardeep Kalkal, Ashish Chauhan, Sagar Kadyan and Sukhdeep Vohra	63
WHM-14	DIAGNOSTIC IMAGING IN ZOO AND WILDLIFE MEDICINE M. Hoque, A.C. Saxena, Rajesh Kumar and Akash	64
WHM-15	CASE REPORT OF ANAEMIC ORPHANED TIGER CUB Khobragade, S. S., G.R. Bhojne, A. B. Motghare, S.S. Bawaskar and M.S. Bawaskar	65
WHM-16	A CASE OF SUCCESSFUL MANAGEMENT OF CLOACAL PROLAPSE IN TURTLE L. R. Pawaskar, S. B. Harkal, N. P. Bhave, S. G. Deshmukh, M. V. Ingawale, C. H. Pawashe.	65

WHM-17	SPIROCERCOSIS IN A RESCUED MONITOR LIZARD AND ITS ENDOSCOPIC DIAGNOSIS AND MANAGEMENT M.Veeraselvam, P.Selvaraj, S.Yogeshpriya, M.Saravanan, M.Venkatesan, K.Jayalakshmi, P.K.Ramkumar and N.Premalatha	66
WHM-18	SURGICAL MANAGEMENT OF PATAGIUM LACERATION IN BLUE ROCK PIGEONS (*Columba livia*) Madhvee Dhairykar, Shobha Jawre, Nidhi Rajput, Sriram Guntoju and Arvind Kumar	67
WHM-19	INTRAMEDULLARY PINNING FOR HUMERUS FRACTURE IN A HOUSE CROW (*Corvus splendens*) Mayank Barde, Ushma Patel, Chetan Patond and Rohit Gangwal	67
WHM-20	A CASE REPORT ON DIARRHOEA IN EMU Motghare, A. B., S.S. Bawaskar, R.S. Khobragade and M.S. Bawaskar	68
WHM-21	A CASE REPORT ON DIARRHOEA IN OTTERS AT MAHARAJBAG ZOO, NAGPUR Khobragade R.S., S.S. Bawaskar, A. B. Motghare and M.S.Bawaskar	68
WHM-22	CHEMICAL IMMOBILIZATION OF BLUE BULL (*Boselaphus tragocamelus*) Motghare, A. B., S.S. Bawaskar, R.S. Khobragade and M.S. Bawaskar	69
WHM-23	MANAGEMENT OF LACERATED WOUND IN RAT SNAKE USING ISOFLURANE ANAESTHESIA Pawar K.S., Thorat M.G., Raulkar R.V., Chepte S.D., Tayade K.N., Mitra A.A. and Jadhav A.A.	70
WHM-24	TRAUMATIC INJURY WITH DOG BITE IN A BLACK BUCK Rajendra Kumar T. and DT Naik	70
WHM-25	SURGICAL MANAGEMENT OF GASTROINTESTINAL FOREIGN BODIES IN AN INDIAN POND TERRAPIN (*Melanochelys trijuga*) Roopa Satish, Priyanka Nambiar, Vasudha AN, Sameeksha Reddy and Shashanka S	71
WHM-26	MANAGEMENT OF MANDIBULAR AND RADIO-ULNA FRACTURE IN FEMALE HYENA Sanjay J. Gaikwad	72
WHM-27	MANAGEMENT OF MAGGOTIZED WOUND IN THE ORAL CAVITY OF INDIAN COBRA (*Naja naja*) Sriram Guntoju, Shobha Jawre, Amol Rokhde, Nidhi Rajput, Devendra Podhade, Somesh Singh and Madhvee Dhairykar	72
WHM-28	SURGICAL MANAGEMENT OF WOUND IN A FEMALE MACAQUE MONKEY A CLINICAL CASE Sanjay J. Gaikwad	73
WHM-29	FRACTURE MANAGEMENT AND REPAIR WITH FIBERGLASS CAST IN DEER SPECIES Sujay Suresh, Ravi Raidurg, Nikita Salian, Chandrashekar, Naveen and Sameena Iza	73
WHM-30	SAFE ANESTHESIA PROTOCOL FOLLOWED IN VARIOUS DEER SPECIES AT TIGER AND LION SAFARI, SHIMOGA Sujay Suresh, Nikita Salian, Sameena Iza, Mukund Chandra and Guru C.	74
WHM-31	SUCCESSFUL LACERATED WOUND MANAGEMENT IN NILGAI (*Boselaphus tragocamelus*): A CASE REPORT V.V. Choutmal, G. S. Dalve, P.P. Deshmukh and A. S. Kachare	75
WHM-32	MANAGEMENT OF STOMATITIS AND ULCERATIVE GLOSSITIS IN ENDANGERED LEOPARD (*Panthera pardus)* Kolangath S.M., Dhoot V.M., Upadhye S.V., Pawshe M.D. and Shalini A.S.	76
WHM-33	MICROSCOPIC STUDIES ON BLACK BUCK (*Antilope cervicapra*) HAIRS Kolangath S.M., Upadhye S.V., Dhoot V.M., Pawshe M.D., Gawande A.P. and Shalini A.S.	76
WHM-34	MANANGEMENT OF HEPATOZOON SP. INFECTION IN AN INDIAN JACKAL (*Canis aureus indicus*) Kolangath S.M., Upadhye S.V., Dhoot V.M., Pawshe M.D. and Shalini A.S.	77
WHM-35	DIAGNOSIS OF TRICHOMONIASIS FROM *Milvus migrans, Tyto alba* AND *Accipiter badius sp.* S.S. Jadhav, B.I. Akhunji, V. Sanghvi, and O. Kinjawadekar	77
WHM-36	SURGICAL MANAGEMENT OF OLD PATAGIAL LACERATION IN JUVENILE PAINTED STORK (*Mycteria leucocephala*) S.S. Jadhav, N.S. Purohit , S. Everett , V. Sanghvi	78
WHM-37	PRELIMINARY STUDY OF CROSS MATCHING OF BLOOD IN INDIAN SLOTH BEAR (*Melursus ursinus*) Pushkar Banka, Adhithyan and Arun A Sha	79

WHM-38	AMPUTATION OF GANGRENOUS TAIL IN GRAY LANGUR (*Semnopithecus hypoleucos*) Akash, Mamta Mishra, Mohar Singh, Rajesh Kumar and M. Hoque	79
WHM-39	PATHOLOGY OF NON-HUMAN PRIMATE (NHP) MORTALITIES IN KFD ENDEMIC AREAS OF WESTERN GHATS IN SHIMOGA, KARNATAKA Kavitha Rani B., Manjunatha SS, Sundareshan S, Madhavaprasad C B, Jayaramu GM, Pradeep B S, Kiran HJ, Satish ES, Sunil Kumar B.S. and Amit H	80
WHM-40	PATHOLOGY OF OXALOSIS IN A BONNET MONKEY – A CASE REPORT Kavitha Rani B, Manjunatha S. S, Jayaramu G.M.,Kiran H.J., Satish E.S, Amit H. and Sunil Kumar B.S.	81
WHM-41	SURGICAL MANAGEMENT OF MANDIBULAR FRACTURE IN A CROW (*Corvus splendens*) AND A POND HERON (*Ardeola*) - A CASE REPORTS Ushma Patel, S. V. Upadhye, S. B. Akhare, Gauri Khante and P. T. Jadhao	81
WHM-42	SUCCESSFUL MANAGEMENT OF BILATERAL METACARPAL FRACTURE IN *Antilope cervicapra* A.A.Jadhav, M.G. Thorat, R.V. Raulkar, A.A. Mitra, K.S. Pawar, and K.N. Tayade	82
WHM-43	THERAPEUTIC MANAGEMENT OF RESCUED LEOPARD CUB A.A. Mitra, M.G. Thorat, R.V. Raulkar, A.A. Jadhav, K.S. Pawar, and K.N. Tayade	83
WHM-44	DEATH DUE TO PULMONARY TUBERCULOSIS IN A BLACK BEAR Sanjiv Kumar, Deepak Kumar, GD Singh and Ramesh Tiwary	84
WHM-45	CONSERVATIVE TREATMENT OF THORACOLUMBAR SPINAL INJURY IN A MALE LEOPARD (*Panthera pardus*) Vanishree, Sujay C. S. and Nikita Salian	84
WHM-46	AVIAN POX: A WIDESPREAD INFECTIOUS VIRAL DISEASE OF BIRDS Akriti Ballabh	85
WHM-47	MANAGEMENT OF PYODERMA IN A SLOTH BEAR Shalini A.S., Dhoot V.M., Upadhye S.V., Gawande A.P., Pawshe M.D. and Kolangath S.M.	86
WHM-48	MANAGEMENT OF WOUND AT THE BASE OF EAR PINNA IN A SLOTH BEAR CUB Shalini A.S., Upadhye S.V., Pawshe M.D, Kalyani Thakur and Kolangath S.M.	87
WHM-49	TREATMENT OF WOUND AT THE METATARSAL REGION IN AN ADULT FEMALE BLUE BULL Shalini A.S., Pawshe M.D, Badane B.K., Upadhye S.V., Dhoot V.M and S.M. Kolangath	87
WHM-50	SUCCESSFUL HAND REARING OF FOUR LEOPARD CUBS Shalini A.S., Pawshe M.D., Dhoot V.M., Upadhye S.V. and S.M. Kolangath	88
WHM-51	HYPOTHERMIA IN A SUB ADULT NILGAI - A CASE REPORT Shalini A.S., Pawshe M.D, Upadhye S.V., S.M. Kolangath and Kriti Dohre	88
WHM-52	SUCCESSFUL MANAGEMENT OF HEPATOZOONOSIS IN A SUBADULT MALE TIGER (*Panthera tigris*) Dhoot V.M., Shalini A.S., Kolte S.W., Pawshe M.D, Upadhye, S.V. and Kolangath S.M.	88
WHM-53	SUCCESSFUL HAND REARING OF SLOTH BEAR CUB Shalini A.S., Dhoot V.M., Upadhye S.V., Gawande A.P., Kolangath S.M. and Pawshe M.D.	89
WHM-54	SURGICAL CORRECTION OF DEEP LACERATED WOUNDS IN AN INDIAN ROCK PYTHON (*Phython molurus*) Reji Varghese, Laiju M. Philip, Praveen M. K., Sharat Joshi., Lavanya,B. and Syam K. Venugopal	89
WHM-55	RETROSPECTIVE STUDY OF ANAESTHETIC MANAGEMENT OF SNAKES AT TRANSIT TREATMENT CENTRE Syed Bilal Ali, Mayur R. Kate and Prabhu Nath Shukla	90
WHM-56	RETRIEVAL OF AIR GUN PELLETS FROM VARIOUS BODY LOCATIONS IN RAT SNAKE Mayur R. Kate and Syed Bilal Ali	90
WHM-57	SURGICAL CORRECTION OF ENTEROCUTANEOUS FISTULA IN AN INDIAN ROCK PYTHON (*Python molurus*) Mayur R. Kate, Syed Bilal Ali and Tista Joseph	91
WHM-58	INTRAMEDULLARY PINNING OF FEMUR IN BLACK BRITTEN Mayur R. Kate, Syed Bilal Ali	91
WHM-59	ACCIDENTAL MANDIBULAR FRACTURE IN A BLACK BUCK AND ITS SURGICAL MANAGEMENT Mayur R. Kate and Syed Bilal Ali	92

WHM-60	SUCCESSFUL MANAGEMENT OF BILATERAL TARSO METATARSUS (SHANK) IN A GREATER COUCAL CROW PHEASANT (BHARDWAJ) Sanjay J. Gaikwad	92
WHM-61	CASE REPORT OF POST MORTEM FINDINGS OF STRIPED DOLPHIN Prasad Khedkar and Acharya P.R.	93
WHM-62	SUCCESSFUL INTRAMEDULLARY PINNING FOR FRACTURE MANAGEMENT OF RADIUS ULNA BONE IN SHORT NOSED FRUIT BAT Mayur R. Kate and Syed Bilal Ali	93
WHM-63	STUDIES ON PREVALENCE AND THERAPEUTIC MANAGEMENT OF ENDOPARASITISM IN CAPTIVE WILD CARNIVORES OF CHHATTISGARH S. Chandrakar, S. Roy, J.K. Khutey, J. Singh, S.L. Ali, D. Markandey and K. Jambagi	94
WHM-64	PREVALENCE AND THERAPEUTIC MANAGEMENT OF GASTROINTESTINAL PARASITISM IN CAPTIVE WILD HERBIVORES OF CHHATTISGARH S. Chandrakar, S. Roy, J.K. Khutey, J. Singh, S. L. Ali, P.Dinkar and Seema Chelak	94
WHM-65	ACCIDENTAL SNAKE BITE IN VARIOUS PROFESSIONALS: AN OVERVIEW J. Singh, S. Mallik, S.L. Ali and Somesh Joshi	95
WHM-66	THERAPEUTIC MANAGEMENT OF INFECTIOUS STOMATITIS IN AN INDIAN ROCK PYTHON J. Singh, S. Mallik, S.L. Ali, N.E. Gade, S. Meshram, K. Jambagi and Bijendra Sahu	96
WHM-67	SURGICAL EXCISION OF A FIBROMA IN AN INDIAN ROCK PYTHON (*Python molurus*) Chetan Dilip Vanjari	96
WHM-68	MANAGEMENT OF CRANIAL INJURY IN INDIAN PYTHON (*Python molurus*) Shobha Jawre, Devendra Podhade, Amol Rokdhe, Babita Das and Madhu Swami	97
WHM-69	BULLET SHOT INJURY AND DEATH IN A LEOPARD (*Panthera pardus*) Manjunatha, S.S., Kavitha Rani, B. Jayaramu, G.M.and Vinay, S.	97
WHM-70	ISOLATION OF MULTIDRUG RESISTANT *Pseudomonas spp.* FROM WOUNDS IN WILD ANIMALS: A POTENTIAL PUBLIC HEALTH CONCERN J. Singh, S.L. Ali, C. Sannat, N.E.Gade, S. Meshram, K. Jambagi and D. Markandey	98
WHM-71	SUCCESSFUL INTRAMEDULLARY PINNING FOR FRACTURE MANAGEMENT OF TIBIOTARSUS BONE IN YELLOW FOOTED GREEN PIGEON M. R. Kate, Syed Bilal Ali and S. B. Akhare	99
WHM-72	CASE REPORT OF SEIZEURES IN INDIAN PALM CIVET CAT Prasad Khedkar	99
WHM-73	REPAIR OFA COMPOUND FEMUR FRACTURE IN AN INDIAN JACKAL (*Canis aureus indicus*) BY INTERNAL FIXATION Chetan Dilip Vanjari	100
WHM-74	CERCLAGE WIRING AND ACRYLIC FOR FIXATION BEAK FRACTURE IN AN OSTRICH K.Sridhar, Boon Alwin and Pa.Kalaignan	101
WHM-75	CRYOSURGICAL MANAGEMENT OF CHRONIC TAIL WOUND IN AN INDIAN ROCK PYTHON J. Singh, S. Mallik, S.L. Ali, D. Markandey, S. Meshram, K. Jambagi and Bijendra Sahu	101
WHM-76	TOXOCARA ELEPHANTIS (ASCARIASIS) INFESTATION IN AN ASIAN ELEPHANT CALF AND ITS THERAPEUTIC MANAGEMENT Nikitasha Bora, Samshul Ali, Kalyan Sarma, Parimal Roychoudhury, Chethan G.E. ,H. Prasad, J. B. Rajesh, G. Jagan Mohan Rao, S. K. Behera, Dhruba Das and Bhaskar Choudhury	102
WHM-77	THE ELEPHANT CALF KILLER – ELEPHANT ENDOTHELIOTROPIC HERPES VIRUS – A SUCCESSFUL TREATMENT STORY Dayamon D. Mathew, C. S. Jayakumar, Ajithkumar G. S., Manu M., Naresh Kumar Singh, and Rahul K. Udehiya	103
WHM-78	SUCCESSFUL MANAGEMENT OF PARTIAL TENDON RUPTURE IN BLACK KITE Sawant S. S., Ingawale M.V., Patil M.G., Pawshe C.H., and Acharya P.R.	103
WHM-79	SURGICAL MANAGEMENT OF COMPOUND TIBIOTARSUS FRACTURE IN A ROSE RINGED PARROT (*Psittacula krameri*) Rajesh Kumar, Aakanksha, Manjusha, S, N.K. Verma and M. Hoque	104
WHM-80	BENEFITS OF OPERANT CONDITIONING IN EFFECTIVE VETERINARY CARE OF CAPTIVE SLOTH BEAR (*Melursus ursinus*) Karthikeyan C., and Hussain Basha	105
WHM-81	CANINE DISTEMPER IN AN ASIAN PALM CIVET (*Paradoxurus hermaphroditus*) AND ITS IMPLICATIONS IN ANIMAL HEALTH Ranjini A.R., Sherin B Sarangam., Varsha Mary Mathai., and Jayasree K. S.	105

WHM-82	CHRONIC KIDNEY DISEASE IN A RESCUED SLOTH BEAR (*Melursus ursinus ursinus*) – A CASE REPORT Arun A Sha and Adhithyan NK	106
WHM-83	SURGICAL MANAGEMENT OF TRAUMATIC CROP FISTULA IN WILD PIGEON Mayank Parwari and Jignasha M Parmar	107
WHM-84	FORELIMB AMPUTATION IN A GOLDEN JACKAL (*Cuon aurius*) Dhanalakshmi, S., Vanishree, Malati Naik and Rashmi L	107
WHM-85	GIGANTIC ILLNESSES- AN EXPLORATION BY AUTOPSY Nandakumar. S	108
WHM-86	CARAPACE FRACTURE AND ITS MANAGEMENT IN AN INDIAN FLAPSHELL TURTLE (*Lissemys punctata*)- A CASE REPORT Prabha Sharma, Amolak Sharma, Gulshan Kumar and R P Pandey	109
WHM-87	SURGICAL CORRECTION OF RECTAL PROLAPSE IN AN INDIAN GREY MONGOOSE PUP (*Herpestes edwardsii*) Lavanya, B., Reji Varghese, Laiju M. Philip, Sharat Joshi, Praveen M. K., and Syam K. Venugopal	109
WHM-88	BREECH PRESENTATION – A CASE REPORT OF FOETAL DYSTOKIA IN RHESUS MACAQUE Prajakta, Ilayaraja S, Acharya P.R. Shivani, Baiju Raj M V. and Arun A.Sha	110
WHM-89	A CASE REPORT OF SUBMANDIBULAR ABSCESS IN LEOPARD Bawaskar, S.S., A. B. Motghare, M.S. Bawaskar and R.S. Khobragade	111
WHM-90	AURAL ABSCESS IN A RED EARED SLIDER (*Trachemys scripta elegans*) AND ITS SURGICAL MANAGEMENT J. Singh, S.L. Ali, D. Markandey, K. Jambagi, Govinda Sahu and U. Baghel	111
WHM-91	SURGICAL MANAGEMENT OF AN EXCESSIVELY LARGE TESTICULAR TUMOR IN A BLUE BULL (*Boselaphus tragocamelus*) J. Singh, S.L. Ali, R.K. Verma, R.L. Rakesh, B. Shrimali, S. Jaiswal and P.Sao	112
WHM-92	CHALLENGING EXPERIENCE DURING TREATMENT OF OCULAR INJURY IN A WILD BUFFALO (*Bubalis arnee*) J. Singh, R.K. Verma, S. Joshi , N. E.Gade, S.L. Ali, K. Jambagi and Preety Singh	112
WHM-93	SUCCESSFUL RELEASE OF SEIZED INDIAN PANGOLIN (*Manis crassicaudata*) TO ITS NATURAL HABITAT S.K. Joshi, R. K. Verma , J. Singh, R.L.Rakesh, Preety Singh, A. Sonwani and B. Shrimali	113
WHM-94	TRANSLOCATION OF WILD BUFFALOES FROM ASSAM TO CHHATTISGARH DESPITE COVID LOCKDOWN J. Singh, R. K.Verma, S.K. Joshi, A. Sonwani, B. Choudhary, S Ali and P. Balasumatry	114
WHM-95	POST MORTEM EXPERIENCE OF RESCUED INDIAN PANGOLIN (*Manis crassicaudata*) R. L. Rakesh, S. K. Joshi, J. Singh , R.K.Verma, Preety Singh, B. Shrimali, S. Mishra, A.Sonwani and Lileshwar Chaudhary	115
WHM-96	MANAGEMENT OF AGED CAPTIVE WILD ANIMALS IN ZOOS: ISSUES AND CHALLENGES K. Raja Kishore and B. Sravani	115
WHM-97	MEDICAL MANAGEMENT OF MANGE IN A CAPTIVE ROSY PELICAN (*Pelicanus onocrotalus*) Powar Komal,Valsarajan Dipika, Tripathi Sanjay A.,Kale Madhumita, and Shah Neha	116
WHM-98	IMPING OF FLIGHT FEATHERS IN A BLACK KITE (*Milvus migrans*) Shivani Jain, Meghana Pemmaiah, Purva Nimkar, and Silambarasan R	117
WHM-99	GERIATRIC MANAGEMENT OF A HYBRID LIONESS Khandekar Yashwant, Karawle M.S.l, Tripathi Sanjay A and Powar Komal	117
WHM-100	SUCCESSFUL MANAGEMENT OF TRANSPORTATION STRESS IN A LEOPARDESS (*Panthera pardus fusca*) AND ROYAL BENGAL TIGRESS (Panthera tigris tigris) DURING QUARANTINE PERIOD USING ENRICHMENT ACTIVITIES AND INTERACTION Shinde Amol, Powar Komal, Valsarajan Dipika, Sirsat Devanand Satam Abhishek, and Tripathi Sanjay A	118
WHM-101	INDUCTION OF MOLTING IN A CAPTIVE FEMALE HUMBOLDT PENGUIN (*Spheniscus humboldti*) USING MANAGEMENTAL PRACTICES Kale Madhumita, Tripathi Sanjay A., Mangnale Govind, Shah Neha and Shejul Ranjit	119
WHM-102	STUDY OF CHANGES IN SERUM BIOCHEMICAL PARAMETERS DURING FRACTURE HEALING IN WILD RABBIT Jyotsana Bhatt, N S Jadon, Priyanka Pandey and Sara Kaushal	120
WHM-103	SUCCESSFUL HAND REARING OF THREE WILD TIGER CUBS Kundan Hate and Sunil Bawaskar	120

WHM-104	RECONSTRUCTIVE SURGERY PERFORMED TO RESTORE COMPLETE FLYING ABILITY OF THREE PELICANS (*Pelecanus*) WITH PATAGIUM AND PRO-PATAGIUM LACERATION Ushma Patel, Shirish Upadhye, Chetan Patond, Rohit Gangwal, and Abhishekh Narayanan	121
WHM-105	MANAGEMENT OF STRESS AND LAMENESS IN A LONG BILLED VULTURE (*Gyps indicus*) Devendra Podhade, Ranjeet Harne, Amol Rokde, Nidhi Rajput and Somesh Singh	112
WHM-106	UNPREDICTED MORTALITY OF SPOTTED DEER (*Axis axis*) AT MINI ZOO PAHALGAM, KASHMIR DURING PRE SEASONAL HEAVY SNOWFALL - DIAGNOSIS, TREATMENT, RESCUEAND CONTROL Umar Nazir Zahid, Dil Mohammed Makhdoomi, A M Pawde,K N Vishwa, K Mahendran, Rashid Yahya Naqash, Rouf Zargar, and M.A Gazi	122
WHM-107	MANAGEMENT OF SNARE TRAP WOUND IN SLOTH BEAR (*Melursus ursinus*) AT GOREWADA RESCUE CENTRE, INDIA Upadhye S.V., Dhoot V.M., Pawshe M.D., Bhadane B.K., Shalini A. S., and Kolangath S.M.	123
WHM-108	SURGICAL MANAGEMENT OF AVIAN LONG BONE FRACTURES USING INTRAMAEDULLARY PINNING ALONE IN COMPARISON TO INTRAMEDULLARY PINNING AND POLYMETHYL METHACRYLATE Ushma Patel, B. M. Gahlod, S.V. Upadhye, P.T. Jadhao, S.B.Akhare, ShalakaSalvekar and Gauri Khante	124
WHM-109	A COMPARATIVE STUDY BETWEEN ISOFLURANE, HALOTHANE AND XYLAZINE-KETAMINE COMBINATION FOR GENERAL ANAESTHESIA IN BIRDS Ushma Patel, B.M.Gahlod, P. T. Jadhao, S. V. Upadhye, Gauri Khante, Shalaka Salvekar and S.B.Akhare	125
WHM-110	INTERVENTION FOR MANAGEMENT OF A SIBERIAN BIRD IN SHOCK J. L. Singh, R. S. Sandhu, Arun Kumar, Manish Kumar, Shivam kartikey Bhardwaj	126
WHM-111	MANAGEMENT OF SEPTIC WOUND CREATED AFTER PARTIAL ELECTROCUTION IN AN INDIAN LANGUR (*Semnopithcus*) BY SURGICAL INTERVENTION J.L.Singh, R.S. Sandhu, Arun Kumar, Manish Kumar, Shivam kartikey Bhardwaj and Animesh kumar Mishra.	126
WHM-112	MANAGEMENT OF A CASE OF ELECTROCUTION, SEPTIC WOUND AND SHOCK IN MONKEY *(Macaca fasciacularis)* J. L. Singh, Anand Kumar Singh, Sawan Kumar, Himanshu Kumar and R. S. Sandhu	127
WHM-113	MANAGEMENT OF ELECTROCUTION WOUNDS IN A LEOPARD (*Panthera pardus*) USING PULSED LAVAGE THERAPY Upadhye S.V., Dhoot V.M., Bhadane B.K., Shalini A. S., Kolangath S.M, Pawshe M.D., Bhadane B.K. and Tista Joseph	128
WHM-114	SHELL FRACTURE REPAIR IN AN INDIAN TENT TURTLE (*Pangshura tentoria*) USING EPOXY AND FIBREGLASS MESH- A CASE STUDY Khante G.S., Tista Joseph, Ambika Arvind, Upadhye S.V., and Akhare, S.B.	128
WHM-115	IDIOPATHIC EPILEPSY AND ITS MANAGEMENT IN CAPTIVE SLOTH BEARS Acharya P.R., Shivani , Prajakta Ilayaraja S , Baijuraj MV. and Arun A.Sha	129
WHM-116	MANDIBULAR FIXATION IN AN INDIAN FLAPSHELL TURTLE (*Lissemys punctata*) Upadhye S.V., Tista Joseph, Ambika Arvind,Khante G.S., and Ransingh A.	130
WHM-117	PREVALENCE OF INTESTINAL HELMINTHS INFECTION IN AILING PIGEONS Panchbhai C.G., Dhoot V.M., Bhojne G.R., Kalyani Thakur, Kriti Dohre and Sameeksha C.	131
WHM-118	AVIAN BOTULISM OUTBREAK IN MIGRATORY BIRDS - AN ABRUPT FLIGHT TO SAMBHAR LAKE, RESCUE AND REHABILITATION Rohit Gangwal, N.V.K. Ashraf, Abhishek Narayanan, Ushma Patel, Bharghavi, Disha Sharma, Joy Gardner, Shamshul Ali, Henna Ganjawala, Nikita Mehta and Mrugank Prabhu	131
WHM-119	AN ATTEMPT TO TAKE NORMAL BODY TEMPERATURE IN CAPTIVE SLOTH BEARS Acharya P.R., Atul Gupta, Ilayaraja S , Baiju raj M V and Arun A.Sha	132
WHM-120	OESOPHAGOTOMY IN AN INDIAN FLAPSHELL TURTLE (*Lissemys punctata*) FOR REMOVAL OF FISH HOOK. Tista Joseph, Upadhye S.V., Ambika Arvind, Adey K., Khante G.S., Amit Kshirsagar and Aditya Singh	133
WHM-121	INTESTINAL OBTRUCTION IN ELEPHANTS A G Dubey, N. Lakshminarayanan and A S Kumar	134
WHM-122	MANAGEMENT OF UROPHAGIA INDUCED BALANOPOSTHITIS IN CAPTIVE SLOTH BEARS Acharya P.R., Shivani, Prajakta Ilayaraja S , Baiju raj MV and Arun A.Sha	135

WHM-123	SURGICAL REPAIR OF TRAUMATIC CROP FISTULA IN A PIGEON (*Columba livia*) Rajesh kumar, Aakanksha N.K. Verma and M. Hoque	136
WHM-124	SUCCESSFUL AMBULATION AFTER TIBIAL FRACTURE REPAIR BY EXTERNAL COAPTATION IN INDIAN PEAFOWL (*Pavo cristatus*) S. S Vende, S. S. Pawar, G. S. Khandekar, S. A. Chauhan, S. V. Gaikwad., A. Barate and G. V.Pande.	136
WHM-125	SUCCESSFUL MANAGEMENT OF VARIOUS SURGICAL AFFECTIONS IN REPTILES - A RETROSPECTIVE STUDY. S. D. Raibole, Dharma. Raibole, G. S. Khandekar, S. A. Chauhan, S. D. Tripathi, V. Nimbalkar and G. S. Khandekar.	137
WHM-126	SUCCESSFUL MANAGEMENT AND POST-OPERATIVE CARE OF RUPTURED EPULIS IN CAPTIVE DANCING SLOTH BEAR Acharya P.R. , Shivani, Prajakta Ilayaraja S , Baiju raj MV and Arun A.Sha	138
WHM-127	METASTATIC HEMANGIOSARCOMA IN A ROYAL BENGAL TIGER Chandrashekhar S. Mote, R.V. Jadhav, V.S. Dhaygude, B.P. Kamdi,N.K. Nighot and Divya Sabharwal	138
WHM-128	MANAGEMENT OF PORCUPINE QUILL INJURY IN WILD TIGER CUB IN TIPESHWAR WILDLIFE SANCTUARY, MAHARASHTRA. Chetan Patond, Ravikiran Govekar, Subhash Puranik and Sandip Chavan	139
WHM-129	PALLIATIVE AND REHABILITATIVE SILICON BASED PROSTHETIC FLIPPER FOR A LARGE OLIVE RIDLEY SEA TURTLE " VASUNDHARA" S. B Walvekar, G. S. Khandekar, S. A. Chauhan, C.Halyal, K. R.Powar, V. Kamble, S. Sawant	140
WHM-130	SURGICALLY CORRECTION OF TRAPPED FISHING HOOK IN INDIAN SOFTSHELL AND INDIAN *Nilssonia* TURTLE S. B. Walvekar, G. S. Khandekar, S. P. Salvekar, S. V. Sonawale, R. R. Mestri Sutar, A. D. Kumbhar, D. H. Bhosale and A.V.Suryawanshi	141
WHM-131	CORRECTION OF FRACTURED WING BONES IN WILD BIRDS BYMEDULLARY PINNING S. B. Walvekar, V. Climent Ben, G. S. Khandekar, R. R. Kale, S. B. Salvekar, V.D. Kamble, S.V. Sawant, R. R. Mestri Sutar, A. D. Kumbhar, S. Y. Harale and A. S. Kulkarni	141
WHM-132	SUCCESSFUL CLINICAL MANAGEMENT OF DYSTOCIA IN NANITISNAKE S.S.Pawar and Vende S.S.	142
WHM-133	MANAGEMENT OF OUTBREAK OF HAEMORRHAGIC SEPTICAEMIA AND CHRONIC FASCIOLOSIS IN SPOTTED DEER (*Axis axis*) M Karikalan, K Mahendran, Hira Ram, Chandra Mohan S, M Saminathan,K N Viswas and A M Pawde	142
WHM-134	RECOVERY OF AIR GUN PELLETS FROM RESCUED LEOPARD AT POST-MORTEM EXAMINATION Pawshe M.D., Kolangath S.M., Upadhye S.V., Dhoot V. M., Shalini A.S., Tista Joseph and Megha Kaore	143
WHM-135	MANANGEMENT OF COLIC IN AN ORPHANED NILGAI CALF (*Boselaphus tragocamelus*) Pawshe M.D., Shalini A.S., Upadhye S.V., Dhoot V.M., Kolangath S.M., and Gawande A.P. and Bhadane B. K.	144
WHM-136	SUCCESSFUL MANAGEMENT OF SUBCUTAEOUS ABCESS IN A NILGAI CALF Pawshe M.D, Shalini A.S., Upadhye S.V., Dhoot V.M., S.M. Kolangath, Bhadane B.K., Gawande A.P. and Patil M. S.	144
WHM-137	ANCYLOSTOMUM INFECTION IN A SLOTH BEAR- A CASE REPORT Pawshe M.D., Shalini A.S., Dhoot V.M., Upadhye S.V., S.M. Kolangath and Kolte S.W.	145
WHM-138	SUCCESSFUL REMOVAL OF FOREIGN BODY OBSTRUCTION (BONE) FROM THE ORAL CAVITY OF A FEMALE TIGRESS Shalini A.S., Upadhye S.V., Dhoot V. M., Pawshe M.D., Gawande A.P., and Kolangath S.M.	145

SESSION-IV
ZOO BIOLOGY & CONSERVATION

Code	Title and Author(s)	Page No(s)
	LEAD/ INVITED PAPERS	
ZBC LP-1	TEACHING HUMANE CARE: IMPROVING ELEPHANT CARE Steve Koyle	147
ZBC LP-2	FROM THE KILLER SNARES TO THE ACTIVE RADIO-COLLARS: THE MANAGEMENT OF SNARE INJURIES IN TIGER *(Panthera tigris)* AND STUDYING THEIR DISPERSAL IN TIPESHWAR WILDLIFE SANCTUARY, MAHARASHTRA, INDIA Ravikiran Govekar, Parag Nigam, Bilal Habib, Chetan Patond, Pramod Panchbhai and Sandip Chavan	150
ZBC LP-3	BRITTLE AND FRAGILE LEOPARD SKIN AND TROPHY RESTORED Leena Zilpe Haate and B.V. Kharbade	154
ZBC LP-4	IS GURNEY'S PITTA ON THE BRINK OF EXTINCTION? Nay Myo Shwe, Niti Sukumal, Mark Grindley and Tommaso Savini	157
ZBC LP-5	A REVIEW OF *Hipposideros lankadiva* KELAART, 1850 *(Chiroptera: Hipposideridae)* WITH A DESCRIPTION OF A NEW SUBSPECIES FROM MYANMAR Paul Bates, Ohnmar Tun, Moe Moe Aung, Aung Lu, M. Roi Lum and Mie Mie Sein	158
ZBC LP-6	ANIMAL WELFARE AND ETHICAL CONCERNS IN WILDLIFE VETERINARY PRACTICE IN INDIA A. Sha Arun	159
ZBC LP-7	PROBLEMS OF "TOO FEW" AND "TOO MANY" CONSERVATION CHALLENGES OF ELEPHANTS IN MYANMAR Khyne U Mar	161
	ABSTRACTS	
ZBC-01	WEIGHT AND BODY MEASURMENTS OF HAND REARED FOUR HORNED ANTILOPE FAWN Bawaskar S.S., A. B. Motghare, M.S. Bawaskar and R.S. Khobragade	165
ZBC-02	TIGER (*Panthera tigris*) IN NON PROTECTED AREAS THE CASE STUDY OF THE KATLABODI TIGRESS OF KALMESHWAR KONDHALI BLOCK, NAGPUR, MAHARASHTRA Kundan Hate and Dhanush Kawalkar	165
ZBC-03	MANAGEMENT OF THEILARIOSIS IN A FRIESWAL CATTLE FARM AFTER THE LANDSLIDE IN KERALA. Seena, T. X., Archana S.N., Amitha Thomas, Justin Davis and Matilda Joseph	166
ZBC-04	EMERGENCE OF ZOONOSES DUE TO HUMAN INTERVENTION AMONG THE WILDLIFE: A CASE STUDY OF KYASANUR FOREST DISEASE OUTBREAKS IN KERALA Gayathri S. Lal and Muhammed Asif M.	167
ZBC-05	TRADITIONAL MEDICINES FROM WILD ANIMAL RESOURCE *vis-á-vis* ITS CONSERVATION STATUS Sharma, G.	168
ZBC-06	MONITORING THE DISPERSAL OF TIGER (*Panthera tigris*) FROM KALMESHWAR-KONDHALI BLOCK, NAGPUR TO POHRA-MALKHED FOREST RANGE, AMRAVATI Kundan Hate and Dhanusha Kawalkar	169
ZBC-07	INVESTIGATION ON THE POTENTIAL OF IN VITRO GAS PRODUCTION TECHNIQUE FOR ASSESSING THE NUTRITIVE VALUE OF FEEDS CONSUMED BY ELEPHANTS Nandana Chandrasekhar, K. S. Ajith, K. Ally, A. Deepa and T. S. Rajeev	170
ZBC-08	PARASITES IN WILD LIFE AND FREE-LIVING OF JAMMU REGION Sanku Borkataki, R.Katoch and Ankur Sharma	170
ZBC-09	CREATING DATABASE FOR ANIMALS USING CLOUD ONLINE FOR CARE OF WILD ANIMALS Shourya Gupta and Dr. Devender Kumar	171
ZBC-10	BEHAVIORAL STUDY OF ROYAL BENGAL TIGER AFTER APPLYING COGNITIVE ENRICHMENT Suvarna Kawale, Bawaskar, S. S. and Motghare, A. B	172

ZBC-11	FEEDING ENRICHMENT OF SLOTH BEAR (*Melursus ursinus*) AT MAHARAJBAG ZOO Suvarna Kawale, Bawaskar, S. S. and Motghare, A. B.	172
ZBC-12	TEMPORAL OVERLAP IN CARNIVORE COMMUNITY OF KANHA TIGER RESERVE Anup Pradhan, Ujjwal Kumar, Jayant Bora, Neha Awasthi, Shravana Goswami, Qamar Qureshi and Yadvendradev V. Jhala	174
ZBC-13	CAPTIVE RED JUNGLE FOWL (*Gallus gallus*) PREFERRED WILD HABITAT IN CAPTIVITY Sanjit Kumar Saha	174
ZBC-14	FEEDING ENRICHMENT IN SLOTH BEARS EXPERIMENTS AND INTERVENTIONS Kolangath S.M., Pawshe M.D., Shalini A.S., Upadhye S.V., and Dhoot V.M.	175
ZBC-15	BAMBOO PLANTATION AS A NATURAL ENRICHMENT IN LEOPARD (*Panthera pardus*) ENCLOSURE Kolangath S.M., Pawshe M.D., Shalini A.S., Upadhye S.V. and Dhoot V.M.	176
ZBC-16	NEW RECORD OF COMMON BANDED PEACOCK (*Papilio crino*) IN SEMINARY HILLS, NAGPUR, MAHARASHTRA, INDIA. Chhapekar S.D., Shendge A., Chichkhede K.H., Kolangath S.M.	176
ZBC-17	IMPACT OF ANTHROPOGENIC PRESSURE ON WILD UNGULATES IN NAGARJUNSAGAR SRISAILAM TIGER RESERVE, ANDHRA PRADESH Ashok kumar, Yadvendradev Vikramsinh Jhala and Qamar Qureshi	177
ZBC-18	ASSESSMENT OF WATERBIRD COMMUNITY IN WADANDRA LAKE OF UMRED TEHSIL IN NAGPUR DISTRICT OF MAHARASHTRA (INDIA) Ashish Kumar Jha and Jagruti Roy	178
ZBC-19	FEEDING ENRICHMENT (USING BAMBOO) TO ASSESS THE WELFARE AND ACTIVE BEHAVIOR IN CAPTIVE SLOTH BEARS Sameena Iza, Sujay, Mukunda Chandra B, Ranganatha. B and Divya	179
ZBC-20	DIVERSITY AND DISTRIBUTION OF SPIDER FAUNA (FAMILY ARANEIDAE) IN AND AROUND KARANJA SOHOL WILDLIFE SANCTUARY, INDIA Amrita Shirbhate and Milind Shirbhate	179
ZBC-21	COLOUR PERCEPTION AND ATTRACTION STUDY IN CAPTIVE SLOTH BEARS (*Melursus ursinus*) Prajakta Rao and Arun A Sha	180
ZBC-22	IMPACT OF FEEDING CHICKEN MEAT OVER BEEF MEAT WITH BONE ON GASTROINTESTINAL PARASITES IN CAPTIVE INDIAN LEOPARDS(*Panthera pardus fusca*)– A REVIEW Nikhil S. Bangar,A. Sha Arun, Mahendra B. Dhore	181
ZBC-23	VERTICAL STRATIFICATION OF BIRD SPECIES FROM A HERONRY IN THRISSUR KERALA Ambika Nandini R Menon and K. Syamala	181
ZBC-24	HIGHLIGHTS OF AN ANIMAL KEEPER WORKING IN A LEOPARD ENCLOSURE OF TIGER AND LION SAFARI, SHIMOGA. Nagendra Naik, Ranganatha B. and Sujay Suresh	182
ZBC-25	CRITICALLY ENDANGERED INDIAN VULTURE VERGE OF EXTINCTION Akriti Ballabh	183
ZBC-26	STUDY OF AVIFAUNAL DIVERSITY IN AND AROUND MANDATUKUM LAKE OF MUL TEHSIL ,DIST. CHANDRAPUR G. A. Chaudhari and Shashikant Sitre	184
ZBC-27	RARE SIGHTING: DUSKY EAGLE OWL (*Bubo coromandus*) IN NAGPUR TERRITORIAL FOREST RANGE, MAHARASHTRA Vinit Arora	184
ZBC-28	SENSITIZING THE ANIMAL CARE STAFF FOR THE IMPORTANCE OF ENVIRONMENTAL ENRICHMENT FOR THE BETTER QUALITY OF LIFE IN CAPTIVE WILDLIFE Saddam Husen, G M. Vishwanath and Prakash G. P.	184
ZBC-29	DIVERSITY AND HABITAT PREFERENCE OF PRAYING MANTIDS IN GOREWADA RESERVE FOREST,NAGPUR, MAHARASHTRA Chhapekar S.D., Kolangath S.M., Chichkhede K.H., Sawant D., Pawshe M.D. and Shalini A.S.	185
ZBC-30	BIOMASS BASED FUEL TO MAKE PORRIDGE FOR RESCUED SLOTH BEARS Allauddin and Dada peer	186

ZBC-31	A STUDY ON BIOLOGICAL RHYTHYMS OF HIMALAYAN YAKS Mohd Iqbal Yatoo, Mir Shabir, Syed Shafat Kubrevi, Ruskhsar Ahmad Dar, Kunzes Angmo, Maheshwar Singh Kanwar, Riyaz Ahmad Bhat, Muheet and Oveas Raffiq Parray	187
ZBC-32	CONSERVATION OF PREDATORS AND PARASITIODS OF COCONUT BLACK HEADED CATERPELLAR (*Opisina arenosella*) WALKER IN ARSIKERE REGION OF KARNATAKA STATE G.S. Chandrashekar, Prasad P. S, H. P. Maheswarappa, R. Siddappa, and Vishnuvardhana	187
ZBC-33	RANGING AND MOVEMENT PATTERNS OF ELEPHANTS IN NORTHERN CHHATTISGARH Ankit Kumar, N. Lakshminarayanan, Bivash Pandav and Ankush Dubey	188
ZBC-34	STUDY OF ECOLOGY AND DIVERSITY OF AM FUNGI ASSOCIATED WITH TEST PLANTS Mohd. Irfan	189
ZBC-35	SUCCESSFUL HAND REARING OF NINE NILGAI CALVES Pawshe M.D., Shalini A.S., Upadhye S.V., Dhoot V.M., Kolangath S.M., Patil M.S. and Gawande A.P.	190
ZBC-36	NESTING BEHAVIOR OF BIRD SHIKRA (*Accipiter badius*) ON NEEM TREE. Pandurang S. Pakhale and Dnyneshwari P. Pakhale	190
ZBC-37	COPROPHAGY (ALLOCOPROPHAGY) IN BIRD RED VENTED BULBUL (*Pycnonotus cafer*) Pandurang S. Pakhale and Dnyneshwari P. Pakhale	191
ZBC-38	SOCIAL STRESS INDUCED ANOREXIA IN A FEMALE MUGGER CROCODILE Vanishree, Nikita Salian and Sujay C.S.	192
ZBC-39	STUDY ON EFFECT OF LOCKDOWN ON BIRDS, BREEDING, MIGRATION, LAKES & ITS HABITAT IN NAGPUR DISTRICT (M.S.), INDIA. Avinash Londhe[1], Pooja Surkar Thakre[2], Minal Bhusari[3], Sanket Dharashivkar[4] and Harish Dhumal[5]	192
ZBC-40	SARS-COV-2 SPILLOVER FROM WILD ANIMALS: DECIPHERMENT AND MITIGATION OF ZOONOSIS Priyanka	194
ZBC-41	STUDIES ON DIVERSITY OF GASTROINTESTINAL PARASITISM INFECTION IN WILD HERBIVORES Bhaydiya Nilesh, Rokde Amol, Singh K. P., and Sharma Gurudatta	194
ZBC-42	FEEDING GUILDS OF AVIFAUNA OF NAVEGAON NATIONAL PARK, MAHARASHTRA, INDIA Chinchkhede K.H. and Kedar G.T.	195
ZBC-43	OPPORTUNISTIC PATHOGENS REPORTED IN RESCUED WILD ANIMALS R. V. Jadhav, A. G. Dubey and N. K. Nighot	196
ZBC-44	SUCCESSFUL HAND REARING OF ALEXANDRINE PARAKEETS Pawshe M.D., Upadhye S.V., Dhoot V.M., Kolangath S.M., Shalini A.S., Gawande A.P., Patil M.S., Bhadane B.K. and Khante G.S.	197
ZBC-45	EMERGENCE OF ZOONOTIC DISEASES DUE TO HUMAN INTERVENTION IN FOREST ECOSYSTEM - A CASE STUDY OF LYME DISEASE OUTBREAK IN WAYANAD, KERALA Muhammed Asif M and Gayathri S. Lal	197

SESSION-V
CONSERVATION BIOTECHNOLOGY & FORENSICS

Code	Title and Author(s)	Page No(s)
	LEAD/ INVITED PAPERS	
CBF/LP 1	ROLE OF DNA FORENSICS IN FIGHT AGAINST WILDLIFE CRIME AND ILLEGAL TRADE IN INDIA Dr. Ajay Gaur	199
CBF/LP 2	ASSISTED REPRODUCTION IN WILD ANIMAL SPECIES Pierre Comizzoli	201
	ABSTRACTS	
CBF-1	HOST-PARASITE INTERACTION WITH REFERENCE TO SEASON IN NILGIRI TAHR (*Nilgiritragus hylocrius*) IN WESTERN GHATS Biju S.	211
CBF-2	COMPARATIVE GROSS MORPHOMETRICAL STUDY ON APPENDICULAR SKELETON OF MALE AND FEMALE LION *(Panthera leo)* Jyoti Saini, P. L. Dhande, V. D. Shankapal and S. A. Gaikwad	211
CBF-3	ASSISTED REPRODUCTIVE TECHNOLOGY IN WILDLIFE Megha. B. Ambalkar and Chaitanya H. Pawshe	212
CBF-4	TUBERCULOSIS: AN UNDERLYING THREAT TO THE WILDLIFE HEALTH Nidhi Rajput, Nitin Gupta, Himanshu R. Joshi and Amol Rokde	213
CBF-5	MOLECULAR DETECTION OF *Panthera pardus* AND *Panthera tigris* USING NON-INVASIVE SCAT SAMPLES Pooja Acharya, Prabhakar Tembhurne, V M. Dhoot, G. R. Bhojane', Vijay Ingle, S.W. Bonde, M.S.Patil, Ajay Gawande, S.V. Upadhey, Nandkishor Kale, N. Rambabu and A. S. Bannalikar	214
CBF-6	DEVELOPING A MOLECULAR SEXING TECHNIQUE FOR CAVE-DWELLING SWIFTLETS (FAMILY: APODIDAE) Sanjeev Kumar Sharma, Prathamesh Gurjarpadhye, Shirish S. Manchi and Ram Pratap Singh	215
CBF-7	DETECTION OF MYCOBACTERIUM TUBERCULOSIS IN A CAPTIVE SLOTH BEAR BY MOLECULAR ANALYSIS Sidharth Shaji, GS Ajithkumar , S Nandakumar , Jacob Alexander and Baby Joseph	216
CBF-8	PATHOLOGY OF LEPTOSPIROSIS IN WHITE TIGER K. Sujatha, Dr. D. Raniprameela, Dr. Arun, Ch. Srilatha and A. Nasreen,	216
CBF-9	MOLECULAR AND MORPHOMETRIC APPROACHES FOR IDENTIFICATION OF *Canis* TAXA IN INDIA: CONSERVATION AND FORENSIC PERCEPTIVE Yellapu Srinivas and Yadvendradev Jhala	217
CBF-10	*Tachygonetria robusta* (PINWORM) INFESTATION CAUSING INTESTINAL IMPACTION IN AN INDIAN STAR TORTOISE (*Geochelone elegans*) C Purnima, Aparna Sandeep and Jacob Alexander	218
CBF-11	SAMPLES AND SAMPLING- A KEY TO DIAGNOSIS OF ELEPHANT ENDOTHELIOTROPIC HERPES VIRUS (EEHV) INFECTION G S Ajithkumar, S Nandakumar, C S Jayakumar and P R Prathiush	219
CBF-12	VETERINARY FORENSIC IMAGING – APPLICATION OF CT IMAGING IN DETECTION OF CHIP AND ITS SURGICAL RETRIEVAL IN A FALCON (*Falco berigora*) Sakar Palecha, P. Bishnoi, Satyaveer Singh, Mahendra Tanwar, Himanshu Vyas and Narendra Singh	220
CBF-13	FORENSIC INVESTIGATION OF AN ELEPHANT DIED DUE TO ELECTROCUTION Manjunatha, S.S., Jayaramu, G.M. Kavitha Rani, B. and Vinay, S.	220
CBF-14	A CASE OF EHRLICHIOSIS IN NILGAI P. M. Sonkusale, N. V. Kurkure and P.A. Tembhurne	221
CBF-15	AN INCIDENTAL CASE OF ANTHRACOSIS IN MONKEY Pratik N. Ingle Patil, P. M. Sonkusale, N. V. Kurkure and P.A. Tembhurne	222
CBF-16	CONSERVATION OF WILD LIFE SPECIMENS: A CASE STUDY Leena Zilpe Haate	222

CBF-17	COMPARATIVE GROSS ANATOMICAL STUDIES ON THE MANDIBLE OF BENGAL TIGER (*Panthera tigris tigris*) AND COMMON LEOPARD (*Panthera pardus*) Abhin Raj, K.P., Sreeranjini, A.R., Maya, S., Sunilkumar, N.S., Lucy, K.M., Leena Chandrasekhar and Sumena, K.B.	223
CBF-18	DETECTION OF *Mycobaterium Tuberculosis* USING REAL TIME NESTED PCR IN A SAMBAR DEER (*Rusa unicolor*) Valsarajan Dipika, Powar Komal, Tripathi Sanjay A., Sirsat Devanand	224
CBF-19	ANTIMICROBIAL RESISTANCE PROFILES AND MOLECULAR PHYLOGENY OF ESBL DETERMINANT GENES IN *Escherichia coli* IN CAMP ELEPHANTS OF KARNATAKA Lallianpuii Kawlni, Sanath Krishna Muliya, Priyanka Dutta, Mujibur Rehaman, Vishnupriya Kolipakam, T.K. Dutta, Belinda Vangchhia, Kafil Hussain, Qamar Qureshi and Yadvendradev Jhala	225
CBF-20	PARASITIC INFECTION IN HILL PRINIA: A CASE REPORT Rupali Masand	225
CBF-21	POST MORTEM INVESTIGATION OF DEATHS IN WILD BOARS AT BHADRA WILDLIFE RANGE, KARNATAKA Manjunatha, S.S., Kavitha Rani, B., Jayaramu, G.M., Kiran H. J. and Vinay, S.	226
CBF-22	PATHOLOGICAL FINDINGS IN COLD SHOCK IN A PEACOCK -A CASE REPORT Aprajita Johri and A.P.Singh	227
CBF-23	HISTOPATHOLOGICAL STUDY IN AILING PIGEONS Panchbhai C.G., Dhoot V.M., Bhojne G.R., Kalyani Thakur, Kriti Dohre and Sameeksha C.	227
CBF-24	EFFECT OF PROBIOTICS SUPPLEMENTATION ON FAECAL PROGESTERONE HORMONE IN ASIAN ELEPHANTS Dharmendra Chharang, Sheela Choudhary, Vinod Kumar, Govindhaswamy Umapathy, Hemant Joshi, Monika Karnani and Manju	228
CBF-25	POST MORTEM FINDINGS IN AN INDIAN SPOTTED EAGLE-A CASE REPORT S. Sood, A Sharma, N Nashiruddullah, S Rahman,A Kumar, and S Sharma	228
CBF-26	MORPHOMETRIC AND RADIOGRAPHIC CHARACTERISTICS OF THE SKULL IN CRESTED SERPENT EAGLE (*Spilornis cheela*) AND BROWN WOOD OWL (*Strix leptogrammica*) O.P. Choudhary, P.C. Kalita, A. Kalita and P.J. Doley	229
CBF-27	GROSS MORPHOLOGICAL AND LIGHT MICROSCOPIC STUDIES OF THE SPLEEN OF MALAYAN SUN BEAR *(Helarctos malayanus)* P. C. Kalita, A. Kalita, O. P. Choudhary, and P. J. Doley	230
CBF-28	FOOT AND MOUTH DISEASE SERO-SURVEILLANCE AT BUFFER AREA OF RESERVE FORESTS IN UTTARAKHAND Sagar A Khulape, J K Biswal, Chandrakanta Jana, Manish Kumar, J K Mohapatra, Raj Kumar Singh and Bishnu Prasad Mishra	231
CBF29	A STUDY ON MORTALITY AMONG CAPTIVE GREEN ANACONDAS (*Eunectes Murinus*) Aparna S, Nandakumar S, Swapna Susan Abraham, Prathuish PR, Sobha SS , Jacob Alexander,Kalpana B	231
CBF-30	INCIDENCE OF ELECTROCUTION IN A WILD ASIATIC ELEPHANT (*Elephas maximus*) Somesh Singh, Devendra Podhade, A.B.Shrivastav, Sandip Agrawal and Sriram Guntoju	232
CBF-31	ENTOMOLOGY AND ENTOMOTOXICOLOGY AS A POTENTIAL TOOL IN WILDLIFE FORENSICS. G A Dubey, A G Dubey and C P Sharma	233
CBF-32	VAGINAL CYTOLOGY IN A TIGRESS (*Panthera tigris tigris*) Pawshe M. D., Patil M. S., Gawande A. P., Kolangath S. M., Upadhye S. V., Dhoot V. M., Syed Bilal Ali, Shalini A. S., Patond C.V. and Kate M. R.	234
CBF-33	ROLE OF BLOW FLIES MAGGOTS IN WILDLIFE FORENSICS Kritika Singh and KP Singh	234
CBF-34	CLINICOPATHOLOGY OF HEPATO-RENAL DYSFUNCTION IN A LEOPARD (*Panthera pardus*) M. S. Hedau, M. P. Kaore, M. D. Pawashe, S. Kolangath and N.V. Kurkure	235
CBF-35	SUCCESSFUL POSTHUMOUS EPIDIDYMAL SPERM RETRIEVAL FROM SPOTTED DEER (*Axis axis*) Kolangath S.M., Pawshe M.D., Upadhye S.V., Dhoot V.M., Gawande A.P. and Shalini A.S.	236

SESSION- VI
POSTER SESSION

Code	Title and Author(s)	Page No(s)
POST-1	REPAIR OF A LACERATED WOUND IN AN INDIAN COBRA (*Naja naja)* Ankur Sharma, R.B. Kushwaha, P. Gupta, A. K. Gupta, S. Borkataki and M.S. Bhadwal	237
POST-2	SUCCESSFUL TREATMENT OF ABSCESS DUE TO FRACTURED TOOTH IN INDIAN PYTHON (*Python molurus*) Syed Bilal Ali, Mayur R. Kate ,Shubhangi Warke, S.V. Upadhye and Shreelaxmi Nair	237
POST-3	SUCCESSFUL WOUND MANAGEMENT OF TIGRESS Syed Bilal Ali, M.D. Pawshe, C.V. Patond, M.R. Kate, S.V. Upadhye, V.M. Dhoot and G.R. Bhojne	238
POST-4	ISOLATION AND IDENTIFICATION OF *S.mercescens* FROM MARSH CROCODILE–A CASE REPORT U.M. Tumlam, M.M. Pawade, C.S. Mote, R.V. Jadhav, S.J. Virshette, S.R. Warke, P.P. Mhase and D.M. Muglikar	238
POST-5	CONCURRENT OCCURRENCE OF METASTRONGYLOSIS AND GNATHOSTOMOSIS IN A WILD BOAR (*Sus scrofa*) Devi, S. S., Megha, K. G.,Ajith, J. G., Sairam,R., Shabeeba, P.M.,Divya, C., Sajitha, I.S. and Asha, R.	239
POST-6	PIROPLASMOSIS IN DONKEY *(Equus asinus)* – A CASE REPORT Karthika R, Pooja G Mankani, Bindu Lakshmanan and Devada K.	240
POST-7	MYELOGRAPHY IN C*anis lupus* (INDIAN WOLF) Mayur R. Kate, Syed Bilal Ali, S.V. Upadhye and G.Khante	241
POST-8	SUCCESSFUL REUNION OF LEOPARD CUB WITH HER MOTHER Mayur R. Kate, Syed Bilal Ali, Prabhunath Shukla,K. Hate and V. J. Arora	241
POST-9	SURVEY OF GASTROINTESTINAL PARASITES OF *Boselaphus tragocamelus* (NILGAI) IN THE KARANJA SOHOL WILDLIFE SANCTUARY, INDIA Milind Shirbhate and Amrita Shirbhate	242
POST-10	GROSS MORPHOLOGICAL CHARACTERISTIC OF SKULL IN INDIAN EAGLE OWL (*Bubo bengalensis*) Sridevi P, Rajalakshmi K, Siva Kumar M and Karthikeyan A	243
POST-11	A CASE REPORT: *Metastrongylus elongates* INFECTION IN WILD BOAR, KERALA Pooja G Mankani, Asha Rajagopal, Karthika R and Devada K.	243
POST-12	INTRAMEDULLARY PINNING OF TIBIAL FRACTURE IN AN INDIAN HERON (*Ardeola grayii*) R B Kushwaha, Ankur Sharma, D K Dwivedi and Pankaj Gupta	244
POST-13	SUCCESSFUL CLINICAL MANAGEMENT OF DYSTOCIA IN NANITISNAKE S.S.Pawar and Vende S.S.	245
POST-14	EXTRACTION OF ECTOPIC TOOTH IN AN INCISOR TOOTH IN A MACAQUE MONKEY Sanjay J. Gaikwad	245
POST-15	FRACTURE AND WOUND HEALING IN CIVET CAT Sanjay J. Gaikwad	246
POST-16	SUCCESSFUL MANAGEMENT OF DEHYDRATED PEACOCK Sanjay J. Gaikwad	246
POST-17	RECONSTRUCTION OF FRACTURED PALATE IN A MONGOOSE Sanjay J. Gaikwad	246
POST-18	REMOVAL OF TWO FISH HOOKS FROM THE INDIAN COBRA MOUTH Sanjay J. Gaikwad	247
POST-19	RESCUE OF A MALE MACAQUE MONKEY Sanjay J. Gaikwad	247
POST-20	MANAGEMENT OF EVISCERATION IN A SPARROW CHICK Sanjay J. Gaikwad	248
POST-21	RESCUE OF A FOX FROM THE WELL Sanjay J. Gaikwad	248
POST-22	RESCUE OF A LEOPARD CUB FROM WELL (SURGANA) Sanjay J. Gaikwad	248
POST-23	ANTI-MICROBIAL SUSCEPTIBILITY PATTERNS OF BACTERIAL AGENTS ISOLATED FROM WOUND AND SOFT TISSUE INFECTIONS IN CAPTIVE ELEPHANTS S. Sundareshan, P. Sheela and Vinay. S.	249

POST-24	AVIAN PROSTHETIC LEG - A NEW ERA IN WILD AVIAN CONSERVATION Ushma Patel, Chetan Patond, S. V. Upadhye and S.B.Akhare	250
POST-25	SURGICAL MANAGEMENT OF CLOACAL PROLAPSE IN AN INDIAN FLAPSHELLEDTURTLE *(Lissemys punctate sp.)* Ushma D. Patel, Chetan V. Patond, Yash Bhate and Gautam Bhojne	250
POST-26	OPEN REDUCTION AND INTERNAL FIXATION BY PLATING IN A LEOPARD (*Panthera pardus)* AND A BLACK BUCK (*Antilope cervicapra*) Upadhye, S.V., S.B. Akhare, GauriKhante, V.M. Dhoot, G.R. Bhojne, Tista Joseph and Ushma Patel	251
POST-27	SUCCESSFUL MANAGEMENT OF CROP LACERATION IN INDIAN ROCK PIGEONS (*Columba livia*) – A REPORT OF TWO CASES Ushma Patel, Chetan Patond, Mayank Barde and S. B. Akhare	251
POST-28	SUCCESSFUL TUMOR REMOVAL IN AN INDIAN ROCK PIGEON *(Columba livia)* Ushma Patel, Chetan Patond, Shirish Upadhye and S.B. Akhare	252
POST-29	SURGICAL MANAGAEMENT OF LACERATED WOUND IN A RUSSELL'S VIPER (*Daboia russelii*) Ushma Patel, Aishwarya Betgiri, Shalaka Salvekar and Chetan Patond	253
POST-30	SURGICAL MANAGEMENT OF FEMUR AND TIBIA FRACTURE ALONG WITH HIP JOINT DISLOCATION IN JUNGLE CAT (*Felis chaus*) S.S.Jadhav, S.D.Sequeira and V.Sanghvi	253
POST-31	FEATHER IMPLANTATION IN SHIKRA *(Accipiter badius)* S.S. Jadhav and S. Everett	254
POST-32	SUCCESSFUL TREATMENT OF ORGANOPHOSPHATE POISONING IN A PEAFOWL Sakhare M. P., Siddiqui M.F.M.F., Shafi T.A., Borikar S.T., Sachin G. D.and S. S. Lingayat	255
POST-33	INVESTIGATION ON FOOT AND EYE PROBELMS IN ASIAN ELEPHANTS AT HAATHI GAON, JAIPUR M. Karikalan, N.S. Manoharan, Arvind Mathur, Bhoj Raj Singh, Prajna Panda, Muthamizh Selvan and A.M. Pawde	255
POST-34	COCCIDIOSIS IN PEAFOWL (*Pavocristatus*) Vanishree, Sujay C.S. and Nikita Salian	256
POST-35	THERAPEUTIC MANAGEMENT OF CANINE TRANSMISSIBLE VENEREAL TUMOR IN INDIAN GREY WOLF: A CASE STUDY Ramesh Pandey, Abhijit Bhawal, Vikash Jayswal, Harshita Raghav and Sonu Sharma	257
POST-36	A LARGE-BILLED CROW WITH BEAK DEFORMITY-A SIGHTING RECORD Rushikesh R. Sankpal, Sfurti B. Raut, Sayali R. Sankpal	258
POST-37	Ω-3 FATTY ACIDS SUPPLEMENTATION IMPROVED ANTIOXIDANT STATUS, IMMUNITY AND REDUCED STRESS IN CAPTIVE INDIAN LEOPARD FED BUFFALO MEAT ON BONE DIET S.M. Durge, Asit Das, S.K. Saha, A.K. Verma, Y. Bhardvaj and V.M. Salunke	258

SESSION- I

THEME SESSION

RESCUE OF STRAY AND INJURED LARGE MAMMALS: ELEPHANT, RHINO, BISON ETC.

Prof. Kushal Konwar Sarma
Head of the Department of Surgery & Radiology
College of Veterinary Science, Assam Agricultural University, Khanapara,
Guwahati-781 022, Assam.

The homosapiens is the latest species that have arrived on the earth which is just an infant in the greater time scale of appearances of life forms on this planet; and when they arrived, the earth was already inhabited by millions of different floral and faunal species, large and small. The existence of human on earth is a relentless struggle and continued tussle with these wild species. The human was just another species and he learnt to leave space for all other species and a balance was thus maintained. This delicate balance, however, tilted greatly toward humans during last one thousand years; thanks to their superior intelligence and inventions of tools like arms and weapons. The situation assumed grave proportions after the industrial revolution in Europe, firearms were manufactured and in just three hundred years, the humans have wiped out almost every species from the face of the earth. The day is not far, it seems; if something serious is not done immediately, the human will find itself lonely, all other species gone forever.

So, though belatedly, the man has understood, that it cannot survive as a single species and at least the last remaining bio-diversity has to be maintained only if it has to secure its own existence for the future. In this principle, every individual animal of every individual surviving species has become valuable. Hunting for pleasure and even for food is not acceptable. The International Union for Conservation of Nature (IUCN) has prepared list of the endangered species and asked all the member countries to enact laws for their protection. The Government of India has enacted the Wildlife Protection Act (WPA-1972) to extend the umbrella of protection to these wild species, imposing severe punishment for violation by "killing or causing any harm" to them. Wild animals have been classified in different schedules and offering highest degree of protection to the animals of Schedule-I which means that their status is "highly endangered" and that nobody should cause any direct or indirect harm to them.

Now, like the human being and other domesticated animals, wild animals are also greatly disturbed and destabilized by natural calamities like flood, erosions, draught, earthquake, tsunamis, volcanic eruptions or even wild fire. In such calamities, they stray out to unprotected areas making themselves vulnerable; such stray animals also attract many curious onlookers and casualties are equally likely also on the human side. In the past, we could have ignored these as a natural control mechanism over the populations;

but the same attitude does not hold good today because of the fact that only a very small number of the species are left in nature. So every individual animal is precious today and necessitates collective will and expertise to save them. It must be borne in mind that there are several species of wild animals with variable size, habits and temperament. Large-small, aquatic-arborial-terrestrial, diurnal-nocturnal, carnivore-herbivore-omnivore; there are scores of variations. Their anatomy and physiologies vary greatly, responses to immobilizing or other drugs are amazingly variable. Quite naturally, the animal will not discriminate the rescuer from an attacker and try to attack back with a view on self-defense. So a great deal of expertise is required to be able to handle them safely to restore their wild status. Stray herds often come to human settlement areas and unwillingly abandon their young ones if they are trapped in quagmires or trenches.

Physical versus chemical restraint: The stray animal is required to be restrained safely without causing any unnecessary stress and if it is free from any injury or infection, should be released without any delay. There are many traditional tricks which can be used to physically trap a wild animal like reptiles and birds etc. some small mammals like small felines, jackals, ant-eaters, hog-badgers, porcupines, pangolins, hispid hare and even monkeys can be trapped in well designed and well placed trap cages. The trapped animal can later be mildly sedated to avoid the psychological stress of entrapment till they are released. The higher mammals, however, react violently to the physical restraint and thus suffer severe physical and mental trauma. In the physical capture, these animals besides causing self inflicted physical injuries have higher vulnerability to "capture myopathy" characterized by anaerobic metabolism of muscle glycogen leading to accumulation of lactic acid, which can kill the animal in a day or even after a month. The experts, therefore, prefer to use chemical restraint which has been proven to be much efficient and safe with the advent of immobilizing drugs with higher margin of safety together with availability of reversal agents.

For chemical capture, you need an assortment of immobilizing and sedative drugs and a variety of delivery systems popularly known as "tranquillizing guns or syringe projectors". No single drug is capable of immobilizing all the species of animals; interestingly a drug very efficient in one species may not be at all useful in another species. For example, opiates are the drugs of choice for immobilizing rhinoceros and the elephants but the same group of drugs is contraindicated in the felines as they will cause only maniacal excitement. The choice of syringe projector is also similarly dictated by the thickness of the skin of the target animal and the type of drug to be used. Typically, a dart propulsion system that projects a metal dart is preferred in thick skinned animals like elephants, rhinoceros, wild buffaloes bisons as against a pneumatic propulsion system with a plastic dart used in thin skinned animal like felines, antelopes etc.

Legal authorization of the operation is mandatory, but never a cause of concern for the vet team since we proceed for such operations only on request of the wildlife authority and not on our own. Providing all necessary facilities like transport, accommodation, tranquilizing and rescue facilities are also their responsibilities. The local Divisional Forest officer should take telephonic or electronic permission from the Chief Wildlife Warden of the state on an emergency and then the DFO should write a letter requesting the vet for undertaking the operation. You should however, take permission from your controlling officer for your own movement.

Several factors dictate the choice of immobilizing drug or drug combinations and also the choice of darting platform. Species of the animal, purpose of immobilization, physical status of the animal and topography of the area are some of the immediate factors that we consider in selection of the drug. However, we have very little choices on the immobilizing drugs; either the narcotics (etorphine and/or its combinations) or the alpha agonists like xylazine, medetomidine with cyclohexamines along with their reversal agents. These drugs are not available in open markets and to be procured by the wildlife departments or institutions. You may have to face the pressure to pick up from few non preferential drugs and also with dates of uses expired already. Given a choice, choose a narcotic (etorphine/carfentanyl/thiafentany) when the animal is to be immobilized in a relatively open flat ground and an alpha agonist in combination with a cyclohexamine in a riverine or hilly territory. Be careful about the expiry date of the drug. In open savannah like Africa a chopper may be the best approach, but in India we prefer a well trained captive elephant, climbing a tree or any other darting platform can be chosen as per the situation, but the safety aspect should never be compromised. One must not ignore the fact that no drug administered with a projectile can save the sniper from a charging elephant, rhino or bison or any wild animal.

Elephants are the most frequently straying out animal that may enter deep into human dominated landscape. Generally they have the homing instinct and can return to their habitat, but sometime they lose direction due to disturbances and obstruction caused by people. So first attempt should be to clear their passage and immobilization and physical removal comes only as a second choice. For physical lifting, the elephant must be immobilized in a hard and motorable place. We found it easy to load an elephant into a truck or trolley in standing position, so choice of Xylazine/Medetomedine with Ketamine comes in handy. First, the limbs of the immobilized animal are tied with jute ropes and all four legs are to be fitted with robust jute ropes separately for anchoring into the side bumpers of the carrier. Now for lifting and loading into the trolley, you need a Hydra lift with at least two hooks placed 1.5meter apart with its telescopic action of the distal arm.

Four sets of cargo belts (5 ton capacity each) are now passed under the axila and groin independently to pass under the arm pit and inner thighs and bunched up at the top to fix

to the hooks of the Hydra arm. The belts used on the rear side should be somewhat (1 meter) shorter than used for the front to maintain a similar height level of the animal when lifted for loading. In this way, we can avoid placing a belt under the belly or chest of the elephant. Now the animal is lifted high on air and the lorry already placed in front of the animal moves in reverse direction to come under the animal and then the animal is gently lowered to place it on the trolley. Now the belts are removed from the hooks but kept with the animal for ease of unloading at the destination. The vehicle should be driven at a low (40-50km/hr) speed and any sudden braking avoided. You will have to sedate the animal again for unloading at the destination site. No fodder should be provided en-route if the journey is under 24 hours, but drinking water should be provided time to time.

Wild buffaloes are very dangerous animals, their strength and ferocity belies their gentle look. Males weigh upto 800-1000kg. Reliable drugs in this group are the opioids/narcotic groups. Etorphine @0.005-0.050mg/kg; carfentanyl @ 0.005-0.015 mg/kg and thiafentanyl 0.007-0.018 mg/kg. Thiafentany gives the shortest induction (2-3min) followed by carfentanyl (6-7min) and etorphine- 10-12 mins. Xylazine @ 0.5-1.0mg/kg and ketamine at 1:1 ratio with xylazine is commonly used in India because of lack of other suitable agents particularly narcotics. Combination is not reliable, may cause abortion in pregnant animals in higher dose and has a long induction period of about 25-30 minutes.

Overall, important points to remember while anaesthetizing wild ruminants can be summarized as follows:

1. Wild animals have legal protection under Wildlife Protection act of India 1972; any casualty or accident involving the animal might invite trouble, therefore legal authorization in writing (Chief Wildlife Warden of the state or his authorized person) must be obtained before undertaking the operation.
2. They are sensitive to most of the anaesthetic agents and there is tremendous species variation in the response to an anesthetic drug by different species.
3. Long chase and excitement before darting must be avoided. This may lead to capture myopathy.
4. Fasting for 24 hours and withdrawal of water for at least 6 hours is advisable in captive conditions.
5. Vitamin – E and Selenium should be administered immediately to prevent myopathy.

6. They suffer from hyperthermia, tympany, regurgitation and often fatal pneumonia, required to be careful
7. Positioning of the animal during recumbency is important. Generally sternal or right lateral recumbency are considered to be safe.
8. Animal should be saved from running into water after darting. Preparations should be made beforehand to save the animal from drowning.
9. Monitoring and resuscitation equipments, endotracheal tube, laryngoscope, oxygen etc should be available.
10. Reversal drugs, antihistamins, Vit-E, Selenium, corticosteroid etc should be ready.

For rhino immobilization and translocation, there are no alternative drugs available other than the narcotics. For Asian rhino a dose rate of 1mg/400kg body weight was found ideal, in adjunct with Acepromazine 20mg. Young hand reared and zoo rhinos may be handled with sedation produced with Medetomidine and ketamine. For wild to wild rhino translocation, the following are required,:

1. Sledge
2. Wooden Crate for holding the rhino
3. Heavy duty tractor
4. JCB/earth mover
5. Motorized Crane
6. Truck
7. Two koonkie elephants
8. Partially inflated Truck tubes
9. Towing belt

When injured animals are captured for treatment and release, we should avoid the sedatives and use only narcotics, the action of which will be reversed after the job is over. Sedative like ACP may keep it sedated for long and make the animal an easy prey of predators. A standing sedation is preferable in an elephant in riverine or hilly areas and also when an injury requires treatment, as it is extremely difficult to turn the animal over to the other side if the side of injury falls underneath. We should always use a long acting and broad spectrum antibiotic in cases of injuries and infections in wild animals, that will not be kept in a boma following treatment. Tetanus prophylaxis also should be remembered.

INDIA'S ENDANGERED MAMMALIA

B. M. Arora[1] and Bipul Chakrabarty[2]

India, a mega-diverse country with only 2.4% of the world's land area, accounts for 7-8% of all recorded species, including over 45,000 species of plants and 91,000 species of animals. The country's diverse physical features and climatic conditions have resulted in a variety of ecosystems such as forests, wetlands, grasslands, desert, coastal and marine ecosystems which harbour and sustain high biodiversity and contribute to human well-being. Four of 34 globally identified biodiversity hotspots: The Himalayas, the Western Ghats, the North-East, and the Nicobar Islands, can be found in India.

India is home to different types of animals, birds and fishes which include some important farm animals like goats, poultry, cows, buffaloes, pigs etc. The country is also a habitat for wild animals like Bengal tigers, deer, wolves, pythons, Indian lions, bears, snakes, monkeys, many types of bison, Asian elephants and antelope species. India is one of the mega diverse countries out of a total of seventeen mega diverse countries in the world. These seventeen mega diverse countries, including India, are the habitats of around 60 – 70% of the world's biodiversity. The Western Ghats, The Eastern Himalayas and Indo–Burma are the three biodiversity hotspots out of total 34 in the whole world.

India has 6.5% of the world's total wildlife species according to a report which was published by the United Nations Office on Drugs and Crime (UNODC) that includes 7.6% of all mammals and 12.6% of all bird species. According a report issued by the International Union for Conservation of Nature (IUCN) Red List in 2014, 15 species of birds, 12 species of mammals, and 18 species of reptiles and amphibians have joined the critically endangered list.

Reasons for Endangerment:

1. Loss of habitat is one of the primary reasons for the endangerment of species.

2. Poaching has a very destructive and catastrophic effect on the number of animals and fishes all over the world.

[1]President, Association of Indian Zoo and Wildlife Veterinarians. Former Principal Scientist, *Centre* for *Wildlife* Conservation Management & Disease Surveillance, IVRI, Bareilly(U.P) & Director, National Zoological Park, new Delhi

[2] Director, Tata Steel Zoological Park, Jamshedpur (Jharkhand) and Former, Joint Secretary, Indian Zoo Directors Association, New Delhi

3. Weather and climatic advisories in a robust and hearty environment there is always an accurate balance to keep population healthy.
4. To save the endangered herbivore mammalian species such as musk deer, sangai deer, Chousingha, pigmy hog, rhinoceros, and carnivore mammalian species such as tiger, Asiatic lion, Snow leopard, clouded leopard, Malayan sun bear, red panda are deadly threatened for poaching. To keep their population regulation harmonious first foremost task is to protect their habitats and connected range areas. The limitation of the habitats has many adverse such as inbreeding, nutritional adequacy, and safe shelters. Thus natural topography of the habitat land scape is changed.

Steps Taken by the Government for Wild Life Protection:

• All the states adopted Wildlife (Protection) Act which prohibits any type of trade for endangered and rare species.
• The Central Government provides every type of financial assistance to the State Governments for the conservation and protection of the endangered species.
• National ban was imposed on tiger hunting in 1970 and Wildlife Protection Act became effective in 1972. According to the latest tiger census (2015), there is an overall increase of 30% in tiger population. In 2010, there were 1700 tigers left in India according to tiger census which has gone up to 2226 tigers in 2015.
• Innumerable numbers of National Parks, Wildlife Sanctuaries, Parks etc have been established by the government.
• In 1992, Central Zoo Authority (CZA) was initiated for the supervision of the management of zoological parks in the country.
• In 1996, the Wildlife Advisory Committee and Wildlife Institute were established for seeking advice on different features of Wildlife conservation and matters related to it. There are several other initiatives which have been taken up by the government to save the endangered species of India.

India is part of five main International Conventions which are associated to wildlife conservation. They are (i) Convention on International Trade in Endangered Species (CITES), (ii) Coalition Against Wildlife Trafficking (CAWT), (iii) International Whaling Commission (IWC), (iv) United Nations Educational, Scientific and Cultural Organization – World Heritage Committee (UNESCO – WHC) and (v) the Convention on Migratory Species (CHS).

Numerous positive steps are being taken for saving the endangered species of India. But that is not enough. There is a dire need for more NGOs and the private corporate sectors to come forward for this noble cause.

INDIAN ENDANGERED MAMMALS (IUCN RED LIST Classification)

	IWPA[3] Status & IUCN[4]Category	Information / Conservation Measures
Herbivores		
Great Indian one horn Rhinoceros (*Rhinoceros unicornis*)	Schedule-I/Part-I(30) Endangered	Habitat: Found only in the tall grasslands and forests in the foothills of the Himalayas (Terai region). National Parks: Kaziranga National Park, Pabitora wildlife sanctuary, Manas National Park, Assam. Status in the Wild: Moved from Endangered to Vulnerable. Threat: Poached for its horn (in SE Asian countries it is a belief that its horn has medicinal properties), Habitat loss& fragmentation.
Wild water buffalo (*Bubalus arnee*)	Schedule-I/Part1(41) Endangered (IUCN May, 2016)	
Takin(*Budorcas taxicolor*)	Schedule-I/Part-I(36)	Distribution: Mountainous regions in the Himalayan Mountains and western China. Threats: Largely due to overhunting and the destruction of their natural habitat, takin are considered Endangered in China and Vulnerable as per the IUCN.
Hispid hare(*Caprolagus hispidus*)	Schedule-I/Part-I(11) Endangered (IUCN June,2018)	Habitat: Southern foothills of the central Himalayas. Threats: The habitat of hispid hares is highly fragmented due to increasing agriculture, flood control, and human development.
Asian Elephant(*Elephas maximus indicus*)	Schedule-I/Part-I(12-B) Endangered June, 2008	Since 1986, the Asian elephant has been listed as Endangered on the IUCN Red List as the wild population has declined by at least 50% since the 1930s to 1940s, i.e. three elephant generations. The Asian elephant is threatened by habitat loss, degradation and fragmentation.
Himalayan musk deer(*Moschus leucogaster*)	Schedule-I/Part-I(25) Endangered (November,2014	Habitat: Kashmir, Kumaon and Sikkim. Threat: poaching & illegal trade for its musk. Only males produce the musk.
NilgiriTahr (*Nilgiri tragus hylocrius*)	Schedule-I/Part-I(25-B) Endangered June,2008	The Nilgiritahr is the largest of the three tahr species, inhabit montane grasslands of Western Ghats. It is the state animal of Tamil Nadu. Threats: Habitat loss, overgrazing, illegal hunting.

[3] IWPA-Indian Wildlife (Protection)Act,1972 as amended till 2013
[4] IUCN-International Union for Conservation of Nature

Sangai -Thamin Deer (*Rucervuseldii eldii*)	Schedule-I/Part-I(3) Endangered (May,2014)	Distribution: Keibul Lamjao National Park (KLNP), Manipur. Threats: Overgrazing, loss of grassland habitat.
Hangul- Kashmir Stag(*Cervuse laphus hangul*)	Schedule-I/Part-I(16) Endangered	It is a subspecies of Red Deer which is native to India. Habitat: Dense riverine forests, high valleys, and mountains of the Kashmir valley and northern Chamba in Himachal Pradesh. State animal of Jammu and Kashmir. Threat:habitat destruction, over-grazing by domestic livestock,and poaching.

Common and Scientific Name of the species	IWPA[3] Status & IUCN[4]Category	Information / Conservation Measures
Indian Wild Ass(*Equus hemionuskhur*)	Schedule-I/Part-I(14)	Showed an increase in population. Moved from Endangered (2015) to Near Threatened (2019). Distribution: Mostly occurs in Rann of Kutch region. Population steadily increasing. Today, its last refuge lies in the Indian Wild Ass Sanctuary, Little Rann of Kutch. Threats: Diseases, habitat degradation due to salt activities, Invasive species Prosopis juliflora shrub, and encroachment and grazing by the Maldhari.
Pygmy Hog(*Porcula salvania*)	Schedule-I/Part-I(29)	Is the world's smallest wild pig. This species constructs a nest throughout the year. It is one of the most useful indicators of the management status of grassland habitats. The grasslands where the pygmy hog resides are crucial for the survival of other threatened species such as Indian Rhinoceros, Swamp Deer, Wild Buffalo, Hispid Hare, Bengal Florican and Swamp Francolin. Habitat: Relatively undisturbed, tall terai grasslands. Distribution: Previously spread across India, Nepal, and Bhutan. Now only found in Assam (Manas Wildlife Sanctuary and its buffer reserves). Pygmy hog-sucking Louse (*Haematopinus oliveri*), a parasite that feeds only on Pygmy Hogs will also fall in the same risk category of critically endangered as its survival is linked to that of the host species. Threats: The main threats are loss and degradation of grasslands, dry-season burning, livestock grazing and afforestation of grasslands. Hunting is also a threat.
Red panda (*Ailurus fulgens)*	Schedule-I/Part-I(18) Endangered(April, 2015)	Red panda is endemic to the temperate forests of the Himalayas. Habitat: Sikkim and Assam, northern Arunachal Pradesh. Threats: habitat loss and fragmentation, poaching, and inbreeding depression.

Common and Scientific Name of the species	IWPA[3] Status & IUCN[4]Category	Information / Conservation Measures
Carnivores		
Dhole /Wild Dog *Cuon alpines*	Schedule-II/Part-I(22) Endangered(May,2015)	Distribution: They occur in most of India south of the Ganges, particularly in the Central Indian Highlands and the Western and Eastern Ghats of the southern states. In north-east India, they inhabit Arunachal Pradesh, Assam, Meghalaya, and West Bengal. Threats: Habitat loss, depletion of its prey base, competition from other predators, persecution and possibly diseases from domestic and feral dogs.
Asiatic (Indian) lion(*Panthera leo persica*)	Schedule-I/Part-I(13) Endangered (June,2008)	Habitat: Gir forests in Gujarat Threats: Habitat destruction, Diseases spreading from domestic animals.
Bengal tiger (*Panthera tigris tigris*)	Schedule-I/Part-I(39) Endangered(February, 2010)	2015: International Union for Conversation of Nature (IUCN), said that tiger numbers have grown to 3,890—a marked increase from estimates in 2010 that put the number at "as few as 3,200." The general observation is that the population of tigers in India has increased while that of the rest of the world has decreased.
Himalayan Brown Bear(*Ursusarctos isabellinus*)	Schedule-I/Part-I(3-A)	Distribution: Nepal, Tibet, north India, and north Pakistan. Threats: loss of suitable habitat and persecution by humans.
Malabar Civet (*Viverra civettina*)	Schedule-I/Part-I(22)	It is endemic to India and was first reported from Travancore, Kerala. It is nocturnal in nature and found exclusively in the Western Ghats. Habitat: Wooded plains and hill slopes of evergreen rainforests. Habitat/distribution: Western Ghats. Threats: Deforestation and commercial plantations are major threats.
Clouded leopard (*Neofelis nebulosi*)	Schedule-I/Part-I(6)	Habitat: Himalayan foothills through mainland Southeast Asia into China. They occur in northern West Bengal, Sikkim, Arunachal Pradesh, Manipur, Meghalaya, Mizoram, Nagaland and Tripura. Threat: deforestation and poaching.
Common and Scientific Name of the species	IWPA[3] Status & IUCN[4]Category	Information / Conservation Measures
Primates		
Lesser Hill langur (*Semnopithecus hector*)	Schedule-II/Part-I(4-A) Near Threatened	The Terai gray langur was formerly considered a subspecies of the northern plains gray langur. The species is listed as Near Threatened, as there are probably not many more than 10,000 mature individuals, and it is experiencing a continuing decline.
Western Himalayan (Kashmir) Gray	Schedule-II/Part-I(4-A) Endangered	The Kashmir gray langur has been reported from Jammu & Kashmir and Himachal Pradesh in northwestern India but evidence indicates it only occurs in the ChambaVallley in Himachal

Langur (*Semnopithecus ajax*)		Pradesh. Because of its restricted range, fragmented population and threats from human agriculture and development activities it is listed as 'Endangered' in the IUCN Red List. In Pakistan it occurs in Machiara National Park. It was formerly considered a subspecies of *Semnopithecus entellus* and is one of several *Semnopithecus* species named after characters from 'Thelliad', along with *Semnopithecus hector* and *Semnopithecuspriam.*
Lion tailed macaque(*Macaca Silenus*)	Schedule-I/Part-I(19) Endangered (November,2015)	Species is present in the following protected area(s): Karnataka: Brahmagiri WLS, Kudremukh NP, Mookambika WLS, Pushpagiri WLS, Sharavathi Valley WLS, Someshwara WLS, Talakaveri WLS; Kerala: Aralam WLS, Chimmony WLS, Neyyar WLS, Peppara WLS, Parambikulam WLS, Periyar NP, Periyar WLS, Shendurney WLS, Silent Valley NP; Tamil Nadu: Indira Gandhi WLS, Kalakkad WLS, Mundanthurai WLS, Grizzled Giant Squirrel WLS Endemic to the Western Ghats. Avoids human presence and they do not live, feed or travel through plantations. Habitat: Evergreen forests in the Western Ghats range. Threat: Habitat fragmentation due to spread of agriculture and tea, coffee, teak and cinchona, construction of water reservoirs and human settlements to support such activities.
Common and Scientific Name of the species	IWPA[3] Status & IUCN[4]Category	Information / Conservation Measures
Gee's golden langur(*Trachypithecus geei*)	Schedule-I/Part-I(10) Endangered(June,2008)	Species is present in the following protected area(s): Assam: Chakrasila WLS, Manas NP Primate, is an Old World monkey Distribution: small region of western Assam and in the neighbouring foothills of the Black Mountains of Bhutan. Threats: Deforestation, human encroachments.
Phayre's Leaf Monkey (*Trachypithecus obscurus phayrei*)	Schedule-I/Part-I(16-A) Endangered	Species is present in the following protected area(s): Mizoram: Dampa WLS / Tripura: Gumti WLS, Sepahijala WLS, Trishna WLS.
Capped langur (*Trachypithecus pileatus tenebricus*)	Schedule-I/Part-I(3-B) Endangered	In India, the capped langur (*Trachypithecus pileatus*) occurs in Assam, Arunachal Pradesh, Manipur, Meghalaya, Mizoram, Nagaland, and Tripura. Elsewhere it is found in Bhutan, Bangladesh, northwestern Myanmar and a small area of Tibet, China. It is a forest-dwelling primate occurring in lowland, wet, evergreen rain forest to temperate forest. It ranges from the plains, 5 m above sea level, to 2,800 m in the Himalaya. It has been recorded in 53 protected areas in Northeast India. Of five subspecies recognized in the past (pileatus, durga, brahma, shortridgei and tenebricus) Trachypithecus p. pileatus occurs south of the Brahmaputra River; T. p. brahma and T. p. tenebricus occur north of the river. The subspecies brahma and tenebricus, both

		found north of the Brahmaputra, have features in common, but which differ from the langurs south of the Brahmaputra. The Jia-Bhoroli (known as Kameng in Arunachal Pradesh) also presents an impassible barrier separating the two subspecies to the north of the river. The primary difference seems to lie in the pattern of the cap of brahma and also some differences in pelage, which still separate them from tenebricus.
Ant eaters		
Chinese Pangolin (*Manis pentadactyla*)	Schedule-I/Part-I(5-A) Critically Endangered	The Chinese pangolin (*Manis pentadactyla*) is a pangolin native to the northernIndian Subcontinent, northern parts of Southeast Asia and southern China. It has been listed as Critically Endangered on the IUCN Red List since 2014, as the wild population is estimated to have declined by more than 80% in three pangolin generations, equal to 21 years. It is threatened by poaching for the illegal wildlife trade.
Rodents & Bats		
Namdapha Flying Squirrel(*Biswamoyopterus biswasi*)	Schedule-II/Part-II(1-C) Critical	It is a unique (the only one in its genus) flying squirrel that is restricted to a single valley in the Namdapha N.P.(or) W.L.S. in Arunachal Pradesh. Habitat: Tropical forest. Habitat/distribution: Found only in Namdapha Tiger Reserve in Arunachal Pradesh. Threats: Hunted for food.
Woolly Flying Squirrel (*Eupetaurus cinereus*)	Schedule-II/Part-II(1-C) Endangered	The woolly flying squirrel (*Eupetaurus cinereus*) is the sole species currently placed in the genus *Eupetaurus*. Until recently scientific knowledge of this rare species was limited to 11 skins collected in the late nineteenth century. However, recent research has confirmed that it remains in Kashmir. It is among the longest members of the family Sciuridae and one of the biggest gliding animal known, but observations confirm that despite its size, it does glide effectively like other flying squirrels.
Nilgiri-striped Squirrel (*Funambulus sublineatus*)	Schedule-II/Part-II(1-C) Endangered	The Nilgiri striped squirrel (*Funambulus sublineatus*) is a threatened species of rodent, a small squirrel (*Sciuridae*) from rainforests in the southern Western Ghats, including the Nilgiris. It formerly included *Funambulus obscurus* from Sri Lanka as a subspecies, at which point the English name of the "combined species" also was dusky striped squirrel (a name now restricted to the Sri Lankan species).

Grizzled Giant Squirrel (*Ratufa macroura*)	Schedule-II/Part-II(1-D) Endangered	R. macroura is the smallest of the giant squirrels found in the Indian subcontinent, with a head and body length of 25 to 45 cm (10–18 in), and tail measuring roughly the same or more, for a total length of 50 to 90 cm (20–35 in). It has small rounded ears with pointed tufts. The home range of an individual is between 1,970 and 6,110 m2 (21,200–65,800 sq ft). In India, R. macroura has been recorded from Grizzled Squirrel Wildlife Sanctuary, Theni Forest Division, Palni Hills, Chinnar Wildlife Sanctuary, Anaimalai Tiger reserve, Sirumalai, Thiruvannamalai Forest Division of the Eastern Ghats, Hosur Forest Division and Cauvery Wildlife Sanctuary. The easternmost population of Ratufa macroura dandolena was discovered in the Pakkamalai Reserve Forest in eastern Tamil Nadu. Grizzled Squirrel Wildlife Sanctuary is located in Shenbagathoppu, Srivilliputtur, Tamil Nadu, India.
Kolar leaf nosed bat (*Hipposideros hypophyllus*)	Schedule-V	Hipposideros hypophyllus Kock& Bhat, 1994 belongs to the bicolor species group of the family Hipposideridae Gray, 1813 represented by 13 species in South Asia (Srinivasulu & Srinivasulu 2012). This taxon is unique among the bicolor species group in possessing a single pair of supplementary leaflets. From Hanumanhalli, the type locality, and Therahalli, situated about 19km west of Hanumanhalli, 41 individuals and eight individuals respectively of hipposiderids of unknown identity were collected as a part of serological studies designed to investigate the role of bats in Japanese encephalitis virus transmission in the years 1983 and 1985. These were misidentified as *Hipposidero spomona* based on similarities in skull morphology (Banerjee et al. 1988; Bhat & Jacob 1990; Sreepada et al. 1993). The specimens were later re-examined and described as *Hipposideros hypophyllus* by D. Kock & H.R. Bhat in 1994. After these initial collections this species was not sighted or collected for further details). Hence, based on the assumption that this species is restricted to <500km2 and known from only two locations, this species was listed as 'Endangered' in the IUCN Red List of Threatened Species (Molur & Srinivasulu 2008)

REFERENCES:

1. The Indian Wild Life(Protection) Act,1972 as amended till December, 2013
2. The IUCN Red List of Threatened Species. Version 2020-2.
3. Kock, D. & H.R. Bhat (1994). *Hipposideroshypophyllus* n. sp. of the *H. bicolor*-group from peninsular India. *Senckenbergiana* 73(1–2): 25–31.
4. Molur, S. & C. Srinivasulu (2008). *Hipposideroshypophyllus*. The IUCN Red List of Threatened Species. Version 2014.2.
5. Wikipedia, the free encyclopedia-2020

SESSION-II
CONFLICT, RESCUE
&
REHABILITATION

CRR-LP 1

RHINO POPULATION THREATS AND ORPHANS RESCUE AND REHABILITATION INFORMATION AND EXPERIENCE BASED ON WHITE RHINOS (*Ceratotherium simum)* AND BLACK RHINOS *(Diceros bicornis)*

Fabiola Quesada Fernandez
DVM MD
CEO Wild Spirit Pty (Wildlife veterinary & conservation courses in South Africa)
President, Wild Spirit Fund
vet.wildspirit@gmail.com

Rhinoceros are some of the most iconic mammals on earth and yet one of the threatened. Historical and present threats are bringing these magnificent creatures to the brink of extinction both in Africa and Asia. Together with law enforcement in rhino conservation, veterinary work is an essential tool saving both a single animal and full populations. Despite the challenges and lack of infrastructure and equipment, it is still the veterinarian's responsibility be updated in world rhino medicine latest knowledge and gain experience to reach the confidence required to save this species.

To the increasing poaching incidents in South Africa in the last 10 years, has followed the successful rescue and rehabilitation of many orphaned rhinos, bringing now knowledge that can be useful to other rhinos species.

This is a complex and high energy-consuming process, both physical and mental that required the full commitment of handlers and veterinarians. From the medical point of view, we can structure the knowledge and work in the following sections:

1) Rescue (Capture and Translocation): Anaesthetic drugs combination, physio-pharmacology, anaesthesia management.

2) First Health care: Based on animal health and potential injured This process must be done efficiently and minimizing any additional stress to the already compromised calf.

3) Bottled feeding and fibre intake: Milk formulas, and grass types.

4) Routine and hygiene.

5) Preventing and handling secondary health problems: Eye ulcers and gastrointestinal pathologies.

6) Reintroduction procedure and challenges.

CRR-LP 2

CONTRACEPTION PROGRAMMES FOR THE CONTROL OF WILD PIGS AND MACAQUES IN HONG KONG, TECHNIQUES, RATIONALE AND RESULTS

Paolo Martelli[1] DVM, CertZooMed, Dip. AACM; Karthiyani Krishnasamy[2]DVM, MRCVS; Amy Kwan[2] and Alex Wong[2]

[1]Veterinary Department, Ocean park Corporation, Hong Kong SAR

[2]Ocean Park Conservation Foundation Hong Kong, SAR

paolo.martelli@oceanpark.com.hk

Dense human populations being in close vicinity to natural terrains that are home to rich biodiversity inherently leads to a high degree of human-wildlife interface. Different paradigms exist in response to negative events at this interface also known as human-wildlife conflicts. Hong Kong laws makes provisions for native wildlife and the generally wildlife-friendly predisposition of the Agriculture, Fisheries and Conservation Department (AFCD) protects it further. To address public complaints and to manage wildlife-human conflict a multipronged approach is required; this will be explained so as to place the role of contraception in its rightful context, to determine expectations and to evaluate results.

Fertility control of the macaque population in the territory started in 1999 and has been implemented on a large scale since 2009 in a joint effort by the AFCD and Ocean Park Conservation Foundation Hong Kong (OPCFHK). This macaque contraception programme is an excellent example of humane and rational management of a relatively small number of non-human primates in an environment dominated by a large number of human primates. We present a synopsis of the last 10 years of macaque contraceptive programme in Hong Kong.

Rapid reproductive rate, lack of natural predators and a versatile but generally discreet natural behavior combined with the copious ill-advised feeding by members of the public allowed wild pigs to overpopulate the Hong Kong territory. In recent years, the frequency of wild pig sightings and of undesirable or dangerous encounters in urban areas is on the rise. As hunting by firearms was phased out, new methods are being developed since 2017 to manage wild pig populations in the territory. We will outline the challenges faced by AFCD and OPCFHK for developing a contraception programme for wild pigs in Hong Kong.

CRR-LP 3

INTEGRATING WILD ANIMAL CAPTURE TECHNIQUES IN WILDLIFE MANAGEMENT AND RESEARCH

Parag Nigam* and Pradeep K Malik**
*Head, Department of Wildlife Health Management
Wildlife Institute of India, Post Box # 18, Chandrabani,
Dehra Dun – 248 001, Uttaranchal
nigamp@wii.gov.in
**Sr. Professor Emeritus
Department of Wildlife Health Management
Wildlife Institute of India, Post Box # 18, Chandrabani,
Dehra Dun – 248 001, Uttaranchal
malikpk@wii.gov.in

Wild animal capture techniques have become effective and considerably safe over the years and are increasingly being used in both wildlife management and research. These techniques have gained wider acceptance due to development of precisely adapted, species-specific procedures that expose the animal to minimal stress and ensures optimal welfare.

Animal capture techniques, particularly in the case of free-ranging species are widely used to manage conflict resolution, augment declining and locally overabundant populations through relocation/ translocation, manage wild animals in distress or those displaced into human dominated landscapes and require rescue and subsequent rehabilitation. Further, interventions under captive environments involving health assessment, veterinary treatment, individual marking, biological sampling for health or reproductive assessment and disease surveillance greatly rely on efficient animal restraint techniques. The techniques are also an integral part of ecological research that involve the deployment of tracking devices or collection of biological samples that form the basis for subsequent research on wildlife health, animal physiology, genetics, toxicology and forensics.

While a variety of capture techniques that include both physical and chemical are available, the choice of technique is essentially based on a understanding of the species biology and behaviour, animal's reaction to stress, clarity on the objectives of capture, procedural risk, knowledge of restraint procedures, possible emergencies during these capture events and the skills and experience of the team. Effective capture also requires a thorough knowledge of the topography of the capture site; prevailing environmental conditions; functional capture equipment, immobilizing drugs and rehabilitation essentials.

Each capture effort is fraught with considerable risk to the animal as well as the handler. Inappropriate techniques may lead to major and possibly fatal physiological disturbances in animals. It is therefore imperative to ensure that the procedures are minimally stressful and safe for animal as well as the handler. The information so collated can form the basis for proper planning of capture event to ensure safe and predictable capture culminating in desirable outcomes.

The talk focuses on capture techniques relevant to major native taxa with a focus on available choices and scientific justifications of these approaches. Essential concerns during capture events, possible emergencies and their management are briefly discussed. In addition, focus will also be given to the essential concerns during capture events, possible emergencies and their management during these operations through appropriate examples.

Abstracts

CRR-1

AN OVERVIEW OF RESCUE AND REHABILITATION FOR FREE-RANGING ANIMALS PERFORMED BY THE WILD ANIMAL MEDICAL CENTER OFRAKUNOGAKUEN UNIVERSITY SINCE 2004- ITS EDUCATIONAL ACTIVITIES FOR VET STUDENTS

Prof. Mitsuhiko Asakawa
DVM, MSc Wild Animal Health (UK), PhD, Dipl. JCZWM
Wild Animal Medical Center (WAMC)/ School of Veterinary Medicine,
RakunoGakuen University, Hokkaido, Japan
askam@rakuno.ac.jp

In 2004, the Wild Animal Medical Center (WAMC) was established at Rakuno Gakuen University (RGU), Hokkaido, Japan, not only to study/educate parasitology mentioned above vobe, but also to performe conservation medicine including zoo and wildlife medicine, medical zoology, pathobiology, forensic veterinary medicine etc. Among these activities, the rescue and rehabilitation for free-ranging animals have been performed by the WAMC as well. In this presentation, patient records were summarized from 2004 to 2020 to evaluate the activities. In total, over 100 birds and 20 mammals were brought into the WAMC including a Peregrine falcon (*Falco peregrines*) and an Ussuri tube-nosed bat (*Murinaussuriensis*) which are in the Red Data Book issued by the Ministry of the Environment of Japan. The median of annual number of the patients was about ten individuals. Most cases were caused artificially, for example, collisions with buildings, traffic accidents and so on. Almost ca. 25% of a total of birds could be released. The care and rehabilitation have been performed by over 70 undergraduate veterinary students of WAMC and many other students including vet nurse ones of RGU. Because mostly common avian species (non-endangered species) were cared for at WAMC, there were no significant effects on the ultimate goal of conservation of natural ecosystem or a direct improvement for ecosystem management, but the program had a positive educational effect. For example, the injured Peregrine falcon was used for lectures to primary and high school students.

CRR-2

REHABILITATION OF CONFISCATED INDIAN STAR TORTOISES *Geocheloneelegaus* IN SATHIYAMANGALAM TIGER RESERVES (STR),TAMILNADU

A. Manimozhi*, K. Sridhar**, & Boon Alwin**& M. Sekar*.
*Biologists, Arignar Anna Zoological Park(AAZP),Vandaur, Chennai
** Veterinarians, Arignar Anna Zoological Park(AAZP),Vandaur, Chennai
manimozhi_64@yahoo.co.in

The Indian Star Tortoise, (*Geocheloneelegaus*) is found in dry deciduous and scrub thorn forest habitats of India, Sri Lanka and Pakistan (Smith 1963, Daniel 1992, Das 1995). This species is one of the many illegally traded wild animals from India and is smuggled to different countries, especially South East Asian nations, where it is used as pets or for human consumption or in preparation of traditional medicines. An illegal consignment of 1073 live star tortoise of different ages of star tortoises (few months to one year old) was confiscated at Chennai Airport by DRI department and transferred to Arignar Anna Zoological Park for rehabilitation on September 2017 in three consignments. These animals were housed in the quarantine area of AAZP adjacent to the Veterinary Hospital. The enclosure was chain linked in all sides including tops. Part of top is covered with shade net. The enclosure enrichments included hollow tree logs, small rocks and plants. The tortoise initially fed with carrot, greens, tomatoes, ladies finger, beans, and pumpkin. The feed was given twice daily morning and evening. Feed supplements like ostocalcium syrup, Live-52 liquid and vimeral liquid were also provided. Portable water was provided in shallow plates at various points in the enclosure. Random fecal samples were collected to find out parasitic loads in every week. Deworming was done regularly by mixing anthelminthic in the feed. A Luke warm water tip was given twice a week to avoid dehydration. Top layer of sand in the enclosure was removed once in a month and new sand was provided to avoid infestation and infection.

The entire rescued and rehabilitation process was followed using IUCN guidelines in sterilization, husbandry, and genetic identification, growth monitoring and pre-release acclimatization. The genetic identification results from CCMB, Hyderabad have geotagged, these individuals as belonging to the Southern Zone of India.

As per the Geotages, in STR a survey was carried out by the team (vets &Bios) for the presence of star tortoises, for their edible plants, water sources, hiding places and suitability of the area for the release of the seized tortoises. Based on the results, T.N. Palayam, Thalmalai, Thalwadi and Jeerahalli Reserve Forests were selected for release. The diet fed in captivity was gradually replaced with different wild edible plants and their preference was observed. Accordingly, the team consists

of Veterinarians and Biologists transported 673 star tortoises in 8 different boxes to STR by road and released them in 13 locations of 4 different Reserves as per the order of Principal Chief Conservator of Forests & Chief Wildlife Warden of Tamil Nadu. In 12 locations 50 animals each and in one location 73 animals were released in scattered manner on November 2020 with suitable sex ratio with different colour marking (Red, Green, Yellow and Blue) on top of the carapace of the each animal for future monitoring. All the staff of each Reserve was sensitized about this species and monitoring.

CRR 3

IMPORTANCE OF ANAMNESIS TO DISCOVER WILDLIFE CRIME AND THERAPEUTIC MANAGEMENT WITH REHABILITATION OF EMERGENCY CASES OF WILD ALEXANDRINE PARAKEET DUE TO HUMAN CONFLICT

Katkhede P.D.*, Waghmare S.P., Bhikane A.U., Pajai K.S.
Department of Veterinary Clinical Medicine, Ethics and Jurisprudence
Post Graduate Institute Of Veterinary and Animal Sciences, Akola
parikshitkatkhede@yahoo.com

Two Alexandrine parakeets brought by one person at TVCC, PGIVAS Akola with the starting history of bloody discharge from eyes and nose, parakeets were found on ground. On face investigation of the person to find out more detail history of case for thorough diagnosis, it was evident that the person had illegally captured this bird for selling purpose and he ran away by keeping birds on clinic.

Onsite clinical examination revealed haemorrhage from eyes and nose. Temperature was 102^0F.Birds were dull, depressed, unable to stand and fly. The case was diagnosed as one bird was in shock and another one passed during treatment, had multiple fractures with internal haemorrhages. Treatment involved hydration therapy Inj. RL 2ml I/v, Inj. D5% 2ml S/c along with Inj. Dexamethasone 0.2ml I/m, liq. Enrofloxacin @10mg/kg b.wt PO BID for 3 days, drop Setwell (Ayurvedic) 1 drop BID in drinking water, Eye drop ofloxacin 1 drop QID, drop Vetrivit avian 1 drop PO OD. Animal showed positive response to treatment within hour. Bird was kept under observation and for treatment upto 5 days. The case was recovered successfully without any further complications and after recovery bird was handed over to Forest Department for further release in the environment.

CRR-4

INCREASING INCIDENCE OF HIMALAYAN BROWN BEAR ATTACK ON LIVESTOCK IN KARGIL

Shamim Ali[a] and Mansoor Ali[b]
SKUAST-K Leh and Animal Husbandry Department Leh Ladakh
shamim.drlal@gmail.com

The Himalayan brown bear (*Ursus arctos isabellinus*) locally known as Dren-Mo, Balu. This endangered Species is confined to three major mountain ranges of the Hindu Kush, the Karakoram and the Western Himalayas. It has been observed that this species is frequently sighting close to human settlement and the incidence of attacking on livestock have been increasing from last seven to eight years particularly in the regions of Drass, Sapi, Suru, Karkichoo, Wakha-Mulbek and Tangole. Recently such incidences were also reported from Chanigund, Gomakargil and Titichumik of Kargil district in which they attacked the small ruminants and poultry. The growth in the number of such attacks on livestock has created a panic among the local people. Therefore such incidence is of great concern due to human life threat and heavy economic loss of the poor farmers. Increasing in the number of such incidence may be due to shrinkage of ecosystem and breeding ground, irresponsible human activities such as overgrazing, poor garbage management, lack of concrete shed for livestock and availability of waste food near the military camps which are forcing them to travel towards the human habitat and nearby villages in search of food and attack the livestock. Such wild attack are the evidence to the fact that the negative impact of 1999 Kargil war with heavy shelling for more than two months that destroyed their natural habitat. It's found that brown bear hibernate from November to March, but due to climate change there has been shorter winter and longer summer which may be responsible for disturbing their hibernation cycle due to which they come to the lower reach even in December and early march and frequently during June to august in summer.

CRR-5

UNDERSTANDING & ADDRESSING THE DRIVERS OF HUMAN WILDLIFE CONFLICT AND RECENT MITIGATION EFFORTS IN UTTARAKHAND

Aditi Sharma,
Senior Veterinary Officer, Rajaji Tiger Reserve, India
aditis2013@gmail.com

Human-wildlife conflict has been a recurring issue in the state of Uttarakhand. While the local issues are usually addressed, the drivers responsible have not been investigated adequately. The conflict animals include both life threats and cause

serious crop & property damage and thus, invoking negative response from people most of the time resulting in retaliate killing of the wild animals. Maximum numbers of human attacks and deaths have been reported due to Leopard, while Elephants also play a major role in human attack in addition to significant level of crop damage. As a case in point, Motichur Range of Rajaji Tiger Reserve and Haridwar range of Rajaji Tiger reserve and Haridwar Forest Division are among the hot spots of HWC in Uttarakhand. The issues have largely been understood based on the conflict occurrence but the need of a well-organized baseline data and species wise hot spot mapping of the conflict is yet to be addressed. As of now, the HWC has been managed with providing immediate compensation but it serves only limited purpose. Based on the findings and the mitigation measures, it is proposed that future efforts here need to be substantiated by the habitat and human-linked drivers of HWC so as to ensure long-term solutions to this problem.

CRR-6

PHYSICAL ESTIMATION OF CROP LOSS DUE TO BLACK BUCK RAID IN AGRICULTURE FIELD

Surjeet Singh and J. M. Chahande
Department of Livestock Production and Management
Nagpur Veterinary College, Maharashtra Animal and Fishery Sciences University, Nagpur-440001, Maharashtra
j.chahande52@gmail.com

Human – wild life conflict is a common phenomenon from the past and has been a significant problem throughout world. One of the reasons of conflict is crop damage by wild ungulates. The problem arises as they are compelled to share the common recourses. Crop damage associated conflict is of great concern since it involves the livelihood of poor communities. In the study area the farmers were suffering from crop damage particularly by black buck. The results indicated that the total area under crop damage was 5976 ± 397, 4552 ± 266 and 3039 ± 101 square feet / acre; the average loss due to crop damage by black buck was 20.47 ± 0.16, 0.63 ± 0.04 and 0.47 ± 0.02 Quintals; the physical loss accounted to 13.72%, 8.42% and 6.20% and the monitory loss accounted to Rs. 3111.52 ± 206, Rs. 1285.41 ±75 and Rs. 1031.12 ± 51 for wheat, soybean and red gram respectively. Quantitative and monitory more loss in wheat crop than grains was found. It is concluded from the study that the loss occurred due to crop damage by black buck is very important to small holders and constitutes the major reason for conflict.

CRR-7

RESCUE EFFORT OF A SUB-ADULT FEMALE WOLF IN UMRER TERRITORIAL FOREST

Vinit Arora
Srushti Paryavaran Mandal, Nagpur, Maharashtra
vinitarora75@gmail.com

A sub-adult wolf whose head was stuck in a plastic container was rescued near a village named Saaiki which comes under North Umred territorial forest of Nagpur Division.

The rescue involved few of experienced wildlife activists with a few exhausting attempts to capture it after a one half hour of chase before cornering the wolf by the side of lake. Covering its face with a camouflage cloth we gave him time to recover from the trauma of being caught. It was a female sub-adult wolf. Other than the plastic prison around her head, she looked healthy and it appeared to be a day or two since she had gotten stuck. Luckily, the plastic jar had many small perforations through which she could breathe.

Attempts were made to cut the jar to free her. But it proved to be impossible since the neck of the jar was made of exceptionally tough plastic. The jar was pushed forward gently and tried to ease her ears free. With much delicate maneuvering we managed to accomplish our task and soon both ears could be free from the box. Now it seemed like a gentle push would do the rest.

With a final tug, the jar fell to the ground and revealed a set of beautiful yellow eyes. As I held her firmly with the help of a cloth, our team member quickly inspected her head and gave the signal that all was fine. Her legs were untied and finally the moment of release was upon us.

It was then that a disturbing thought crossed my mind "How could one good act of conservation be nullified and lead to the harm of some other species?" A snake was rescued and released in the wild but the plastic jar left behind resulted in a near-fatal situation for the endangered wolf. We need to release that our one act of negligence can be a life threatening misfortune for another living being.

CRR-8

RESCUE OF STINGLESS BEE COLONIES DURING DEFORESTATION: AN INNOVATIVE METHOD FOR CONSERVATION

Jagruti Roy* and Ashish Kumar Jha
Department of Zoology, Hislop College, Nagpur- 440001, India
jagrutiroy@hislopcollege.ac.in

Stingless bees are ecosocial bees known for their role in pollination and Meliponi products *viz*., honey, fermented bee pollen and propolis. The nest of stingless bees can be found in hollowed cavities of tree trunk, crevices in brick and mud wall, burrows made by animals, termite and ant nests. Urbanization has created ecological threat due to felling of trees resulting in habitat destruction of pollinators. Stingless bee species are also vulnerable to habitat destruction endangering its diversity and abundance. To secure the ecological integrity of stingless bee colonies, rescuing and shifting of bee colonies at the time of felling of trees is an important practice in conservation. The present study was carried out at Raj Bhavan, Nagpur, where 60 trees of *Gliricidia* sp. were purposefully fell down, to undertake tree plantation designed to favor Apiculture. A total of 25 stingless bee colonies were rescued in the year 2019. The tree logs with stingless bee colony were carefully split open using chisel, the queen, whole brood without damaging the cells, few pollen pots and honey pots, were transferred to the wooden box designed for rearing. 68% of colonies were recovered well and 32% of colonies were perished. At present,11 colonies are being reared at Raj Bhavan. 02 colonies each were donated to BNHS, Bhisi village, Chimur, Chandrapur, Aura Park, Kathalabodi, Bazargaon and Grace Farms, Mahurzari, respectively. The rescue of stingless bee colonies during the tree felling not only lead to conservation but also provided us with therapeutic products which are immunity boosters with positive results against COVID-19. Such rescuing of stingless bee colonies can be employed at different land use management sites to mitigate the environmental impacts of felling trees and rearing of stingless bees also provide additional income to rural families.

CRR-9

MODELLING OCCUPANCY OF TIGERS (*Panthera tigris*) IN A NON-PROTECTED AREA OF NAGPUR, MAHARASHTRA

Dhanusha Kawalkar[1 2*], Rahul Mungikar[2 3], Kundan Hate[4]
[1]Division of Conservation Ecology, SACON, Anaikatty P.O., Coimbatore, Tamil Nadu, India
[2] BVIEER, Dhankawadi, Pune[3]Bombay Natural History Society, Mumbai, Maharashtra
[4]Nagpur Forest Division, Maharashtra Forest Department,
dhanushakawalkar@gmail.com

Modelling occupancy of tiger's (*Panthera tigris*) in non-protected area and extending critical tiger habitat holds foremost importance in their conservation and management. Hence, we conducted a study to identify individual tiger home ranges and estimate their occupancy in the Kalmeshwar- Kondhali Block (KKB). We also attempted to understand the factors influencing the tiger occupancy. Because of the tiger's elusive nature, we used the camera trapping method collect its presence/absence data. We used a novel method of beat based tiger monitoring and hence deployed the camera traps in 16 beats (each of 7 sq km). Further, we used PRESENCE 10.9 to model single- season single species occupancy. Results show that there are seven resident tigers in the KKB. The model simulations showed that the tigers (n=7) occupy approximately 49% (Ψ=0.49, SE= 0.13) of the landscape in Kalmeshwar- Kondhali Block. Also, we observed that the low risk areas with high easy prey base (livestock) and low risk areas with moderate natural prey base holds highest tiger occupancy. This research provides an effective beat-based monitoring approach for estimating occupancy using camera traps (1 camera/7 sq km beat size). Further, the occupancy studies can be done by the front line staff of the forest department as the beats are the smallest unit of administration. Further, a detailed methodology can be added into the working plans of the division (where tigers are present) which will help in the tier monitoring, prioritization of the critical tiger habitats and also to reduce human- tiger conflict in human-dominated areas.

CRR-10

RETROSPECTIVE STUDY OF RESCUE, TREATMENT AND REHABILITATION OF WILD ANIMAL BY TRANSIT TREATMENT CENTRE, NAGPUR

[1]Syed Bilal Ali, [1]Mayur R. Kate, [2]S.V. Upadhye, [3]V.M. Dhoot, [3]G.R. Bhojne, [4] G. Mallikarjuna, [5]Prabhu NathShukla and [6]K. Hate
[1]Veterinary Officer, Transit Treatment Centre, Nagpur Forest Division, Nagpur, [2]Department of Veterinary of Surgery and Radiology, [3]Department of Veterinary Clinical Medicine, [4]Chief Conservator of Forests, Sanjay Gandhi National Park, Borivali, Mumbai, [5]Deputy Conservator of Forests, Nagpur Forest Division, Nagpur, [6]Member: Wildlife Advisory Board, Maharashtra State, [4]wildlifer.
mayurkate.kate4@gmail.com

The Transit Treatment Centre was established with the aim and objective of rescue, treatment and rehabilitation of wildlife under Nagpur Forest Division. Since the beginning centre is regularly engaged in rescue, treatment and rehabilitation of wildlife from rural and urban areas. Area of Nagpur Forest Division comprises 14 ranges. It comprises of rich wildlife habitats in which the variety of fauna exists. Since beginning, total cases reported at TTC are 3500. Out of which 2409 cases have been released, 1023 cases have died and 68 cases have been transferred to rescue centre. The overall survival rate of the centre is 69 percent.

CRR-11

SUCCESSFUL RESCUE OF LEOPARD FROM WELL

[1]Syed Bilal Ali, [1]Mayur R. Kate, [2]Prabhu NathShukla, and [3] K. Hate
[1] Veterinary Officer, Transit Treatment Centre, Nagpur Forest Division, Seminary Hills, Nagpur, [2]Deputy Conservator of Forests, Nagpur Forest Division, Nagpur, [3]Member: Wildlife Advisory Board, Maharashtra State.
mayurkate.kate4@gmail.com

A female leopard aged approximately of 2 years which was drowning in well was rescued from Dorli village under Kondhali Range (Nagpur Division, Nagpur). The rescue operation took three attempts for successful retrieval. The operation lasted for more than 8 hrs. The rescue involved use of trap nets, trap cages, ropes and cot. Firstly, the attempt was made by placing trap cage over the cot which failed as leopard failed to get into cage. Secondly, rescue was tried with single and double layered trap net respectively which also failed by biting and cutting of the net. Thirdly, the trap cage was allowed to settle into the water and the leopard was trapped in double layer placed on the cot. The leopard was trapped in double layer net and then shifted into cage. To remove the trapped net,

animal was chemically immobilized using xylazine-ketamine combination as per standard dose rate and the trap net was removed. On physical examination animal was found healthy so with all precautionary and administrative approval, leopard was released into its natural habitat.

CRR-12

RESCUE OF INDIAN GAUR FROM HUMAN DOMINATED LANDSCAPE

[1]Syed Bilal Ali, [2]A.G. Dubey, [2]S. Nandagawali and [4]Tista. Joseph
[1]Veterinary Officer, Transit Treatment Centre, Nagpur Forest Division, Nagpur.
[2]Project Veterinarian, Elephant Cell, Wildlife Institute of India, [3]Veterinary Officer, APCCF Wildlife (east) and [4]Post graduate Scholar.
mayurkate.kate4@gmail.com

A male bison weighing approximately 700 kg was coincidently spotted in the human dominated Yerkheda village in vicinity of Seminary hills range approximately 50kms away from tiger reserve and protected area. The bison unexpectedly was spotted by the local people in to the boundary wall of a garage in the last week of March month. On observation of the situation, team decided to rescue the animal by chemical immobilization. As, all the preparations for darting was done. The animal jumped the 8 feet wall and moved in to thick patch of trees. Team again started the search operation and soon animal was located adjacent to the highway road. Further, the animal was chemically immobilized with the combination of xylazine-ketamine combination at the dose rate of 0.6mg /kg and 2mg/kg body weight respectively. The induction period was 12 mins. Clinical examination revealed a minor lacerated wound on the lumbar region which was cleaned and dressed with povidone iodine, antibiotic powder and sprayed with antiseptic spray. Long acting antibiotic, anti-inflammatory and analgesic drugs were administered intramuscularly. The complete rescue operation lasted for about 10 hours. Finally, the animal was transferred to its natural habitat and released back in wild. Thus, it shows that increasing human population, infrastructure development and loss of habitat has resulted into reduction in pastoral land leading to straying of wild animals into human dominated landscape.

CRR-13

SUCCESSFUL RESCUE AND RELEASE OF MALE LEOPARD USING MONKEY TRAP CAGE

Syed Bilal Ali
Veterinary Officer, Transit Treatment Centre, Nagpur Forest Division, Nagpur
drsyedbilalali086@gmail.com

A male leopard aged approximately 4-5 years was found drowning in the well of about 65 feet depth with no boundary wall, near the holy place; during the ritual ceremony of local villagers was going on. On the spot, local mob of around 1500 people was present for ceremony, so with the permission of higher official's quick rescue was planned to save the life of an animal. For rescue operation cot, ropes and monkey trap was used. Initially cot tied with rope was placed at the water level in hanging position, so that the drowning leopard could come over the cot and take rest on it. Further the monkey trap cage with live poultry bird was placed in the cage and cage was placed on the cot. Eventually after the waiting period of around one hour the leopard trapped in cage. Thus the rescue operation suggests that monkey cage weighing 35 kg with the dimension of 3.0 x 2.5 x 2.5 ft can be safely used for easy and fast rescue of adult leopard.

CRR-14

ESTABLISHMENT OF TRANSIT TREATMENT CENTRE, NAGPUR FOREST DIVISION, NAGPUR- A BOON FOR WILDLIFE CONSERVATION

Kundan M. Hate
Member: Wildlife Advisory Board, Maharashtra State.
kundanhate@gmail.com

Transit Treatment Centre was newer concept with aim to provide immediate rescue, treatment and rehabilitation of wild life the veterinary dispensary nearby tiger project, wildlife sanctuary or protected forest are lack of expertise and facilities. To overcome this and to save precious life of wildlife, Transit Treatment Centre, Nagpur was established. Till date more than 3500 animals including mammals, birds and reptiles have been treated.

CRR-15

OUR JOURNEY FROM A KALANDAR MADARI TO PARA-VETERINARIAN IN A DANCING SLOTH BEAR REHABILITATION CENTRE

Imam Sab[1] and Saddam Husen[1]
[1]Bear care staff, Wildlife SOS, Bannerghatta Bear Rescue Centre, Bangalore, 560083
bbrc@wildlifesos.org

Kalandar communities are originally gypsy communities with a highly nomadic lifestyle and were famous for their mastery over animals. Initially, these communities took up the profession of Sloth bear fighting in India. This community has performed a 400 years age-old practice of dancing Indian sloth bears. In 2002, Wildlife SOS collaborated with the state forest department, started the rehabilitation of Kalandar communities by educating them and providing alternate livelihood as an extension of the dancing bear rescue project. Over 3,000 families spread out through six states and over 15 villages; have received support to become economically self-sufficient for two decades.

After surrendering my dancing sloth bear in 2004, I worked as an assistant keeper under trained senior animal care staff. Slowly after ten years, my para-veterinarian journey started. As a para-veterinary worker and not having any education, it wasn't easy to understand animal procedures, medicines, surgeries, etc. Gradually, I was trained under several wildlife veterinarians, and it became a regular job because of the core interest in the work. The routine tasks start with arrangements of all the equipment for minor and major surgeries and treatments, maintaining the operation theatre and checking the necessary medicines and consumables, assisting post mortem, and going for the conflict bear rescue operations as and when required. The journey started primarily as an animal performer roaming from villages to villages. It narrowed down as regular salaried staff with settled family and kids' education to a better life.

CRR-16

HUMAN-ELEPHANT CONFLICTS IN BANKURA DISTRICT, WEST BENGAL

Subhasis Mahato and Tulika Panda
Department of forestry, PRMS Mahavidyalaya, Boragari, Jamboni, Bankura-722150
subhasis.prl@gmail.com, tulikapanda3@gmail.com,

Due to land use land cover changes, habitat loss is a conservation problem brought about by a variety of factors. Human - elephant conflict is a major intractable problem. Now recently human – elephant problem become very common in the Bankura district of West Bengal. Mainly during paddy season, elephants travel to the agricultural

land area and edge of the forest for a few weeks. Elephant destroyed lots of crops; house and also they injured humans and cattle's etc. Human injuries observed more in the study area when the elephants damage their crops and humans are disturbing elephant migration routes. Vice-versa elephants were also injured by some human activities like use of stone, flambeau, crackers etc. to driven out the elephants. The information was collected from 8 villages during December 2019 to January 2020. This human - elephant conflict have a detrimental effect on both and this information was collected by direct observation, querying from villagers and forest officers. During the study we observed that forest department taken so many steps to reducing the conflict, but due to less awareness among the local people the elephants are more aggressive and damage more.

Based on our survey results we propose that increases awareness campaign among local people, management of forest areas through reforestation, stop illegal felling & NTF'P collection, the management of habitat corridors, and developed good relation between the villagers and forest officers so that could help prevent further conflict.

CRR-17

PROSTHETIC REHABILITATION OF A SOFT-SHELL TURTLE

Shobha Jawre[1], Madhvee Dhairykar[1], Manoj Reddy[2] and Nidhi Rajput[1]
[1]School of Wildlife Forensic and Health, Nanaji Deshmukh Veterinary Science University, Jabalpur, Madhya Pradesh
[2]Department of Surgery and Radiology, COVSc&AH, NDVSU, Jabalpur, Madhya Pradesh
s.jawre@rediffmail.com

A soft-shell turtle was presented with a history of vehicular collision. Clinical examination revealed shell fracture in the carapace as well as hind limb paralysis. Turtle was bright and alert and its excretory system was also functional. External fixation was done using the adhesives to fix the carapace. As the turtle was trying to move with its fore limbs hence it was decided to place the prosthesis to support its hind body and further movement. Supportive medicines and physiotherapy were also given to revive the normal functions. In this case, internal organs were not injured which made the turtle to survive the trauma. The practice of prosthesis is common in mammals but we tried the same in the reptile which proved to be successful.

CRR-18

ELEPHANT TRAPPED IN A 50-FOOT WELL RESCUED AFTER 18-HOUR OPERATION IN TAMIL NADU

A. Prakash, M.V.Sc., PGD (Wildlife Forensics and Nature Conservation),
Forest Veterinary Surgeon, Forest Veterinary Unit,
Cauvery north wildlife sancturay, hosur forest division, Tamilnadu.
prakash.salem@gmail.com

On 19.11.20 Friday, earthly morning 4.30 am at Elaguntur village, Palacode section, Placode range, Dharmapuri division, incident was reported that an adult makhana elephant, aged about 25 years old was accidentally fallen in to a well of 60 feet depth, and trapped inside a narrow ring concrete deep well with water about 6 feet height, in which the diameter of well is almost equal to elephant length. There was no space around the elephants to go on side and underneath it. On the receipt of this information forest veterinarian rushed to the spot with team and get into well by rope and conducted the rescue operations from morning 6.00 am to 11.30 pm. In this work, 3 attempts were failed due to elephant pull the pipe inside the well and damages the pipe so unable to took the water from well cannot make rampage also due to heavy concrete wall with pillars. Using more than 150 tied sand bags were put into the well to absorb the water and make elevation to stand elephant on height during deep sedation after successful sedation the motor along with pipe was took inside well to remove the water from the well to avoid drowning of elephant and making space for secure roping and tying legs for lifting from the well. In mean time elephant was feed with tender coconut leaf and tree leaves.

In this work challenge was elephant stand at juncture of well with water about 6 feet we can't go for deep sedation it might make the elephants to sit on its sternum (chest) as there was no space it can't able to lay on its lateral recumbency. If elephant sit on chest under sedation for more than 10 to 15 minutes it succumbs to death. After keen monitoring the movement of the elephant then it was tranquilized using xylazine and ketamine in recommended dose. for standing sedation considering life risk to elephants and this dose only sedate the elephants for short duration. In this situation, putting rope around leg and waist by hanging on the rope above the animals for our convenient was not easy, even then also elephant was roped safely after sedation then slowly lifted out from the concrete ring wells. In meanwhile once elephant come out of concrete ring well suddenly elephant was loosed out from tied belt due to elephant aggressive movement and fall down at mid of the well in abnormal position upside head down and leg upside during this critical emergency time Dr. Prakash along with his team tied the individual leg with belt during that work aggressive kick and vigorous movement of leg makes work very life risky and threading instead of that timely the legs were belted and tied to crane and lifted the elephant out of the well.

After 18 hrs of struggle elephant was rescued while doing so suddenly the elephant become aggressive, fear and entered towards public crowd of more than 100 people. Then elephant was safely reaching the nearby RF during night then also elephant was followed for three days continually it bears good health condition with proper feeding and watering.

CRR-19

RESOLVING HUMAN-BIRD CONFLICT: A CASE STUDY OF THE EDIBLE-NEST SWIFTLETS IN THE ANDAMAN AND NICOBAR ISLANDS, INDIA

Shirish S Manchi
Division of Conservation Ecology, Sálim Ali Centre for Ornithology and Natural History,
Anaikatty P.O. Coimbatore, Tamilnadu, India-641108
edible-nest@gmail.com,

Biological resources have always been significant for economic benefits, further leading to conflicts. One such resource is the edible-nest, made up of saliva produced by the swiftlets (*Aerodramus sp.*) of the tropical region. It is considered an essential item in Chinese cuisine and for medicine, making it a significant and one of the most expensive animal products trafficked globally. The illegal nest-collection in Andaman and Nicobar Islands led to a decline of ~80% Edible-nest Swiftlet population between the mid-80s' and mid-90s'. Hence, a unique participatory in-situ and ex-situ approach to resolve the conflict was initiated. Initially, the problem was identified, and the nest collectors were motivated for round the clock protection of swiftlets at three potential sites. During the process, they were trained for scientific understanding of the species for positive human-animal interaction. They were also prepared for the team work and equal benefit sharing of the resource. Simultaneously, the efforts for edible-nest farming were initiated. The in-situ and ex-situ measures depicted a significant increase in the wild population in caves and breeding attempts in ex-situ habitat. Based on the wild population recovery and the in-situ and ex-situ protocol developed for further sustainable use of this natural resource, the Edible-nest Swiftlet was removed from the Schedules of the Wildlife Protection Act (1972). Further expansion of the in-situ and ex-situ conservation efforts is underway.

CRR-20

DANGERS TO WILD LIFE FROM PET AND FERAL ANIMALS

Sarabjeet Singh*, Anil Kumar Pandey[1] and Utsav Sharma[2]
Division of Veterinary Gynaecology and Obstetrics, Faculty of Veterinary Sciences and Animal Husbandry, Sher-e-Kashmir University of Agricultural Sciences and Technology of Jammu, R. S. Pura, Jammu-181102
dirtyvet@gmail.com

Every now and then Black bucks (*Antilope cervicapra*) and other wild animals are killed by stray dogs and these incidents are well reported by Indian newspapers. According to an article published in Guardian this year, pet cats kill 230 million native Australian animals each year. Apparently Australia is at war with feral cats for past many years. Damage to wildlife diversity caused by the animals that flourish in human populations (mostly dogs and cats) is immense and yet it is not in focus of discussions.

In present context of pandemic of COVID-19 we can understand how this can be a route to many wild life diseases leaking into human population and thus becoming a major source of zoonotic disease in future also.

Dogs and cats usually get enough food to eat when they live in urban populations but when these animals are directly in contact with wildlife, they wreak havoc on wildlife population due to their natural hunting instincts. Dogs hunt animals in packs therefore dogs have the capacity to kill large animals while cats are solitary hunters and mostly prey on small animals like wild rodents and birds.

The population of dogs and cats should be restricted around wildlife areas by carrying out regular birth control programs in these areas. It's our duty to control the population of animals proliferating at expense of a hugely diverse wildlife and also to spread awareness on possible zoonotic risk of this situation.

CRR-21

CROSS-PLATFORM APPLICATION FOR RESCUE OPERATIONS

Omkar Kekre, Nihal Reddy and Rohit Hazare,
Srushti Mehatkar Affiliation – WildCER
nestoftern@gmail.com

Our proposal is a cross-platform app that serves as a bridge between wildlife rescue organizations and the wildlife veterinarians. A cross-platform application works as a website, an android app, and an IOS app. The application will have independent logins for rescue organizations and wildlife veterinarians, with differentiated roles.

The app will have following features:

1. In case of emergency, ease of contact with the local organizations is maximized.

2. The rescue organizations can enter the data related to the rescue operation.
3. The wildlife veterinarians can mention their field practices and related information.
4. Information about first aid will be made available to authorized logins.
5. Resource Sharing section–here one can find the data of all the equipment and man-power available to use in case of a rescue operation.
6. If someone lacks a device, a drug or any related resources, they can find the person of contact from whom these resources can be made available, and all of this in no time.
7. An easy to fill first information form, with a common database.

All the above features are strategically designed to facilitate quick actions and provide the best possible first aid. The biggest advantage here is going to be the easily available organized data. The platform can then be scaled up for other critical requirements.

CRR-22

MANAGEMENT OF PARAPARESIS IN AN INDIAN JACKAL (C*anis aureus indicus*): MEDICAL MANAGEMENT, PHYSIOTHERAPY & APPLICATION OF BRACES

Upadhye, S.V [1]., Tista Joseph[2], Kolangath, S.M[3]., Dhoot, V.M[4]., Shalini A.S[5] and Pawshe, M.D[6].
Wildlife Research & Training Centre, Gorewada, MAFSU, Nagpur

1. Director, Wildlife Research & Training Centre, Gorewada, Nagpur (MH)
2. Masters Scholar, Dept. of Vet Surgery & Radiology, Nagpur Vet.College, MAFSU
3. SMS, Biotechnology, Wildlife Research & Training Centre, Gorewada, Nagpur (MH)
4. Deputy-Director, Wildlife Research & Training Centre, Gorewada, Nagpur (MH)
5. SMS, Medicine, Wildlife Research & Training Centre, Gorewada, Nagpur (MH)
6. SMS, ARGO, Wildlife Research & Training Centre, Gorewada, Nagpur (MH)

shirishupadhye@gmail.com

An adult Indian Jackal (*Canis aureus indicus*) with paraparesis was transferred to Gorewada Rescue Centre, Nagpur for rehabilitation and further care. The jackal was unable to bear weight on hind limbs for over a month post rescue and had deep seated decubitus ulcers when reported at WRTC. The paws and anterior metacarpal regions had also sustained severe drag injuries with the right side being worse than the left. The patient had bowel incontinence and urinary retention. The hindquarter motor and sensory reflexes were sluggish and were completely absent below both hock joints. Radiography revealed an L6 spinal fracture with L6-L7 dislocation and a dislocation at the left hock which had fibrosed. The right spinous process of L7 was also fractured. Urine collected by manually expelling the bladder was examined that revealed severe urinary tract infection.

The jackal was medically managed with Inj. Methylprednisolone Acetate started @ 5mg/kg BW and tapered off, Inj. Neurobion, Cap. Palsineuron (Ayurveda) for the neurological deficit; Tab. Nitrofurantoin PO TID and Inj. Ceftiofur sodium @ 2.2mg/kg BW SC OD to manage the urinary tract infection and infected soft tissue injuries; Tab. Bethanecol @ 20 mg PO TID, later BID; The patient also received Vitamins B-complex and Vitamin C supplementation. The decubital sores were managed by dressing with povidone iodine, ALUSPRAY-AWD®, padded bandages where possible and padded bedding.

In adjunct to medical management, the jackal received physiotherapy for 2 months in the form of massages, passive range of motion exercises, a full body sling to support walking and infrared therapy. Customised braces were designed with a light aluminium backbone, polypropylene and Velcro, with the soles made from airplane tires to ensure maximum durability and anti-skid. The final brace had a figure of eight hinge at the hock joint to add more flexibility. Initially with some assistance and eventually without help the jackal adapted to the braces and was able to walk with the braces.

CRR-23

SUCCESSFUL RELEASE OF SEIZED INDIAN PANGOLIN (*Manis crassicaudata*) TO ITS NATURAL HABITAT

S.K. Joshi[1], R.K.Verma[1], J.Singh[2], R.L.Rakesh[1], Preety Singh[3], A, Sonwani[2] and B. Shrimali[2]
[1]Veterinary Officer, Forest Department-Chhattisgarh, [2]Wildlife Health and Forensic Centre, D.S.V.C. Kamdhenu Vishwavidyalaya, Durg [3]IVRI, Izatnagar, Bareilly
vet_jasmeetsingh@rediffmail.com

A female Indian Pangolin was seized at the Udanti Sitanadi Tiger Reserve's buffer area from poachers of neighboring district. Morphological parameters were 09kg body weight, body length 76cm, head length 9cm, tail length 45cm, shoulder height 17cm, hind leg and fore leg length 16cm & 13cm respectively, ear length 3cm, neck girth 22cm, chest girth 38cm, size of scale of different body parts, head 0.8cm neck 2.9cm back 3.9cm rump 4.2cm tail base 3.8cm tail tip 1.3cm long. The seized animal was observed as healthy and passed urine and defecated immediately after keeping it inside a simulated caged enclosure with shrubs & termites. After completing all legal formalities against poachers, chief judicial magistrate issued order for release of seized Indian Pangolin to their natural habitat and the animal was released in core area of USTR on next day evening.

CRR-24

IMUNOCONTRACEPTION AS A MANAGEMENT TOOL IN DEALING WITH HUMAN WILDLIFE CONFLICT IN INDIA

Sanath Krishna Muliya[1], LallianpuiiKawlni[1], Kafil Hussain[1], Priya Gusain[1], Vishnupriya Kolipakam[1], Qamar Qureshi[1] and Yadvendradev Jhala[1].
[1] Wildlife Institute of India, Dehradun, Uttarakhand - 248 001.
kafil.hussain@gmail.com

Human-Wildlife Conflict (HWC) is currently one of the major threats to the continued survival of many species in different parts of the world, and in certain cases a significant threat to health and lives of local people, the security and sustainability of their livelihoods, and to the state and national economies. Thus, resolving human-wildlife conflict has become an important aspect of conservation initiatives, especially in biologically rich countries like India. Currently, a range of short-term strategies are used to mitigate HWC in India, essentially as an immediate tactical strategy to deter conflict animals. These include: creating barriers (e.g., fencing, boundary wall, trench, etc.), compensation schemes, and eliminating/ translocating " problem" individuals from the population. These measures are however ineffective over long period due to various reasons, including animals getting habituated to the barriers and financial burden due to ever increasing claims under compensation schemes. Thus, to minimize HWC, it is now imperative to develop new strategies, including active wildlife population management techniques. With animal welfare steadily gaining importance, including ethical opposition to the killing of animals, more focus has been devoted to non-lethal population control methods, particularly reproductive control which seems to be a viable option in actively managing HWC species. A wide diversity of such methods has been applied to wildlife reproductive control over several decades. The current presentation focuses on various such techniques, which are currently being explored by Wildlife Institute of India, to control conflict populations of Nilgai, wild pig, elephant and rhesus macaque in India.

CRR- 25

MODELING FOR THE ESTABLISHMENT OF A NETWORK OF PROTECTED AREAS IN THE DIFFERENT LAND USE MANAGEMENT SITE OF GONDIA DISTRICT IN MAHARASHTRA (INDIA)

Sushilani Chakma, Jagruti Roy and Ashish Kumar Jha*
Department of Zoology, Hislop College, Nagpur- 440001, India
ashishkumarjha@hislopcollege.ac.in

Degradation of vegetation is one of the examples of human interference. Some of the major environmental factors that influenced or which are influencing the vegetation or parts thereof are deforestation, overgrazing, erosion and other related factors. To protect the endangered flora and fauna of Gondia district in Maharashtra, a network of protected areas is urgently needed.

CRR- 26

RESCUE OF A SPECTACLED COBRA (*Naja naja*) ENTANGLED IN A METALLIC PIPE

Devendra Podhade, Ranjeet Harne, Amol Rokde, Nidhi Rajput, Somesh Singh and Shobha Jawre
School of Wildlife Forensic and Health, N.D.V.S.U., Jabalpur
drdevendrapodhade@rediffmail.com

A spectacled cobra (*Naja naja*) was brought to the School of Wildlife Forensic and Health, N.D.V.S.U., Jabalpur by the Rescue Squad, Jabalpur of M.P. Forest Department. It was found entangled in a piece of square shaped metallic pipe near a saw mill. Physical examination revealed that the mid portion the snake was entangled in metal piece. The snake was active and alert. Initially, it was tried to pull out the metal piece manually with the help of paraffin gel but success couldn't be achieved. Hence, it was decided to sedate the snake to remove the metal piece. After the sedation, metal piece was cut with the help of electric saw with minimum stress to the snake. The snake recovered successfully and rehabilitated back in the wild.

CRR- 27

CONFLICTS BETWEEN WILDLIFE CONSERVATION AND THE MAJOR LAND USE PRACTICES IN UMRED TEHSIL IN NAGPUR DISTRICT OF MAHARASHTRA (INDIA)

Aniket Dahake, Jagruti Roy and Ashish Kumar Jha
Department Of Zoology, Hislop College, Nagpur- 440001, India
ashishkumarjha@hislopcollege.ac.in

The present investigation contains the results of study conducted in the forest areas of Umred Tehsil in Nagpur districts of Maharashtra (India). The forest areas of this region are situated between the Umred-Pauni-Karhandla wildlife sanctuary. The objective of the study is to inspect the conflict between wildlife conservation and major land use practices. It is observed that the forest areas of the region are excellent habitats for the wild animals in general. Gond and Halba tribals and other forest dwellers have been traditionally living in co-existence with wild animals since ages. However, the wildlife conservation and the land use practice conflict has increased alarmingly in recent years.

The study reveals that the agricultural practices and forestry ultimately effects on wildlife areas. The problems between livestock and wildlife as far as land pressure is concerned have never been as severe as those with crops. The issues need to be solved sincerely if the tiger and other wild animals are to be saved from local extinction in this area.

SESSION - III

WILDLIFE HEALTH

&

MANAGEMENT

WHM-LP 1

MINIMALLY INVASIVE SURGERY IN WILDLIFE

Romain Pizzi
BVSc MSc PhD DZooMed DipECZM FRES FRGS FRSB FRCVS
Royal College of Veterinary Surgeons and European recognised specialist in
Zoo & Wildlife Medicine
romain@wildlifesurgery.org

Minimally invasive surgery (MIS) is currently regarded as the gold standard for many human surgical procedures, and has also been demonstrated to benefit domestic animal veterinary patients for several procedures. Many of the benefits, including small wounds, lower risk of dehiscence, lower risks of wound complications, less pain, rapid recovery and reduced post-operative care and restriction are particularly appealing in applying this type of surgery to wild animal species. Yet minimally invasive surgery also involves specific risks, that differ from open surgery. These include access injuries and the delayed onset of clinical signs from unrecognised bowel injuries during surgery. Increased complexity of equipment also poses a risk, as does the initial learning curve, which can be a hurdle in wildlife. A serious positive publication exists in all of wildlife surgery, which is essential to appreciate when trying to determine a likely surgical outcome. An illusory superiority bias also tends to make surgeon believe their skills and outcomes to be better than they are, so clinical auditing of wildlife minimally invasive surgery outcomes is essential in monitoring and improving an individual wildlife veterinarian's clinical outcomes, and ensuring the safe treatment of wildlife patients.

Minimally Invasive Surgery in Wildlife

Minimally invasive surgery (MIS) has become widespread only recently despite a long history. While Hans Christian Jacobaeus performed the first human laparoscopy over 110 years ago, it was only after the first human laparoscopic cholecystectomy by Erich Mühe 35 year ago that laparoscopy and other minimally invasive surgery came into the mainstream of human surgery. MIS is now regarded as the gold standard for many human surgical procedures, such as cholecystectomy and appendectomy in developed countries. Despite wildlife laparoscopy originating in the late 1970's with reproduction research (surgery performed by eye) still only a small minority of wildlife operations, even in wealthy Western zoological collections, are performed by minimally invasive surgical means.

There are a number of advantages to human and other animal patients with MIS surgery versus traditional open surgery. These include smaller wounds; less post-operative pain; reduced abdominal adhesions; reduced risks from infections; and reduced dehiscence risk. There are unfortunately some disadvantages to MIS, such as increased complexity; longer operating times; longer learning curve; Poor depth perception due to 2-dimensional visualisation; Lack of feed-back and tactile sensation when handling tissues risking tissue damage; and a limited range of motion of inserted instruments. MIS also carries some specific risk that must be carefully considered. These include trocars injuring organs on entry; electrosurgical burns; out-of-view injuries; and the risks of excessive pneumoperitoneum on vascular return and respiration. A particularly serious risk unique to MIS is the delayed recognition of bowel injuries. This delayed onset of clinical signs from bowel content leakage into the peritoneal space carries a higher risk of death than in open surgery. This is exacerbated by injuries that may occur out of the limited field of view of the endoscope, or by inadvertently touching bowel with the tips of an instrument that is still hot after electrosurgical use, in the limited operating space available.

Many of the benefits of MIS, well established in the evidence base for human surgery, could have particularly beneficial applications in wildlife veterinary surgical patients, but despite the fact that the first non-domestic animal MIS procedures were performed half a century ago, demonstration of its advantages over open surgery has remained fragmented and mainly low-level evidence.

It is often claimed that surgeons bury their mistakes. In zoo, wildlife and exotic pet surgery the scientific evidence base is still limited. Much consists of low-level evidence of expert opinion in book chapters, while the small number of primary surgical peer-reviewed journal articles are limited by small patient numbers. The outcomes in the peer-reviewed literature also do not appear to correlate well with the actual outcomes and complications veterinarians experience.

A systematic review of captive and free-ranging non-domestic animal surgery abstracts was performed using MEDLINE, CAB Abstracts, Scopus, and Zoological Record. The majority of publications at 59.69% [95% Confidence Interval (CI) 55.82-63.43%, Standard error (SE) 1.95%] were single case reports, with only 15.19% (95% CI 12.54-18.11%, SE 1.42%) of publications containing more than 10 animals. The complication rate calculated from summation across all papers was 5.67% (95% CI 5.12-6.24%, SE 0.28%). Papers that reported surgical novelty had a very low reporting of complications, with only a 2.21% (95% CI 1.6-3.04%, SE 0.36%), a significant difference from the general publication complication rate ($p<0.001$).

In comparison, total surgical records for a 25-year period from four major Western zoological collections (n=1633) found an actual complication rate of 22.84% (95% CI 20.87-24.94%, SE 1.04%), and 12.31% (95% CI 10.8-13.99%, SE 0.81%) of

zoo surgical patients were affected by major or life-threatening complications. This indicates a marked positive publication bias in the literature that needs very careful consideration by zoo, wildlife, and exotic pet veterinarians when making clinical decisions, as actual surgical outcomes are likely to be far poorer than reported in the literature at present. These factors likely lead to a higher surgical intervention rate in many cases than justified by real outcomes, with real resultant harm and poor welfare to large numbers of animals internationally.

A systematic review and meta-analysis, that attempted to compare open or MIS surgery of the abdomen or coelomic cavity in wildlife species, while appearing to favour MIS, was not statistically significant. Individual patients and reported complications were summated, to estimate total published complication rates. Across all wildlife species a 6.54% absolute risk reduction (95% CI of the difference 5.08-8.14%, SE 0.78, $p<0.001$) was evident in publications of MIS surgery compared to open abdominal or coelomic surgery. There was a statistically significant lower complication rate across all analysed taxonomic groups, but the evidence was at high risk of bias. Examining the records from four major Western zoological collections, across all species, open surgery carried a major complication rate of 26.35%, while MIS only carried a major complication rate of 5.16%; an absolute risk reduction of 21.19% (95% CI of 13.69-29.14%, SE 3.93%). However this was limited by most MIS procedures being performed by a small number of highly experienced wildlife surgeons. Published complication rates were notable lower, indicating likely positive publication bias and outcome reporting bias. This needs careful consideration when wildlife veterinarians attempt evidence based surgical decisions.

Yet, minimally invasive surgery is more complex than traditional open surgery, and hence carries a notable learning curve. Even in domestic dogs it has been shown that more than 80 operations are needed to become safe and competent in just one relatively simple operation in this single species. This is also a problem in wildlife minimally invasive surgery, with it's low case load and variety of species and procedures required. In one wildlife surgery study, while laparoscopic cholecystectomy in bears had a minor complication rate of 7% under field conditions, teaching a far simpler procedures, just a liver biopsy, to local veterinary surgeons still incurred a much higher 28% complication rate. This hurdle is difficult to overcome with wildlife surgery, with a high caseload needed initially, as well as reasonable case load to maintain skills also needed.

Non-clinical human factors can also be an important source of poor surgical decisions and adverse outcomes. Innate cognitive biases may predispose to poor surgical decisions in veterinarians operating on wildlife species, and result in adverse surgical outcomes. 57.14% (95% CI 50.01-63.99%, SE 3.6%) of pre-clinical veterinary students, when self-predicting their surgical skills 5 years after graduation, believed they would be above average, while only 3.7% (95% CI 1.81-7.45%, SE 1.37%) believed they would be

below average. Untrained veterinary surgeons appeared to have an illusory superiority bias, when self-evaluating their surgical aptitude and future surgical performance.

Further, only 3.17% (95% CI 1.46-6.75%, SE 1.28%) ranked clinical auditing as the most important of six suggested options, to improving their personal surgical outcomes once qualified veterinary surgeons. This indicated an innate lack of appreciation or understanding of its value in improving surgical skills and performance. Auditing one's surgical outcomes is essential in any form of surgery, and essential in the MIS of wildlife species, as the evidence base is limited. Without auditing one may simply be performing more complex procedures, but this does not necessarily mean they are beneficial to the patient.

Despite the benefits of minimally invasive surgery in wildlife, it can be hampered by the same risks and restrictions that affect outcomes in traditional open surgery in wild animals. Severe limitations in the scientific evidence, surgeon over-confidence and innate individuals' superiority bias, with a trend towards novel and unproven surgical treatments, and exacerbated by media coverage focusing on impressive surgical procedures rather than actual surgical outcomes and complications poses a notable risk of increasing harm to zoo, wildlife, and exotic pet patients, unless these factors are carefully considered.

WHM-LP 2

IMMOBILIZATION AND ANESTHESIA OF LIONS, TIGERS, AND LEOPARDS

Edward C. Ramsay
DVM, Dipl. ACZM
Professor Emeritus
Department of Small Animal Clinical Sciences
College of Veterinary Medicine
University of Tennessee Knoxville, TN 37996
eramsay@utk.edu

The paper reviews clinical aspects of immobilization, anesthesia, and analgesia of large felids. It is not intended to be an exhaustive review of the literature but will focus on my UTCVM colleagues' and my own experiences. In particularly it addresses those areas where I have received the most questions from my Indian colleagues, and areas where I learned some lessons 'the hard way,' in the hope others don't have to repeat those experiences.

Immobilization

Precautions: In contrast to our domestic animals, precautions such as fasting and preventing drinking are not possible for free-ranging and many of our captive felids. When possible, 24-48 hours of fasting should be performed. Preventing access to water for 4-6 hours prior to immobilization is also desirable. Whenever possible immobilization should take place in a relatively small, confined area, away from water hazards and areas where animals could fall, i.e., moats. Hand injection of immobilization drugs is much less stressing to the animal than darting, and can frequently be performed in small cages or squeeze cages, and/or with training.

For years, ketamine HCl and an alpha-2 adrenergic antagonist (aka, alpha-2) have been the principle drugs used for immobilization or chemical restraint of large felids (Table 1). While ketamine has no reversal agent, it is a relatively safe, and short-acting drug. Ketamine, as sold in most countries, is unconcentrated (either 50 mg/mL or 100 mg/mL) and, as such, large volumes may be required for large felids. Concentrated ketamine (200 mg/mL) can reduce the size or number of ketamine injections or darts required, but the concentrated formulation is not easily available. Ketamine is fairly quick acting, with signs of ataxia, occurring within 5 minutes of i.m. injection but, depending on dosage, effects may begin to 'wear off' 30-40 minutes following administration. Redosing with ketamine, either i.m. or i.v., is frequently required for performing long procedures.

Ketamine at high dosages has the potential to cause seizures, which in my experience, occur most frequently in tigers, so a benzodiazepine, such as diazepam or midazolam, should always be available, or added to the initial drug combinations. If a

tiger has had seizure during a past immobilization, it has an increased chance of doing so in future immobilizations. Diazepam has variable i.m. absorption and should be given either orally or i.v. Oral administration of diazepam, pre-darting, however has not been successful in preventing seizures, in my experience. Rather, for animals prone to seizures, I try to reduce the dosage of ketamine to just what is required, by using a larger dosage of the alpha-2 agent, and adding midazolam, which is absorbed well i.m., to the initial immobilization injection.

Telazol,™ or Zoletil,™ is a combination of tiletamine, a dissociative agent, and zolazepam, a benzodiazepine, and has been used by many veterinarians for felid immobilizations. When reconstituted according to directions, it is relatively concentrated (50mg of each drug/mL), allowing for small injection volumes. It also has the advantage of being able to be reconstituted with less water or another immobilization agent, i.e., xylazine, making the initial injection volume even smaller. Early work suggested Telazol™ should be avoided in tigers but a review of those papers refuted that recommendation, and it is now considered safe to use in tigers.[6] The major complication I have seen with Telazol™ is occasional, very long recoveries; some animals taking >6 hours to recover. These long recoveries seem to occur randomly but appear more frequent when Telazol™ is used in combination with other drugs or is redosed. Due to this latter concern, if an animal has received Telazol™ as the initial immobilization agent, should the animal need more sedation I don't not redose it with more Telazol,™ but use ketamine, instead. Similar to ketamine, tiletamine is not reversable. Zolazepam can be partially reversed with flumazenil, but the dosage of flumazenil is large, flumazenil is short-acting, and it is relatively expensive. As such, I only use flumazenil in animals experiencing exceptionally long recoveries.

Xylazine has been the most utilized and least expensive alpha-2 immobilization agent for large felids. It comes in a concentrated, "large animal" preparation (100 mg/mL), it is inexpensive, and its effects can be reversed with yohimbine. Yohimbine is marketed for small animals in a dilute concentration, but concentrated forms may be obtained from compounding pharmacies. It should be given i.m., unless there is an emergency and even then full reversal doses should not be given i.v., due to the profound cardio-vascular effects. Xylazine should not be reversed until at least 40 minutes after initial ketamine injection, to avoid ketamine 'excitement' following the alpha-2 reversal.

Xylazine has profound cardio-vascular effects and has been replaced in our practice by medetomidine or dexmedetomidine. The latter is the bio-active enantiomer of medetomidine. As marketed for small animals, these drugs are not concentrated but concentrated forms can be obtained from compounding pharmacies. The effects of both medetomidine and dexmedetomidine can be reversed with atipamezole. All three of these drugs are expensive. There are two adverse effects seen with medetomidine and dexmedetomidine: vomiting; and shallow breathing. Vomiting during induction with

these agents is common (up to 30% of the animals) and typically occurs within 5 – 10 minutes after injection. The animal may still be standing at this time and aspiration of vomitus has not occurred, in my experience. More concerning is bradypnea; shallow breathing with deep breaths occurring only once or twice/minute. Counterintuitively, this appears to occur more often in tigers receiving low dosages of medetomidine. When low respiratory rates or mucous membrane color cause concern, respiration can be stimulated with doxapram i.m. or i.v. or, if in a safe environment, a small amount (approximately 10-15% of the total reversal dose) of atipamezole can be given i.v. I usually administer the latter into the lingual vein.

Large felids seem to breath best in lateral recumbency. During short immobilization procedures, endotracheal intubation is not typically required, in part because if the animal is not sufficiently sedated with an alpha-2 drug, it may 'fight the tube,' if one attempts to intubate it. Monitoring during immobilization is usually recording respiratory rates, mucous membrane color, heart rate, and rectal temperature. If a pulse oximeter is available, the monitoring of SpO_2 is also valuable. Supplemental oxygen should be available for animals with reduced respiratory rates and SpO_2<90%. Oxygen can be supplied by nasal insufflation, at 2L/minute. I keep doxapram (for apnea), midazolam (for muscle relaxation and for prevention/treatment of seizures), and reversal agents available as 'emergency drugs,' for all immobilizations (Table 1).

Anesthesia

For longer procedures, such as dental procedures or surgeries, full anesthesia is required. Felids are typically induced using one of the immobilization regimens described above. If depth of immobilization is sufficient, then endotracheal intubation can be performed under injectable drugs, alone. If the animal is not sufficiently sedate for intubation, then it can be further relaxed by administering an inhalant agent via face mask. Most large felids do not require administration of topical lidocaine to assist/avoid laryngospasm but it is necessary to dramatically extend the animal's neck- to almost a 90° angle to the thoracic spine- to accomplish intubation. The use of a rigid stylet within the endotracheal tube is also helpful. Most tigers will take an 18mm or 20mm endotracheal tube, but larger felids my need a 22 mm tube.

Anesthesia is maintained in our practice with isoflurane in oxygen, typically ranging from 2% to 3%. Most animals breathe well under anesthesia but partial reversal of the alpha-2, typically 10-20% of the total atipamezole reversal dose i.m., can be administered to improve respiration, if needed. Monitoring during anesthesia is similar to that described above, but may also include monitoring end-tidal CO_2 and indirect blood pressure monitoring.[4] A wide range of end-tidal CO_2 readings can be tolerated but should CO_2 levels exceed 55 mmHg, manual or mechanical ventilation should be instituted. Similarly, mean blood pressures (MAP) can vary widely during anesthesia but long

periods of low MAP (<50 mmHg) should be address via increased administration of fluids, reducing the inhalation agents (possibly administering i.v. ketamine to maintain safe restraint), and/or the administration of vasopressors.

A major complication of long anesthesia (>2 hours) is the development of hyperkalemia (K^+> 5.5 meq/L). Most animals given alpha-2 agents will show gradually increasing blood glucose concentrations and concomitant increases in plasma K^+ levels during anesthesia. Unfortunately, for reasons yet to be discovered, this occurs in some individuals at a very rapid rate, resulting in life-threatening hyperkalemia prior to the end of the surgery or procedure. Early administration of atipamezole reduces the rate of K^+ increases, and as a result, we routinely administer 12.5-16% of the full atipamezole reversal dose i.m., 2 hours after initiation of inhalation anesthesia.[7] Typically, I will repeat that atipamezole dose q.30 minutes, through the remainder of the surgery or until the full, calculated reversal dose has been given.

Analgesia

For acute pain, such as traumatic injury or post-surgical pain, we rely on a combination of oral non-steroidal inflammatory drugs (NSAID) and opioids. Meloxicam is our most commonly used NSAID and the initial dose is given during surgery, followed by once daily (p.o. or s.c.) dosing for 3-7 days (Table 1). Pre- and post-operative tramadol is given for minor procedures (i.e., castrations, & endodontics), and continued p.o.b.i.d., as needed. For more painful procedures, such as pyometra surgeries, buprenorphine (s.c. intra-operative) is used, instead of tramadol on the day of surgery. A single dose is usually sufficient but an additional dose can be administered 8-12 hours after the initial dose, if necessary. Typically, we transition to oral tramadol the day following surgery.

A number of opioid analgesic applications, such as epidural morphine, sustained-release fentanyl patches, and long-acting buprenorphine preparations, have gained popularity in small animal practice. These are frequently expensive and have not seemed to be of great benefit, in my experience. Additionally, use of multiple, simultaneous opioids may result in opioid dysphoria; something I have seen on three occasions. A tiger experiencing this become manic and is in danger of injuring itself. The condition is treated, and the diagnosis is confirmed, by administration of naloxone or naltrexone i.m., with immediate effect.

Selected Literature

1. Clark-Price SC, Lascola KM, Schaeffer DJ. Physiological and biochemical variables in captive tigers (*Panthera tigris*) immobilised with dexmedetomidine and ketamine or dexmedetomidine, midazolam and ketamine. Vet Rec. 2015;177(22):570.

2. Curro TG, Okeson D, Zimmerman D, Armstrong DL, Simmons LG. Xylazine–midazolam–ketamine versus medetomidine– midazolam–ketamine anesthesia in captive Siberian tigers (*Panthera tigris altaica*). J Zoo Wildl Med. 2004;35(3):320-327.

3. Goodrich JM, Kerley LL, Schleyer BO, Miquelle DG, Quigley KS, Smirnov YN, Nikolaev IG, Quigley HB, Hornocker MG. Capture and chemical anesthesia of Amur (Siberian) tigers. Wildl Soc Bull. 2001;29(2):533-542.

4. Howard L, Bashaw M, Lamberski N, Zuba J, Greenberg M, Janssen D. Evaluation of two anatomic locations for measurement of indirect blood pressure in anesthetized African lions (*Panthera leo*). Proc Am Assoc Zoo Vet. 2006:253.

5. Steeil JC, Sura PA, Ramsay EC, Reilly S, Sedigghi M, Wittemore J. Laparoscopic-assisted ovariectomy of tigers (*Panthera tigris*) with the use of the Ligasure™ device. J Zoo Wildl Med. 2012;43(3):566-572.

6. Kreeger TJ, Armstrong DL. Tigers and Telazol: The unintended evolution of caution to contraindication. J Wildl Manag. 2010;74(6):1183-1185.

7. McEntire MS, Ramsay EC, Price JM, Cushing AC. The effects of procedure duration and atipamezole administration on hyperkalemia in tigers (*Panthera tigris*) and lions (*Panthera leo*) anesthetized with alpha-2 agonists. J Zoo Wildl Med. 2019;51 (3):490-496.

8. Miller M, Weber M, Neiffer D, Mangold B, Fontenot D, Stetter M. Anesthetic induction of captive tigers (*Panthera tigris*) using a medetomidine-ketamine combination. J Zoo Wildl Med. 2003;34(3):307-308.

9. Quigley KS, Armstrong DL, Miquelle DG, Goodrich JM, Quigley HB. Health evaluation of wild Siberian tigers (*Panthera tigris altaica*) and Amur leopards (*Panthera pardus orientalis*) in the Russian Far East. Proc Am Assoc Zoo Vet. 2001:179-182.

10. Reilly S, Seddighi MR, Steeil JC, Sura P, Whittemore JC, Gompf RE, Elliott SB, Ramsay EC. Selected clinical, biochemical, and electrolyte alterations in anesthetized captive tigers (*Panthera tigris*) and lions (*Panthera leo*). J Zoo Wildl Med. 2014;45(2):328-334.

11. Sontakke SD, Umapathy G, Shivaji S. Yohimbine antagonizes the anaesthetic effects of ketamine-xylazine in captive Indian wild felids. Vet Anaesth Analg. 2009;36(1):34-41.

12. Wenger S, Buss P, Joubert J, Steenkamp J, Shikwambana P, Hatt J-M. Evaluation of butorphanol, medetomidine and midazolam as a reversible narcotic combination in free-ranging African lions (*Panthera leo*). Vet Anaesth Analg. 2010;37(6):491-500.

Table 1. Immobilization and emergency drug dosages for lions, tigers and leopards.

Species	Agents	Reference
Lions, Tigers & Leopards	Medetomidine (20-30µg/kg) or Dexmedetomidine (10–15 µg/kg) & Midazolam (0.1mg/kg) & Ketamine (2.0-3.0mg/kg) i.m.	author's personal experience
Other dosages reported		
Amur tiger (snared)	Ketamine (10.8mg/kg) & Xylazine (0.81mg/kg) i.m.	3
Amur tiger & Amur leopards	Ketamine (6.6mg/kg) & Xylazine (0.66mg/kg) i.m.	9
Leopards (wild)	Ketamine (2.2-2.6mg/kg) & Xylazine (1.1-1.3mg/kg) i.m.	11
Reversal drugs		
Yohimbine	1.25mg/kg i.m. or s.c.	
Atipamezole	5mg/mg medetomidine or 10 mg/mg dexmedetomidine i.m.	
Emergency Drugs		
Doxapram	3 – 5mg/kg i.m. or i.v.	
Midazolam	0.1mg/kg i.v.	
Analgesic Drugs		
Meloxicam	0.1 – 0.2mg/kg s.c.(initially), then 0.1mg/kg p.o. q.24hrs	
Tramadol	1.0 – 2.0mg/kg p.o. b.i.d.	
Buprenorphine	0.03mg/kg s.c.	

Abstracts

WHM-1

OPTHALMIC EXAMINATION FOR REDUCED VISION IN A LEOPARD *(Panthera pardus)*

Ankur Sharma, S.Sood, H.R. Bhardwaj, A. Kumar, M. Singh and D.K. Dwivedi
Division of Veterinary Surgery and Radiology,
FVSc & AH, SKUAST-J, RS Pura, Jammu-181102
ankurvets@gmail.com

A two year old leopard *(Panthera pardus)* was presented to Teaching Veterinary Clinical complex, FVSc & AH, SKUAST-J, RS Pura, Jammu with the history of reduced vision while it was injured during capture by villagers from the hills of Udhampur region. Clinically, there were no visible injury marks on the animal, but it showed mild staggering while walking in the cage. The leopard (55 kgs approx.) was administered xylazine and ketamine anaesthesia. On clinical examination, the physiological parameters noted at various intervals and haemato-biochemical tests were within the normal range except neutrophillia with a shift to the left. Corneal cytology revealed normal epithelial cells and CST examination was carried out. Periocular and ocular structure of both eyes were symmetrical with transparent cornea and mild hazy anterior chamber. Palpebral reflex, PLR and dazzle reflex were normal on direct examination but anisocoria was observed on consensual PLR. Menace and maze tests could not be performed. STT, IOP readings were in the normal range and fluorescein dye test did not indicate any corneal defect. Direct ophthalmoscopy after mydriasis in dim light showed a positive tapetal reflex with visible retinal vessels. Ocular USG using 10MHz linear transducer showed mild hyperechoic anterior lens capsule in one eye. Sub-conjunctival injections, parenteral antibiotics and analgesics were advised which resulted in uneventful recovery.

WHM-2

HEALTH MONITORING AND FIELD ANESTHESIA OF GOLDEN JACKALS *(Canis aureus)*

Atul Gupta, Amol Rokde, Kajal Jadav and Madhvi Dherykar
School of Wildlife forensic & Health,
NDVSU, Jabalpur, MP
amolrokde@gmail.com

The golden jackal (*Canis aureus*) is a species under significant and fast geographic expansion. Various pathogens are known from golden jackals across their geographic range, and certain groups can be spread during their expansion, increasing the

risk of cross-infection with other carnivores or even humans. For health investigation of any meta-population in free range and captive situation, immobilization of wild carnivores is necessary. In the present study, nineteen free-ranging Indian jackals (*Canis aureus*) of Van Vihar National Park & Zoo were chemically immobilized with a combination of xylazine (2± 0.5mg/kg) and ketamine (6±2 mg/kg) by intra muscular injection. Induction and recovery times were also recorded. Pulse rate, respiratory rate, body temperature, systolic and diastolic blood pressures and oxygen saturation were measured. Anesthesia depth indicators were observed. The combinations provided safe and effective immobilization regime for 20–30 minutes. The observations made during immobilisation procedures in this work suggest that chemical immobilisation of Indian jackal with 6–8 mg kg ketamine and 2 mg kg xylazine were effective and safe for routine management and veterinary interventions. Blood and other biological samples were also collected for health investigation.

WHM-3

CLINICO-HAEMATOLOGICAL STUDY IN AILING PIGEONS (*Columbia livia)* OF NAGPUR CITY

Panchbhai C.G., Dhoot V.M., Bhojne G.R., Kalyani Thakur, Kriti Dohre and Sameeksha C.
Department of Clinical Medicine, Ethics and Jurisprudence,
Nagpur Veterinary College, Nagpur
checkpunch@rediffmail.com

In recent years a number of deaths of pigeons have been reported from different parts of the country, however causes have remained unknown. The present study was undertaken on the pigeons (*Columbia livia)* from different parts of Nagpur city. The data on area, number of birds infected, clinical symptoms, nature of infection, morbidity percentage was collected. The ailing birds were kept under observation and subjected to detail clinical investigation. Blood samples were collected from the wing vein. Blood smears and serum samples were collected and Hb percentage, PCV, DLC and TLC estimations were carried out. The overall haemoglobin in ailing pigeons was observed to be reduced significantly than that of normal pigeons. The significant reduction of the total erythrocyte count and increase in PCV of affected pigeons were observed. On differential leucocytes count the increase in eosinophil percentage observed which can be attributed to heavy parasitic infection.

WHM-4

ALVEOLAR BONE ABSCESS DUE TO THE BROKEN CANINE TOOTH IN A ROYAL BENGAL TIGER

Tripathi S. D.[1], Gaikwad R.V. and Khandekar G. S.
Department of Surgery and Radiology
Mumbai Veterinary College, MAFSU
savets@rediffmail.com

An adult Royal Bengal tiger of the Sanjay Gandhi National Park was reported with anorexia, listlessness and swelling of the muzzle. The animal was restrained in a squeeze cage and examined carefully. After careful examination it was decided to anaesthetize the animal and proceed ahead with oral examination and to rule out the initial suspicion of snake bite. The animal was anaesthetized with 1:1 combination of xylazine and ketamine and examined. On clinical examination it was noted that the canine tooth of the left maxilla was broken. The cavity formed was drained and a seton was applied. The tiger made an uneventful recovery. The details of the case will be discussed during the conference.

WHM-5

HAEMATOLOGICAL AND BIOCHEMICAL ANALYSIS OF BLOOD AND SERUM SAMPLES OF LIONS OF ALIPORE ZOOLOGICAL GARDEN, KOLKATA, WEST BENGAL

Sumit Chowdhury*, Uday Sankar Das[1] and Maloy Maity[2]
*BLDO Chanchal-1, Malda & Ex-Assistant Director, ARD, IAH&VB, Kolkata, ARD Dept., Govt of W.B., 1. Assistant Director, ARD, IAH&VB, Kolkata, ARD Deptt, Govt of W.B., 2. Joint Director, IAH&VB, Kolkata, ARD Deptt, Govt of W.B.

drsumit07@rediffmail.com

Routine analysis of blood and serum of zoo animal is utmost important for good health status of zoo animals. Present study was undertaken to analyze the hematological and biochemical parameters of seven numbers of lions of different ages from Alipore Zoological Garden, Kolkata. Total Protein (TP), Albumin(Alb), BUN, Creatinine, SGOT and SGPT parameters were tested from serum and Hemoglobin (Hb%), Total Leucocytes Count(TLC) and Differential Leucocytes Count (DLC) were test from blood of all ages of lions. Serum parameters of lions were total protein 6.28±0.30 g/dl , Albumin 3.30±0.20 g/dl, BUN 13.11-27.32 g/dl , Creatinine 1.05±1.82 g/dl, SGOT 16.56-49.87

IU/L and SGPT 19.56-28.23 IU/L. Blood parameters values were Hb% 14.96-18.05, TLC/µl 10950-15000, Neutrophil % -53-65, Eosinophil %-0-6 , Basophil%-0 , Lymphocyte%-28-34 and Monocyte %-3-7. However, one lion cub was showing higher value of SGOT 212 IU/L and BUN 109.12 g/dl. Further investigation is required to study more numbers of samples from lion of different species with their clinical sign and symptoms to establish a reference value for different ages and seasons.

WHM-6

A CASE OF PENILE FRACTURE AND PARTIAL AMPUTATION OF OS PENIS IN A SLOTH BEAR *(Melursus ursinus)*

Arun A Sha[1] and Adhithyan N.K[1]
[1]Wildlife Veterinary Officer, Wildlife SOS,
Bannerghatta Bear Rescue Centre, Bangalore 560083 - Karnataka.
arun@wildlifesos.org

Sloth bears possess an os penis like their wild canine relatives. It is believed to be an aid in their reproduction and mating success. The average length of the os penis in adult sloth bear is around 16 centimeters. Pathological and congenital affections of genitalia are uncommon in sloth bears, even though geriatric animals are likely to get posthitis and balanitis as their age advances.

A 25 year old male sloth bear housed at Bannerghatta bear rescue centre was showing signs of dysuria, followed by abnormal and excess mobility of penile tissue. Upon close examination, additional clinical abnormalities like crepitus and thickened fracture site was noticed. The plain radiography confirmed a simple, short, oblique fracture at the distal one third of os penis. A lacerated wound was noticed approximately 15 cms long, extending from base to tip of the prepuce. The bear was immobilized with Xylazine (2mg/kg), and Ketamine (5mg/kg) and partial amputation of os penis and wound reconstruction surgery was performed. The broken tip of the os penis was removed through a 20 mm incision made on the anterio dorsal part of the glans penis without interfering with urethral opening, the incision and extraction of os penis from the corpus spongeosum was performed using an electrocautery to minimize bleeding. The wound was sutured using 3-0 PGA and wound on the prepuce was sutured using a 2-0 PGA. Antibiotics and anti-inflammatory was given for 7 days along with supplementation of serratiopeptidase and vitamin B. The animal had an uneventful recovery.

WHM-7

THERAPEUTIC MANAGEMENT OF BULLAE IN CAPTIVE ASIAN ELEPHANTS *(Elephas maximus)*- A CASE REPORT

Rahul Prasad, Ilayaraja Selvaraj, Arun A. Sha, Pramod Rajput, Srinu S. Maharana
(Veterinary officer, Deputy Director of Veterinary Department, Director of Veterinary Department ,Veterinary Officer, Senior Research Associate)
rahul@wildlifesos.org

Diagnosis of bullae is an important treatment perspective in Asian elephants. We report here the clinical case of Bullae in rescued captive Asian elephant housed at Elephant conservation and care center, Mathura and its medical intervention. A 50 year old male Asian elephant showed symptoms of pain and fluid filled sac along with watery discharge from ear pinna. Later on it was tentatively diagnosed as bullae. The bullae were rinsed with normal saline solution and the residual fluids were seized with the help of sterile cotton swab. The elephant was treated topically with a mixture of Silver sulfadiazine, Calendula powder and coconut oil in a ratio of 2:1:1 twice a day for 45 days. Oral medication of Meloxicam @0.1mg/kg, Chlorphenamine meleate @0.5mg/kg were given for 25days and TRP bolus @4/SID until the recovery noticed. The treatment was found to be effective as the animal showed improvement after the course of treatment. The animal was completely recovered after 45 days of treatment.

WHM-8

THERAPEUTIC MANAGEMENT OF VENTRAL EDEMA IN ASIAN ELEPHANT *(Elephas maximus)* - A CASE REPORT

Rahul Prasad, Illayaraja Selvaraj, Arun A Shah, Shivani Sing
(Veterinary Officer, Deputy director of veterinary department, Director of veterinary department, Veterinary officer, Wildlifesos)
rahul@wildlifesos.org

Ventral edema may involve the ventral abdominal wall, the submandibular area, the tissues surrounding the external genitalia, edema associated with parasites, anemia, kidney failure, tuberculosis and chronic diarrhea. A single, specific, underlying etiology has not been identified. Edematous pockets can emerge in any of the respective areas of the elephant's body. Incidence of ventral edema noticed in rescued begging female elephant aged 64 years at Elephant Conservation and Care Center, Wildlife SOS, Mathura. The subcutaneous ventral edema usually exhibit in overnight at abdomen and ventral thoracic region. Animal had mild pain on while touching, walking, sitting and

when animal lay down. Applied herbal aerosol spray Wisprec (Eranda, Tulasi, Eucalyptus globules leaf oil topically as anti-inflammatory to reduce inflammation that assist to reduced edematous swelling, orally given Bol. Meloxicam @ 0.1 mg/kg B.Wt. to reduce pain and inflammation also and Tab. Chlorpherinamine maleate @ 0.5 mg/kg B.wt to prevent allergic reactions at morning around 9:00 am . Around 03:00 pm applied Epsom salt ($MgSO_4$) mixed with Glycerin and make thick adhesive paste and applied topically on ventral edema after that an elephant allowed to walk with mahout for approx. 2 km on premises. Same treatment follow up for next ten days. Reduction in ventral edema noticed from 4th day but complete recovery had been noticed in ten days.

WHM-9

MANAGEMENT OF INJURED SNAKES: INDIAN COBRAS, RAT SNAKE & ROCK PYTHON CLINICAL CASES

Sanjay J.Gaikwad
Regional Joint Commissioner of Animal Husbandry,
Aurangabad ,Maharashtra
sj66gaikwad@gmail.com

Injured snakes were brought to clinic. The treatment required surgical intervention. Thus, for inducing general anesthesia, Ketamine 20 mg/kg body weight was administered. The wounds were aseptically cleaned and the muscles were sutured with catgut and the skin with nylon. Inj. Streptopenicillin was sprinkled on the wound. The wounds were dressed as per the need of the patient. The various cases encountered are as follows:

1. An Indian Cobra had a lacerated wound on the thoracic region exposing skin, muscles, ribs and heart.

2. A second cobra had prolapsed hemipenes which were reduced and repositioned to the anatomical position and dressed.

3. In a rock python there was big wound exposing the trachea, esophagus, surrounding muscle and skin. These were sutured as per anatomical manner.

4. A rat snake had gotten entangled in a plastic bottle and was released by cutting the bottle neck and then the afflicted wound was sutured.

Regular cleaning and dressing was done with povidon iodine for one week. The stitches were removed after 20 days. There was marked recovery shown by all the snakes and they were released in the natural habitat by the forest department officials.

WHM-10

DETECTION OF SPIROMETROSIS IN CAPTIVE ASIATIC LIONS AND ITS SUCCESSFUL TREATMENT AT NANDANKANAN ZOOLOGICAL PARK

Santosh kumar Gupta[1], Sarat Kumar Sahu[2], Debabrat Mohapatra[2], Alok Kumar Das[2], Niranjan Sahoo[3], Bijayendranath Mohanty [4]and Shivani Soni[1]

1. Centre for Wildlife Health, College of Veterinary Science, Bhubaneswar, Odisha ,
2. Nandankanan Zoological Park cum Botanical garden, Bhubaneswar, Odisha
3. Department of Veterinary Epidemiology and Preventive Medicine, College of Veterinary Science, Bhubaneswar , Odisha, 4. Department of Veterinary Parasitology, College of Veterinary Science, Bhubaneswar , Odisha

santoshkumargupta@ymail.com

The present case report deals with detection of Spirometrosis in four captive male Asiatic lions (*Panthera leo persica*) of about 3 years of age weighing about 120 kg on an average at Nandankanan Zoological Park, Bhubaneswar, Odisha and its successful treatment using Praziquantel. The faecal samples were screened for routine deworming using qualitative (direct and concentration). Faecal sample showed operculated yellowish brown colored egg pointed at either egg suggestive of *Spirometra spp*. McMaster technique was conducted for EPG estimation on 0th (Pre-treatment) and 1st, 3rd, 7th, 14th, 28th, 60th and 90th (post treatment). EPG reduced from 22100 ± 1050, 17450 ± 444 (21%) , 5800 ± 561 (73.7%) and 0 (100%) on 0th , 1st , 3rd and 7th day onwards after treatment with Praziquantel @ 5 mg per kg body weight for three consecutive days. Neither adult segment nor eggs were detected up to 90th day post treatment. Molecular diagnosis for species confirmation could not be done due to non recovery of adult segments.

WHM-11

SURGICAL MANAGEMENT OF FISHING HOOK INGESTION IN INDIAN FLAP SHELL TURTLE

[1]M. R. Kate, [1]Syed Bilal Aliand [2]S. B. Akhare

[1]Veterinary Officer, Transit Treatment Centre, Nagpur Forest Division, Nagpur,
[2]Professor Department of Surgery and Radiology, Nagpur Veterinary College, Nagpur.
mayurkate.kate4@gmail.com

An adult male Indian flap shell turtle was diagnosed with foreign body obstruction of fishing hook. Upon presentation, fishing line protruding out from the oral cavity of the reptile was observed. Diagnosis of foreign body ingestion was based on

plain radiograph where the fishing hook was evidenced on ventrodorsal radiographic view. Surgical procedure was carried out under the general anesthesia using a combination of Ketamine- Midazolam @ 20 mg/kg and 1mg/kg respectively. Antibiotic, anti-inflammatory and parenteral fluid therapy was given pre and post-surgically as medical treatment and stabilization.

WHM-12

ACUTE RESPIRATORY DISTRESS SYNDROME (ARDS) IN CAPTIVE TIGER WITH TREATMENT AND MANAGEMENT

Sujay Suresh[1], Nikita Salian[3], Suresh Patel[2] , Ravi Raidurg[2] and Tista Joseph[3]

1. Veterinary Officer and incharge Assistant Director, Tiger and Lion Safari, Shimoga
2. Associate Professor, Dept of Medicine, Veterinary College Shimoga

   Associate Professor and Head of Department, Dept of Surgery and Radiology, Veterinary College Shimoga
3. PG Scholar, MVSc Wildlife, Veterinary College Hebbal, Bangalore
4. PG Scholar, MVSc Surgery, Nagpur Veterinary College, Nagpur

nikitasalian28@gmail.com

Tiger Wali (Male, aged 19 years) housed in Shimoga Tiger and Lion safari, Karnataka was displaying signs of acute respiratory distress syndrome(ARDS) with dyspnoea, blood-tinged mucoid nasal discharge, dull lung and heart sounds indicative of pleurisy along with thoraco-abdominal respiration. The animal was off-feed and displayed a temperature of 37^0C, paler mucosa and a dehydration status of around 10 percent. The animal displayed generalized weakness.

After a thorough examination and haemo-analysis which revealed leukocytosis ($21 * 10^9$/l) and decreased granulocytes ($0.96 * 10^9$/l). The animal was also tested for bovine tuberculosis, which was negative (Anigen-BTB Ab ELISA 2.0). Chest radiographs could not be conducted as: the animal was too weak for sedation, the zoo infrastructure did not at that time possess a radiography unit, also the animal could not be taken out in light of the recent COVID-19 lockdown.

The animal was treated with intra-venous hypertonic glucose elevators, amino-acids, multi-vitamins, antibiotics (Ceftrioxone tazobactum @ 20mg/kg), xanthines, fat emulsions and anti-inflammatory glucocorticoids for a course of two weeks. The tiger was also put under nebulisation with Asthalin (Salbutamol (2.5mg)), Duolin

(Levosalbutamol (1.25mg) + Ipratropium (500mcg)) and budacort (Budesonide (0.5mg)) respules along with oral electrolytes for the entire course of the treatment. The treatment was carried out in a squeeze cage.

The animal made an uneventful recovery with improvement in appetite and gradual improvement in respiration and lung and heart sounds with normalized leukocyte counts.

WHM-13

MAIDEN PREVALENCE REPORT OF GASTROINTESTINAL PARASITES WITH THE ASSESSMENT OF ANTHELMINTIC ACTIVITY OF ALBENDAZOLE BY FAECAL EGG REDUCTION TESTS IN WILD ANIMALS OF HARYANA

Hardeep Kalkal*, Ashish Chauhan, Sagar Kadyan and Sukhdeep Vohra
Department of Veterinary Parasitology,
Lala Lajpat Rai University of Veterinary and Animal Sciences, Hisar-125 004, India

kalkal12hardeep@gmail.com

Gastrointestinal parasitism (GIP) is one of the important causes of diarrhoea in captive wildlife. Due to the lack of systematic data on GIP in captive wild animals of Haryana, this study was conducted. Total of 268 faecal samples was collected from wild animals from three agro-climatic zones of Haryana. Viz. Deer Park Hisar (Zone-II) n=81 (DPH-II), Chinkara Breeding Centre Kairu, Bhiwani (Zone-III) n=50 (CBCKB- III), Mini Zoo Pipli, Kurukshetra (Zone-I) n =26 (MZPK- I), Mini Zoo, Bhiwani (Zone-III) n=75 (MZB-III) and Rohtak Zoo (Zone-II) n=36 (RZ-II). Samples were examined using parasitological techniques and data generated was statistically analyzed using IBM SPSS software (version 20). Faecal egg count reduction test was performed on Deer Park Hisar (Zone-II) only two groups were made Spotted deer (*Axis axis*) - AA and Blackbuck (*Antilope cervicapra*) - AC total 20 samples each were analysed pre-treatment and post-treatment. Deworming was done with albendazole @ 10mg/kg body weight through the feed. An overall prevalence of Strongyle eggs were 75% (202/268) in herbivores and omnivorous, Coccidia oocyst 47% (127/268) in herbivores, omnivorous and primates, Trichuris spp. 20% (54/268) in herbivores, Strongyloides spp. 13% (35/268) in herbivores and primates, *Toxascaris leonine* 4% (11/268) in carnivores, *Toxocara cati* 0.7% (2/268) in carnivores, Ancylostoma spp. 3% (7/268) in carnivores, *B. coli* 2.2% (6/268) in primates, Ascaris spp. 1.5% (4/268) in primates. No GIP was found in bear and crocodile. The highest prevalence of GIP in different zoos according to agro-climatic

zones are DPH-II and CBCKB- III 100% each followed by MZB-III, RZ-II, MZPK- I 83%, 78% and 77% respectively. The percentage reduction in faecal egg counts and mean egg per gram on 14th day in AA and AC was 96 (30±16) and 98% (10±10), respectively. The result indicates no resistance in AA and AC to albendazole in DPH-II. Systematic monitoring and efficacy/effect of drugs for GIP is needed for the proper prevention of health hazard and the development of resistance to drugs in wild animals.

WHM-14

DIAGNOSTIC IMAGING IN ZOO AND WILDLIFE MEDICINE

M. Hoque, A.C. Saxena, Rajesh Kumar and Akash
Division of Surgery,
ICAR-Indian Veterinary Research Institute-243 122 (UP)
mhoq61@yahoo.com

Application of various diagnostic modalities has revolutionized the disease diagnosis in wildlife medicine. Of which radiography and ultrasonography are gaining ground. Radiography has been the backbone in diagnostic imaging in the diagnosis of skeletal disorder and radiopaqe foreign bodies. The limitations are radiation hazards and in diagnosis of soft tissue sffections. With the introduction of portable ultrasound machine and growing interest of wildlife veterinarians in this arena, the imaging modality is gaining ground in wild life medicine. This modality has a wide scope for the study of visceral anatomy and physiology, reproductive biology and diagnosis of diseases/conditions in wild animals. Sonologists all over the world are working hard to develop a repository of data regarding normal sonographic features of different organs/structures in wide varieties of species. The modality is being used for better understanding of ovarian dynamics, embryo/fetal development that in turn has a direct bearing on successful breeding program. There are also reports of using this modality for early and precise diagnosis of various diseases/conditions in wildlife. It has several advantages over other diagnostic modalities. It is non-invasive, free from radiation hazards, provides instant diagnosis, and determines shape, size, location and internal consistency of a structure. Further, repetitive examinations can be done and it is well tolerated by the animals. The aim of this paper is to provide the basics of ultrasonography in wildlife medicine so that interested zoo and wildlife veterinarians of our country may explore the potential of this unique modality.

WHM-15

CASE REPORT OF ANAEMIC ORPHANED TIGER CUB

Khobragade, S. S., G.R. Bhojne, A. B. Motghare, S.S. Bawaskar and M.S. Bawaskar
Tadoba Andhari Tiger Reserve, Chandrapur
abhijeet.motghare@rediffmail.com

Orphaned male tiger cub were brought from the Khatoda round, Tadoba range, Tadoba Andhari Tiger Reserve (TATR) to Transit Treatment Centre (TTC), Chandrapur. Cub was in lateral recumbancy, severely dehydrated, anemic with heavy ticks on his body. Blood was collected for hematology. Blood report was showed Hb – 3.7 g/dl, SGOT- 287.0 U/L, SGPT-191.0 U/L and Total protein was 5 g/dl. Initially ticks were removed manually. Treatment was started with D 5% (250 ml, I/V), Ampicillin (500 gm, I/V), Doramectin (0.2 ml, S/C), Victofol (1 ml, I/M), Beplex (1 ml, I/M), was given with Hepamust (3 ml, orally), Tonoferon drop (5 drops, orally) and Sucralfet (3 ml, orally) for six days. After completion of treatment animal showed recovery with taking normal food.

WHM-16

A CASE OF SUCCESSFUL MANAGEMENT OF CLOACAL PROLAPSE IN TURTLE

L. R. Pawaskar, S. B. Harkal, N. P. Bhave, S. G. Deshmukh, M. V. Ingawale and C. H. Pawashe
Department of Animal Reproduction, Gynaecology and Obstetrics
Post Graduate Institute of Veterinary and Animal Science, Akola.
pawaskarlajari@gmail.com

A case of female turtle aged one year was presented to the Teaching Veterinary Clinical Complex, Post Graduate Institute of Veterinary and Animal Science, Akola with the history of cloacal prolapse since 15 hours. The turtle revealed symptoms of inappetance, reduced water intake and hyperemic prolapsed mass. On the basis of observation and clinical examination, the case was diagnosed as cloacal prolapse. For stabilization of turtle, Inj. Melonex, 0.2 mg/kg I/M, Inj. Intamox 5 mg/kg I/M and Neuroxin-M diluted in normal saline was administered orally. For the reduction of cloacal mass small ice packs were applied over prolapsed mass and mass was cleaned with normal saline. After reduction, Lignocaine jelly was applied over prolapsed mass and with the help of sterile ear bud prolapsed mass was repositioned inside abdomen of turtle. The purse string sutures were given around cloacal opening and antibiotic and analgesics were administered for successive four days. The sutures were removed after five days. The turtle showed healthy recovery without any reoccurrence. Turtle recovered successfully.

WHM-17

SPIROCERCOSIS IN A RESCUED MONITOR LIZARD AND ITS ENDOSCOPIC DIAGNOSIS AND MANAGEMENT

M.Veeraselvam, P.Selvaraj, S.Yogeshpriya, M.Saravanan, M.Venkatesan, K.Jayalakshmi, P.K.Ramkumar
and N.Premalatha
Exotic Animal Medicine Referral Clinic, Department of Veterinary Medicine,
Veterinary College and Research Institute, Orathanadu, Thanjavur - 614 625
drveeraselva@gmail.com

A rescued Monitor Lizard (*Varanus bengalensis*) was presented to the Exotic Animal Medicine Referral Clinic VCRI, Orathanadu with a history of rescue with injuries from a rural household. It had few wound in the tail. It was dull and reluctant to move. Tensed abdomen, copious salivation and nasal discharge were noticed. Vital parameters respiratory rate, heart rate, cloacal temperature was recorded. Blood samples collected through lateral tail vein. Faecal examination detected presence of embryonated eggs and larvae of *Spirocerca* sp. Electrocardiographic assessment did not reveal any abnormality. As it had tensed abdomen with copious salivation, gastro intestinal involvement was suspected and endoscopic assessment of digestive tract was planned. The lizard was medicated with Ketamine hydrochloride @ 44 mg/kg BW IM. It was placed in dorso-ventral position with the head and neck adequately restrained. An indigenous mouth guard was made and was placed in oral cavity to hold the mouth open for endoscopy. A thin flexible endoscopy (2.7 mm) was introduced through opening of the oesophagus and the stomach was assessed. Oral cavity and oesophagus were found to be normal, except for few hyperaemic spots. However in distal oesophagus a yellow longitudinal occlusion was observed and there was a oesophageal nodule. The case was confirmed as clinical Spirocerosis. Ivermectin @ 0.2 mg/kg SC was given once a week for two weeks. Fluid therapy with 40 ml of Dextrose Normal Saline SC was given twice a day. Oral B complex was given for 3 days, using feeding tubes. The lizard recovered uneventfully and later released.

WHM-18

SURGICAL MANAGEMENT OF PATAGIUM LACERATION IN BLUE ROCK PIGEONS *(Columba livia)*

Madhvee Dhairykar, Shobha Jawre, Nidhi Rajput, Sriram Guntoju and Arvind Kumar
School of Wildlife Forensic and Health,
NDVSU, Jabalpur (M.P.)
madhav.dhairya31@gmail.com

Every year, thousands of birds like pigeon, kites and some wild species of birds get injured by sharp, glass-coated manja. Two adult rock pigeons were referred to School of Wildlife Forensic and Health, NDVSU Jabalpur (M.P.) with the history of patagium laceration through glass-coated manja. The lacerated wounds were repaired by using Inj. Butorphanol@ 0.1 mg/kg, IM to provide pre-operative analgesia and Lignocaine hydrochloride were used as topical anaesthesia. Wounds were sutured by simple interrupted suturing pattern with 3-0 vicryl as suture material. Post-operatively antibiotic, supportive treatments and low level laser therapy were followed for 5 days. Both the pigeons recovered uneventfully with the restoration of good flying acuity and were released in the suitable natural habitat.

WHM-19

INTRAMEDULLARY PINNING FOR HUMERUS FRACTURE IN A HOUSE CROW *(Corvus splendens)*

Mayank Barde, Ushma Patel, Chetan Patond and Rohit Gangwal
Raksha, Jaipur
bardemayank97@gmail.com

A House crow (*Corvus splendens)* was brought at a Bird treatment camp, Raksha, Jaipur with left wing trauma, with Manja entangled around the wing. Clinical examination revealed swelling and bruising on the left wing with crepitating sound giving indication of fracture. Lateral radiograph of the affected wing revealed oblique distal humerus fracture and the fracture fixation was planned by intramedullary pinning. Preoperatively the bird was rehydrated with Ringers lactate @30 ml/kg body wt subcutaneously and stabalised by oxygen supplementation along with painkillers such as Tramadol @5 mg/kg and Meloxicam @0.5 mg/kg were given intramuscularly. The bird was induced by 5% Isoflourane and then intubated and then maintained at 1% Isoflorane. The surgical site was prepared prepared aseptically by plucking feathers and scrubbing with diluted Cholrhexidine solution. Intramedullary pinning was done in retrograde fashion using 2.5 mm titanium pin. Lateral radiograph of the left humerus was taken post

operatively to check the fracture allingment and found to be satisfactionary. The extra length of the pin was cut close to the skin and skin wound was closed by simple interrupted suture using Vicryl 3-0 and 8-figure bandaging along with body bandaging was done. Post operatively the bird was administered with antibiotic Enrofloxacin @ 15mg/kg orally once a day for 5 days along with analgesic Meloxicam @1 mg/kg orally for 3 days. The pin was removed and bird was released successfully on day 21st post operatively.

WHM-20

A CASE REPORT ON DIARRHOEA IN EMU

Motghare, A. B., S.S. Bawaskar, R.S. Khobragade and M.S. Bawaskar
Maharajbag Zoo, College of Agriculture, Nagpur
abhijeet.motghare@rediffmail.com

Emu of Maharajbag Zoo, College of Agriculture, Nagpur was showed lameness, greenish diarrhoea, temperature was 102.5^{0} F and appetite was normal. Treatment was started with injection Enroflox, injection Avil, injection Belamyl and injection Melonex for three days. Animal showed recovery sign of normal walking but greenish diarrhoea was continued. Same treatment was continued for next four days with tablet Liv 52. After seven days of treatment the animal recovered uneventfully with no diarrhoea.

WHM-21

A CASE REPORT ON DIARRHOEA IN OTTERS AT MAHARAJBAG ZOO, NAGPUR

Khobragade R.S., S.S. Bawaskar, A. B. Motghare and M.S.Bawaskar
Maharajbag Zoo, College of Agriculture, Nagpur
abhijeet.motghare@rediffmail.com

Otters play an important role in the aquatic ecosystem as top carnivores and thus influence the function of the ecosystem or fluvial ecosystem, they provide indication of the overall health of the aquatic ecosystem. Otters (1:1) were brought to Maharajbag zoo, College of Agriculture, Nagpur by forest department. In month of 19th August 2019 male otter went off feed, vomition and persistence watery diarrhea occurred. Treatment was started with syp. Ondem (5 ml, orally) and powder Gutwell (5 gm, orally). Ceftriaxone (2

ml, i/m) was given for five days with Perinorm (1 ml, i/m), Rantac (1 ml, i/m) and Griptol-N (2.5 ml, orally). After five days of treatment recovery sign passing of semisolid faecal. But vomition was continued and off feed. Then started Sucralfate (5 ml, orally), Belamyl (0.5 ml, i/m) and Gutwell (5 gm, orally) for next five days. After five days of treatment animal showed recovery sign of no vomition and taking small amount of feed. After 12 days of treatment animal showed complete recovery and started taking complete normal feed.

WHM-22

CHEMICAL IMMOBILIZATION OF BLUE BULL (*Boselaphus tragocamelus*)

Motghare, A. B., S.S. Bawaskar, R.S. Khobragade and M.S. Bawaskar
Maharajbag Zoo, College of Agriculture, Nagpur
abhijeet.motghare@rediffmail.com

The Maharajbag zoo has a stock of Blue bull (*Boselaphus tragocamelus*). They have been successfully bred and presently their number has increased. As it has become difficult to retain the entire herd of Blue bull with Black buck. It was decided to transfer a unit of 3 male and 3 female to another enclosure which is located about 300 meters away.

The translocation operation was planned on Monday as the zoo remains closed for the visitors. No food was offered to the herd since the previous evening. Out of 3 adult males the younger (approx. 200-250 kg) was selected for transfer and was darted on the quadriceps using 5 ml syringe. Xylazine (100 mg/ml) - 3 ml and Ketamine (100 mg/ml) - 2 ml was filled in the dart. The first sign of sedation with in coordination while walking and lowering of the head. As sedation become stronger, the animal knelt down, saliva drooling and the tongue protruded to outside. Lateral recumbancy was achieved after 15 minutes of darting. On close examination, the animal was found deeply sedated. The limbs were tied with cotton ropes and the animal was lifted on stretcher and brought out of the enclosure. The animal was transferred to a hand puller and rushed to the new enclosure. The animal was unloaded under the shade of a tree and examined for vital signs. The palpebral reflex was lost and the tongue was found dirty with soil. Cool water was sprayed over the body and the tongue was washed with clean water. Xylazine antagonist Yohimbine Hydrochloride (10 mg/ml) - 3 ml was injected in to the saphenous vein within 3-4 minutes the animal stand on his feet and ran away but stopped under the shade of another tree, where it sit again. All animals were also transferred in to the new enclosure in a similar manner.

WHM-23

MANAGEMENT OF LACERATED WOUND IN RAT SNAKE USING ISOFLURANE ANAESTHESIA

Pawar K.S., Thorat M.G., Raulkar R.V., Chepte S.D., Tayade K.N., Mitra A.A. and Jadhav A.A.
Department of Veterinary Surgery and Radiology
Post Graduate Institute of Veterinary and Animal Sciences, Akola, Maharashtra
kmlpawar.05@gmail.com

An Indian rat snake (*Ptyas mucosa*) approximately 6 feet length was rescued by local volunteer and presented at Teaching Veterinary Clinical Complex, Akola with lacerated wound on dorsal and ventral aspect towards the caudal end of the body. Wound was fresh with no apparent contamination. It was planned to undertake inhalant anaesthesia for restraining of snake. Snake was transferred into induction chamber and a crash induction was achieved by Isoflurane at the rate of 4% in combination with oxygen (2 L/min) via a semi closed circuit system with vaporizer until the snake reached surgical plane of anaesthesia. The depth of anaesthesia was estimated based on tongue movement, muscle tone, tail movement, righting reflex and pain perception. Although respiratory rate reduced to 2 breaths/min, no apnea was observed. Anaesthesia was maintained on 2% Isoflurane through a mask. The lacerated wound was cleaned and edges were sutured using 2-0 chromic catgut with horizontal mattress pattern. Post-operatively Inj. Enrofloxacin @ 5mg/kg I/M and Inj. Meloxicam @ 0.02 mg/kg I/M were administered for three consecutive days. Reptile was kept under observation and sutured wounds were disinfected with mild antiseptic solution for 5 days and later on it was released back to its natural habitat. This method of anesthesia proved to be safe in rat snake.

WHM-24

TRAUMATIC INJURY WITH DOG BITE IN A BLACK BUCK

Rajendra Kumar T and DT Naik
Department of Veterinary Pathology, Veterinary College, Bidar
drrajendra4428@gmail.com

The wild animals experience various forms of trauma and injury leading to shock and death. In the present study, a brownish Black Buck was presented for necropsy examination from the forest department of Bhalki taluk of Bidar District with a history of accidental trauma, dog bite and sudden death. The postmortem examination revealed, lacerated and punctured dog bite wounds adhered with clotted dark blood noticed on the

pelvis, left hindleg and thoracic vertebrae regin. On opening of the skin, the subcutaneous and muscular hemorrhagic effusions with hematoma formation were seen on the left front fore leg, hind leg and hip region. The rumen was filled with food material. The liver was congested and gall bladder was distended with bile. Both the kidneys were congested. Both the lungs were congested and emphysematous and on cutting through bronchi and bronchioles, hemorrhagic fluid and blood were oozed from the cut portion. The heart was congested and lumen was showed the clotted blood. The case morphologically diagnosed as traumatic injury with dog bite leading to hypovolemic shock and death.

WHM-25

SURGICAL MANAGEMENT OF GASTROINTESTINAL FOREIGN BODIES IN AN INDIAN POND TERRAPIN *(Melanochelys trijuga)*

Roopa Satish, Priyanka Nambiar, Vasudha AN, Sameeksha Reddy and Shashanka S
Wildlife Rescue and Rehabilitation Centre (WRRC), Bengaluru, Karnataka, India.
([1]Wildlife Veterinarian, [2-4]4th year BVSc & AH, KVAFSU, [5]2nd year BVSc & AH, KVAFSU, Bengaluru)
roopasatish01@gmail.com

An adult female Indian Pond Terrapin weighing 1.360 kg was presented with firm swelling in the right femoral region between plastron and carapace. She had been kept as a pet in a small tank with pebbles, grit as substrate prior to rescue. She was fed an incorrect diet of rice, wheat and vegetables, with no fish, basking time in sunlight or exercise. She developed the swelling gradually over a period of 2 months.

Radiographs confirmed the swelling to contain dense material. Surgery was performed after a week for stabilization of the patient. Fasting for 24 hours was done and surgery conducted using Ketamine @20 mg per kg body weight intramuscular. Induction took 20 minutes. A one inch skin incision on dorso lateral aspect of the swelling was made followed by an intestinal incision to reveal greenish tinged pebbles and grit inside. All the debris was gently removed and flushed with normal saline to reveal healthy intestinal mucosa below. There were no signs of infection. Slight finger probing was done to remove pebbles lodged further inside the intestines. The intestine incision was sutured using absorbable material Vicryl 3-0 in simple interrupted method and skin was sutured using non absorbable material Trulon 3-0 in mattress method. A pressure bandage was placed for a week.

Post operative care with Meloxicam injection @ 0.2 mg/kg sid for 5 days and long acting Enrofloxacin @ 5 mg/kg every 72 hours (5 injections) were given. Isotonic sterile fluids were given intracoelomic for first two days (20 ml). She was kept in a dry

clean vivarium for first week and as wound showed signs of healing and shifted to an enclosure with water, basking and hiding spaces and was fed fresh lake fish. The wound healed uneventfully, sutures were removed and she was released in the wild after two months of observation.

WHM-26

MANAGEMENT OF MANDIBULAR AND RADIO-ULNA FRACTURE IN FEMALE HYENA

Sanjay J.Gaikwad
Regional Joint Commissioner of Animal Husbandry, Aurangabad ,Maharashtra
sj66gaikwad@gmail.com

Female hyena was found limping and prostrate post an automobile accident. She was rescued by forest officials, Shahada Dist:- Nandurbar. On close examination right radio-ulna and mandibular fracture were observed. The patient was sedated and primary fixation of fracture was done by local veterinarian. The case was referred to Veterinary Polyclinic, Nasik. Anaesthetic used: Inj. Xylazine@ 1mg/kg and Inj.Ketamime mg/kg body weight. Post examination, wiring of right horizontal ramus was done. Plastering was done by using fiber cast. The hyena was looked after for 45-days by forest officials and an NGO. After complete weight bearing plaster cast was removed. The patient recovered uneventfully then was released in the same habitat from where she was rescued as per directions of forest officials.

WHM-27

MANAGEMENT OF MAGGOTIZED WOUND IN THE ORAL CAVITY OF INDIAN COBRA *(Naja naja)*

Sriram Guntoju, Shobha Jawre, Amol Rokhde, Nidhi Rajput, Devendra Podhade, Somesh Singh and Madhvee Dhairykar
School of Wild life Forensic and Health, NDVSU, Jabalpur (M.P)
sriramguntoju@gmail.com

An Indian cobra was presented to the S.W.F.H (School of wildlife forensic and health) by the rescue squad of Jabalpur with the history of bleeding from the mouth. On thorough clinical examination, it was found that oral cavity was packed with maggots. The cobra was physically retrained and 1% Lignocaine hydrochloride was applied as topical anaesthesia. Then turpentine oil was instilled followed by removal of all the maggots manually. Wound was cleaned with normal saline and povidone iodine followed

by application of Benzocaine gel .Injection Meloxicam and Enrofloxacin were administered I/M. Cobra was recovered and sent free in the wild by the rescue squad.

WHM-28

SURGICAL MANAGEMENT OF WOUND IN A FEMALE MACAQUE MONKEY - A CLINICAL CASE

Sanjay J.Gaikwad
Regional Joint Commissioner of Animal Husbandry, Aurangabad ,Maharashtra
sj66gaikwad@gmail.com

A macaque female and baby were rescued from a *madaari* and referred to the clinic .After tranquilizing using Inj. Ketamine 10mg /kg B.Wt. Clinical examination revealed a circular wound infested with maggots at neck region due to rope tied by handler. On sedation the rope was removed and the wound was washed and cleaned with antiseptic solution and dressed with antibiotic ointment. Parentarally antibiotics and tetanus toxide was given. Daily dressing was done for two weeks. After complete healing of wounds, both the mother and baby monkey were released in natural habitat by forest officials.

WHM-29

FRACTURE MANAGEMENT AND REPAIR WITH FIBERGLASS CAST IN DEER SPECIES

Sujay Suresh[1], Ravi Raidurg[2], Nikita Salian[4], Chandrashekar[3], Naveen[3] and Sameena Iza[5]
1. Veterinary Officer and incharge Assistant Director, Tiger and Lion Safari, Shimoga
2. Associate Professor and Head Of Department, Dept of Surgery and Radiology, Veterinary College Shimoga, 3. Assistant Professor, Dept of Surgery and Radiology, Veterinary College Shimoga, 4. PG Scholar, MVSc Wildlife, Veterinary College Hebbal, Bangalore , 5. Education Officer, Tiger and Lion Safari, Shimoga

nikitasalian28@gmail.com

Tiger and Lion Safari, Shimoga hosts a herbivore safari, where there are Sambar deer, Spotted deer and other herbivores. Infighting has been observed between the same species to assert dominance and as a result there can be injuries and fractures among the individuals.

An adult female Spotted deer and an adult male Sambar deer had shown signs of lameness and inability to bear weigh on the right hind-limb and left fore-limb respectively. These animals were sedated with Xylazine at 1 mg/kg and 2 mg/kg respectively and Ketamine at 2mg/kg for examination. On physical examination, Spotted deer revealed a simple complete fracture of right metatarsal and the Sambar deer revealed a compound fracture on dorsal aspect of the left metacarpal. Diagnostic facilities were not available in the zoo and transit to nearby human facility was stressful for the animals. Further, blood picture revealed slightly elevated WBC count, no other anomalies noted.

The fractured limbs of these animals were immobilized with Fibreglass cast (Alsocast®) following standard bandaging procedures and allowed to set. A window was made in the fiberglass cast of the sambar deer near the injury site for regular treatment. The cast was left for a period of two months for healing as there was no damage to the cast, leg or the gait of the animal. Upon removal of the fiberglass cast by electric plaster cutter post sedation the site had healed well and the animals could bear weight on the affected limbs with no further complications.

WHM-30

SAFE ANESTHESIA PROTOCOL FOLLOWED IN VARIOUS DEER SPECIES AT TIGER AND LION SAFARI, SHIMOGA

Sujay Suresh[1], Nikita Salian[4], Sameena Iza[5], Mukund Chandra[3] and Guru C[4].

Veterinary Officer and incharge Assistant Director, Tiger and Lion Safari, Shimoga, PG Scholar, MVSc Wildlife, Veterinary College Hebbal, Bangalore , Executive Director, Tiger and Lion Safari, Shimoga, Deputy Range Forest Officer, Tiger and Lion Safari, Shimoga Education Officer, Tiger and Lion Safari

nikitasalian28@gmail.com

Restrain and safe handling of deer in free range/ safari is always a challenging task for a veterinarian especially with the involvement of anesthesia. Sometimes animals have to be sedated for various treatment protocols with limited availability of anesthetic drug. In Shimoga various herbivores viz. Sambar deer, spotted deer, Hog deer, blackbuck and Nilgai were sedated for conditions involving fracture, wound management, translocation, isolation etc. They were sedated with Xylazine and Ketamine 100mg/ml concentration with various doses as mentioned in Table 1. Recovery was done with Yohimbine. Blood picture varied with case as they were sedated for various health reasons. General precautions taken during the procedure were an efficient tranquilizing team, portable SS 307 stretcher, nebulizer and oxygen apparatus with power backup, motorized cold water sprayer, immobilization projector and accessories, general and

specific medication kit, back up transport vehicle, rubber sheets, ropes and straps, vital monitoring units, anti bloat liquids, microchips and other small essentials. Post reversal the animals were monitored until complete recovery.

Table 1

Sl no	Animal	No of animals	Xylazine	Ketamine	Reversine	HR/ min	RR/ min	Temp ^{0} F	Remarks
						Average peak sedation			
1	Spotted deer	9	1 mg /kg	2 mg/kg	0.5 ml	50	75	102	Good
2	Sambar	5	2 mg/kg	2 mg/kg	3 ml	45	18	102	Good
3	Hog deer	4	2 mg/kg	2 mg/kg	0.2 ml	65	14	102	Good
4	Blackbuck	7	0.5 mg/kg	2.5 mg/kg	0.2 ml	85	95	103	Good
5	Nilgai	3	2.5 mg/kg	2 mg/kg	3 ml	75	58	104	Average

WHM-31

SUCCESSFUL LACERATED WOUND MANAGEMENT IN NILGAI (*Boselaphus tragocamelus)*: A CASE REPORT

V.V. Choutmal[1], G. S. Dalve[2], P.P. Deshmukh[3] and A. S. Kachare [4]
[1,3] B.V.Sc.& A.H. Final year, N V C, Nagpur., [2].Private Practioner, [4].Livestock Development Officer,Nivgha Bazar, Hadgaon, Nanded
vaibhavchoutmal789@gmail.com

A 1-year-old Nilai was presented at Veterinary Dispensary Grade -A Nivgha bazar. with history of lacerated wound on the nasal base area. Severe bleeding was present near about 4-5cm skin was cut by barbed wire of farm compound. Weight approximately 100-125 kg Wound was cleaned by normal saline. Decide to do suturing. Animal was stabilized by giving inj. RL 500ml iv slowly after that local anesthetic was administered Lignocaine2% the suturing was done by catgut no.1 in the pattern of simple interrupted suture. Dressing of wound is done with the povidone iodine. NSAID Inj. Meloxicam@ 0.2mg/kg BW, inj. Enrofloxacin @ 5mg/kg BW due to uncomfortable area animal was ran away towards the forest

WHM-32

MANAGEMENT OF STOMATITIS AND ULCERATIVE GLOSSITIS IN ENDANGERED LEOPARD *(Panthera pardus)*

Kolangath S.M., Dhoot V.M., Upadhye S.V., Pawshe M.D. and Shalini A.S.
Wildlife Research & Training Centre, Gorewada, MAFSU, Nagpur
brosujit@gmail.com

2-year-old male leopard was found to reject buffen offered at Gorewada Rescue Centre, Nagpur. On observation the male leopard showed signs of ropy salivation, anorexia and dullness. The leopard was examined after physical restraint in a squeeze cage. The examination revealed stomatitis and ulcerative glossitis. The temperature, urine and stools of the leopard were normal. The stools were examined for endoparasites; however, the stools were negative for endoparasites. The Complete Blood Check (CBC) and serum parameters were normal. Differential Leucocyte Count (DLC) revealed, neutrophilia and mild anaemia. The leopard was treated with oral dosage of Vitamin B complex and Vitamin C, oral lavage with tannic acid lidocaine combination gel and Glycerine thrice a day. The leopard was offered medication in hard boiled eggs and boneless chicken was offered once a day. In order to avoid summer stress, desert coolers were installed and temperatures were maintained at 28-30°C and relative humidity was always maintained at 60-70 % at all times. The treatment was continued for 10 days until complete resolution of oral lesions and normal appetite was noticed.

WHM-33

MICROSCOPIC STUDIES ON BLACK BUCK *(Antilope cervicapra)* HAIRS

Kolangath S.M., Upadhye S.V., Dhoot V.M., Pawshe M.D., Gawande A.P. and Shalini A.S.
Wildlife Research & Training Centre, Gorewada, MAFSU, Nagpur
brosujit@gmail.com

Guard hair samples were collected from black bucks brought for treatment or at post-mortem examination at Wildlife Research & Training Centre, Gorewada, Nagpur. The hairs were examined under light microscope and nail paint casting technique was used to study the morphometric features of the hairs. The hair samples were collected from rump, back, thigh, tail, abdomen and neck were collected as per the standard protocol. The hairs were examined under 400X magnification and the measurements of tip diameter, mid-shaft diameter, root length, root diameter, length of medulla, medulla pattern, length of cortex and cortex: medulla ratio was calculated for each hair type.

Based on the nail paint cast the cuticle pattern was studied. It was found that the hairs differed in the shape of the root, diameter, cortex: medulla ratio, scale pattern etc. The above findings have potential implications in species identification using hair morphology studies.

WHM-34

MANAGEMENT OF HEPATOZOON SP. INFECTION IN AN INDIAN JACKAL *(Canis aureus indicus)*

Kolangath S.M., Upadhye S.V., Dhoot V.M., Pawshe M.D. and Shalini A.S.
Wildlife Research & Training Centre, Gorewada, MAFSU, Nagpur
brosujit@gmail.com

An adult Indian Jackal (*Canis aureus indicus*) was brought for rehabilitation and care to Wildlife Research & Training Centre, Gorewada, Nagpur with a history of paraperesis. The jackal was unable to bear weight on the hindlimbs and had wounds on the pin bone, forelimbs and hindlimbs. During the routine blood examination, the blood picture indicated infection with HepatozoonSp, neutrophilia and anaemia. The Complete Blood Check (CBC) indicated Haemoglobin (Hb)Value of 7.2 gm/dl while serum biochemistry values were normal. The faecal examination indicated infection with Strongyloid Sp. Following which the jackal was dewormed with Doramectin. The Jackal was treated with oral Doxycycline @ 10 mg / Kg bd. Wt. OD for 45 days along with oral Iron and Folic acid supplements. The jackal also received B and C complex supplements. During the entire tenure of treatment, the jackal was provided boneless beef and liver. The blood smear examination was repeated twice every month. On day 60 the blood smear examination did not reveal any gametocytes in the neutrophils

WHM-35

DIAGNOSIS OF TRICHOMONIASIS FROM *Milvus migrans, Tyto alba* AND *Accipiter badius* SPECIES

S.S. Jadhav, B.I. Akhunji, V. Sanghvi and O. Kinjawadekar
Jivdaya Charitable Trust, Ahmedabad, Gujarat
drshashijadhav@gmail.com

Avian trichomoniasis is an emerging pathogen of wild birds in india. It is caused by ingestion of unicellular flagellate of different trichomonad species, mainly

Trchomonas gallinae. It is primarily found from upper respiratory tract of columbid and raptor species world-wide. This study was conducted for diagnosis of trichomoniasis from three different bird species *viz, Milvus migrans, Tyto alba* and*Accipiter badius*during November 2019 to November 2020 at Jivdaya Charitable Trust, Gujarat. A total of 770 birds, 720 *Milvus migrans,* 30 *Tyto alba* and20 *Accipiter badius* tested by wet mount and giemsa's staining by taking swabs from oral and upper respiratory tract. These birds were selected on the basis of clinical signs like anorexia, yellow caseous lesion attached to oral and also birds which had no visible injuries. Out of 770 birds, 270 *Milvus migrans* and 7 *Tyto alba and 5 Accipiter badius* turned positive by wet mount and giemsa's staining. According to severity of live trichomonad in wet mount, birds have been segregated as mild, moderate and severe trichomoniasis. As preventive measure, positive birds had kept in isolation from rest of the flock. In conclusion, raptors need to be diagnosed for trichomoniasis, as it is becoming serious concern for clinician and rehabilitation centre.

WHM-36

SURGICAL MANAGEMENT OF OLD PATAGIAL LACERATION IN JUVENILE PAINTED STORK (*Mycteria leucocephala*)

S.S. Jadhav, N.S. Purohit, S. Everett and V. Sanghvi
Jivdaya Charitable Trust, Ahmedabad, Gujarat
drshashijadhav@gmail.com

A juvenile painted stork (*Mycteria leucocephala***)** with a three to four day old patagial laceration on the left-wing due to a kite string was reported at Jivdaya Charitable Trust, Ahmedabad in January 2020. The bird weighed 2.212 kg with an average body condition. The stork was stabilized for two days with intravenous fluid at 3% of body weight, meloxicam at 0.1 mg/kg, enrofloxacin at 15 mg/kg and supportive multivitamins. On the third day, the lacerated wound was debrided and sutured under Isoflurane gas anesthesia and the wing was secured with figure 8 bandage. The suture line gave up after five days at propatagium and resutured again under the same gas anesthesia. Good healing of the wound was observed after ten days of resuturing. Postoperative care included daily follow-up with enrofloxacin for seven days and pain management with meloxicam for three days post-surgery. The bandage was changed on every alternate day for cleaning and dressing of the wound along with physiotherapy to the wing till complete healing. During post-operative care, the bird was monitored for its normal activity, behavior, and feeding with weight observations. The wound healed completely after thirty days and bird was kept in an open aviary to monitor the normal flight for

fifteen days. After which it was released back to its natural habitat to allow the individual to contribute to the wild population.

WHM-37

PRELIMINARY STUDY OF CROSS MATCHING OF BLOOD IN INDIAN SLOTH BEAR *(Melursus ursinus)*

Pushkar Banka, Adhithyan and Arun A Sha
Bannerghatta Bear Rescue Centre, Wildlife SOS, Bangalore
pushkarbanka@gmail.com

The transfusion of whole blood in sloth bears could provide cardiovascular support and maintains life in critical conditions but transfusion of incompatible blood can lead to fatal reactions. Hence, cross matching of donor and recipient's blood becomes paramount prior to any transfusions. Though transfusion medicine in veterinary science has grown up a lot and practiced well, it is not so common in wildlife practice. Since donor and recipient compatibility needs to be established prior to transfusion, it possesses practical difficulties and challenges to collect blood and cross match them. In order to confirm the same, a technique is being established to allow cross matching of red blood cells and serum in sloth bears. Cross matching was carried out in 14 individuals. Operant conditioning technique was used to collect blood samples from all these individuals. For the major cross matching, few drops of washed red blood cells of the donor were added to a few drops of recipient serum. And for minor cross matching few drops of recipient's washed red blood cells were added to donor's serum. After incubation and centrifugation, the samples were evaluated for presence of macroscopic or microscopic haemolysis or agglutination. Samples showed no agglutination or haemolysis, macroscopically suggesting that donor and recipient would be compatible. But mild clumping of Red Blood Cells under microscope suggested chances of incompatibility. Hence, cross matching should be carried out in sloth bears prior to any blood transfusion and further studies are needed in related areas.

WHM-38

AMPUTATION OF GANGRENOUS TAIL IN GRAY LANGUR (*Semnopithecus hypoleucos)*

Akash[*], Mamta Mishra[*], Mohar Singh[*], Rajesh Kumar[*] and M. Hoque[**]
Division of Surgery, Indian Veterinary Research Institute, Izatnagar, Bareilly, Uttar Pradesh
[*]Ph.D Scholar, [**]Principal Scientist
anant.akash9@gmail.com

An Indian Gray Langur of about 1.5 yrs of age was presented to referral Veterinary Polyclinic of Indian Veterinary Research Institute Bareilly with the history of trauma at the base of tail. Wound was smelly having lot of dirt and loss of sensation. It was decided to amputate the

gangrenous tail from the base. Animal was premedicated with atropine sulphate @ 0.04 mg/kg body weight I/M. After 10 minutes animal was sedated with xylazine @ 0.6 mg/kg body weight I/M. Induction was done with ketamine @ 7mg/kg body weight I/M. Anaesthesia was maintained with ketamine hydrochloride. Standard monitoring techniques were applied to maintain cardiovascular homeostasis and core body temperature. After the tail amputation the recovery was smooth. Postoperative antibiotics and analgesics were advised for 5 days.

WHM-39

PATHOLOGY OF NON-HUMAN PRIMATE (NHP) MORTALITIES IN KFD ENDEMIC AREAS OF WESTERN GHATS IN SHIMOGA, KARNATAKA

Kavitha Rani B.*, Manjunatha SS[1], Sundareshan S[2], Madhavaprasad C B[3], Jayaramu GM[4], Pradeep B S[5], Kiran HJ[6], Satish ES[7], Sunil Kumar B S[8], Amit H[9]
Department of Veterinary Pathology, Veterinary College, Karnataka Veterinary Animal and Fisheries Sciences University (Bidar), Shimoga, Karnataka, India.
*Associate Professor, Dept of Veterinary Pathology, 1 and 6 Assistant Professor, Dept of Veterinary Pathology, 2 Assistant Professor, Dept. of Veterinary Microbiology, 3 Professor and Head, Dept of Veterinary Epidemiology, 4 Professor and Head, Dept of Veterinary Pathology, 5 Assistant Professor, Dept. of Veterinary Parasitology, 7,8,9 Post Graduate students, Dept of Veterinary Pathology
krnvet@gmail.com

Monkeys of South India endemic to Western Ghats in Karnataka are mainly *Macaca radiata* (Bonnet monkeys) and *Semnopithecus entellus* (Hanuman Langur). Review of literature on widely publicized monkey disease, Kyasanur Forest Disease, has highlighted the monkeys in transmission of the disease to humans with themselves being susceptible to clinical KFD. Hence, for practical purposes, monkey mortalities wherever reported is assumed to herald KFD in declared endemic areas in Karnataka. But, the present studies on NHP mortalities show that they do suffer from other ailments, other than KFD. Monkeys are usually spotted in morbid condition showing disorientation, circling, ataxia or falling from trees followed by death. Common pathological findings were haemorrhages and congestion in liver, kidneys, brain, lungs and Interstitial nephritis, Pneumonia, Chronic hepatitis, Portal hepatitis, splenomegaly and splenic congestion. Heart failure cells were commonly observed in several cases in lungs especially around the capillaries. Kidneys showed glomerular and medullary congestion, glomerulopathy and interstitial nephritis in several cases. One of the cases showed nephropathy due to oxalosis with prominent birefringence, tubular degeneration and necrosis. Few cases also showed infighting/ biting with subsequent gangrenous changes. *Streptococcal* and *E.coli* infections, eggs of Ascaridia and Ancylostoma were detected from cases with enteric pathology. These cases were found negative for KFD.

WHM-40

PATHOLOGY OF OXALOSIS IN A BONNET MONKEY – A CASE REPORT

Kavitha Rani B.*, Manjunatha SS[1], Jayaramu GM[2], Kiran HJ[3], Satish E S[4], Amit H[5], Sunil Kumar B S[6]
Department of Veterinary Pathology,
Veterinary College, Karnataka Veterinary Animal and Fisheries Sciences University (Bidar), Shimoga, Karnataka, India.
*Associate Professor, Dept of Veterinary Pathology, 1 and 3 Assistant Professor, Dept of Veterinary Pathology, 2 Professor and Head, Dept of Veterinary Pathology, 4,5,6 Post Graduate students, Dept of Veterinary Pathology
krnvet@gmail.com

Oxalosis is a pathological condition which causes nephropathy and nephritic lesions which can be fatal. In one of the necropsy investigations into pathology of monkey mortality, gross and histopathological studies were undertaken. In Sharavati river backwaters of Sagara taluk, Shimoga district, a KFD endemic area, the monkey had died after being ill, spotted by forest guards, observed for almost one day exhibiting signs of disorientation, dullness before falling from the tree. The gross pathology revealed incised wounds on the face and oral cavity with haemorrhages. The liver showed congestive and fatty changes, intestines with semi-solid catarrhal contents, kidneys with medullary congestion and enlargement with grossly pale yellow visceral fat, splenomegaly, cardiac dilatation, pulmonary congestion. Histopathology of kidneys showed irregular grey glassy deposits in the tubules, diffuse in nature. Observation under polarized light showed birefringence with glassy crystalline irregular material occupying the tubules along with necrotic areas, indicative of oxalate deposition. Extensive interstitial and tubular nephrosis were observed indicating kidney damage.

WHM-41

SURGICAL MANAGEMENT OF MANDIBULAR FRACTURE IN A CROW *(Corvus splendens)* AND A POND HERON *(Ardeola)* - A CASE REPORTS

Ushma Patel, S. V. Upadhye, S. B. Akhare, Gauri Khante and P. T. Jadhao
Department of Veterinary Surgery and Radiology, Nagpur Veterinary College, Nagpur
drushmapatel11@gmail.com

Two different species of birds were presented with mandibular fracture. The pond heron *(Ardeola)* had an unilateral complete fracture of right ramus of

mandible while the crow *(Corvus splendens)* was presented with a complete bilateral mandibular fracture. Both cases were decided to be operated with external rigid fixation using stainless steel plates. Isoflurane was used as general anesthesia for induction as well as maintenance to carry out the external fixation of the beak by using stainless steel reconstruction bone plates for the pond heron; and Injectable general anesthesia i.e. combination of Ketamine and Diazepam (2:1) was used for the crow. In both the cases, the beaks were immobilized by two plates from medial and lateral aspect of each fractured mandible. The birds were sustained on tube feeding technique and avian critical care formula for three days. Thereafter they were allowed their normal feeding habit. The post operative antibiotics (Enrofloxacin @ 15mg/kg body weight IM) and analgesics (Meloxicam @ 0.1mg/kg body weight IM) were continued for five days. The plates were removed after a month after restoration of complete function and also had an aesthetic look. Both the birds were released back into the wild successfully.

WHM-42

SUCCESSFUL MANAGEMENT OF BILATERAL METACARPAL FRACTURE IN *Antilope cervicapra*

A.A. Jadhav, M.G. Thorat, R.V. Raulkar, A.A. Mitra, K.S. Pawar, K.N. Tayade
Department of Veterinary Surgery and Radiology
Post Graduate Institute of Veterinary and Animal Sciences, Akola, Maharashtra
ameya0612@gmail.com

A sub-adult male blackbuck *(Antilope cervicapra)* was rescued by RFO and presented to TVCC, PGIVAS, Akola with the history of automobile accident a day ago. On presentation, the animal was recumbent, unable to stand and lethargic. Clinical examination revealed small lacerated wound below carpal joint at anterior aspect on both the forelimbs, with abnormal deviation of left forelimb from the wounded region. On palpation fracture was tentatively diagnosed on both left and right forelimbs. Radiographic examination confirmed compound complete transverse fracture at proximal 1/3rd of left metacarpal bone and compound complete oblique fractures at proximal and distal shaft of right metacarpal bone. The animal was stabilized by intravenous administration of Inj.Dexamethasone@ 2mg/kg BW, Inj.Ringer's Lactate 100ml, Inj.DNS 150ml, Inj.Amoxicillin@ 10mg/kg BW, Inj.Flunixin meglumine@ 1mg/kg BW and intramuscularly Inj.Chlorpheniramine maleate@ 0.5 mg/kg. The wounds were cleaned and dressed with 5% w/v Povidone-Iodine solution. The fractured fragments were reduced and aligned under ring block anaesthesia with 2% Lignocaine hydrochloride. The limbs were immobilized by external coaptation method with plaster

of paris (POP) cast by leaving sufficient window at anterior aspect over wound for antiseptic dressing. The animal was shifted to local rescue centre, where anti-biotic, anti-inflammatory, anti-histaminic and fluid therapy was undertaken for 5 consecutive days and dressing was continued till the wound healed completely. The plaster cast was removed on 45th day after confirming radiographic union of the metacarpal bones. The blackbuck recovered uneventfully in due course of time.

WHM-43

THERAPEUTIC MANAGEMENT OF RESCUED LEOPARD CUB

A.A. Mitra, M.G. Thorat, R.V. Raulkar, A.A. Jadhav, K.S. Pawar, K.N. Tayade
Department of Veterinary Surgery and Radiology
Post Graduate Institute of Veterinary and Animal Sciences, Akola, Maharashtra
ayanikamitra22@gmail.com

Leopards (*Panthera pardus*) are extremely adaptable to various ecological conditions. In recent years due to habitat fragmentation, leopards have started living in close proximity to humans in rural areas giving rise to conflicts, thus endangering them. A two months old leopard cub was rescued by RFO and presented to TVCC, PGIVAS Akola which fell into a well and was stuck there for 3 days. The cub was severely dehydrated, emaciated, recumbent with few lacerated wound on the body. On clinical examination, the heart rate and respiration rates were in normal physiological range but the rectal temperature was sub-normal. On the basis of clinical signs exhibited, the cub was stabilised and treated for shock and dehydration. The cub was properly restrained and covered with warm blankets till the temperature returned within normal range. Fluid therapy was undertaken by providing warm fluids Inj. DNS-50 ml subcutaneously, Inj. Dextrose 25%-5 ml, Inj. Ringer's Lactate-200ml and Inj. Tribivet- 1ml intravenously and Inj. Prednisolone@ 0.5mg/kg B.W intramuscularly. The dressing of the lacerated wounds was carried out with 5% povidine iodine solution. This treatment was undertaken for 3 consecutive days till the cub became active and started to have food. The cub was released into the forest after 5 days as it regained its strength and agility.

WHM-44

DEATH DUE TO PULMONARY TUBERCULOSIS IN A BLACK BEAR

Sanjiv Kumar*, Deepak Kumar, GD Singh[1] and Ramesh Tiwary[1]
Department of Veterinary Pathology and Surgery[2], Bihar Veterinary College, Patna
mrsanvet@rediffmail.com

An adult black bear maintained under captivity died showing weakness, loss of appetite, fluctuating fever and hacking cough. The animal was necropsied for ascertaining the cause of death. The body was in fair condition however the visible mucous membrane appeared whitish. Systemic examination revealed marked pathological changes in the lungs which was characterized by presence tan firm nodules of varying diameter disseminated throughout the pulmonary parenchyma with areas of pin point haemorrhages. The nearby lymph nodes were mildly enlarged. Cut surface the lungs showed multiple nodules with a necrotic caseative core. Heart epicardium showed extensive local haemorrhages. There was also mild enlargement and haemorrhages over spleen. Impression smear and sample for culture were taken from lung cut surface. Tissue pieces were collected in 10% formalin for histopathological assessment. Stained smear with Ziehl-Neelsen stain revealed typical acid fast bacilli under microscope. Histopathopathological examination of lung tissue stained by H & E stain showed typical multiple tuberculoid granulomas with central necrosis surrounded by epithelioid macrophages and multinucleated Langhans giant cells admixed with few lymphocytes. Some granulomas were located within the walls of bronchiole. Based on these findings, a presumptive diagnosis of a pulmonary mycobacteriosis caused by organisms of the *M. tuberculosis* complex was made. *Mycobacterium tuberculosis*, *M. bovis*, or other members of the *M. tuberculosis* complex affects a broad range of mammal hosts. Although natural susceptibility to infection may vary among humans and animals, interspecies transmission is not uncommon, especially in captive wildlife populations in which multi-host TB outbreaks have been reported.

WHM-45

CONSERVATIVE TREATMENT OF THORACOLUMBAR SPINAL INJURY IN A MALE LEOPARD (*Panthera pardus*)

Vanishree[1], Sujay CS[2] and Nikita Salian[2]
1. Veterinary Officer, Sri Atal Bihari Vajpayee Zoological Park, Kamalapur, Hospet,Karnataka.
2. Veterinary Officer and incharge Assistant Director, Tiger and Lion Safari, Shimoga.
3. PG Scholar, MVSc Wildlife, Veterinary College Hebbal, Bangalore
vanihiremath44@gmail.com

This case report presents repeated spinal trauma in a 3 year old male leopard at Kamalapur zoo and its conservative treatment. The leopard had limping of left hind limb

and weakness in both hind limb after falling from a height. Treatment with injectable Meloxicam and confinement in the holding room for fortnight, to restrict the movement, resulted in good improvement and the animal was subsequently released with the group. After four months, the leopard showed sudden weakness in hind limbs with dragging, reduced ambulation and sings of pain. Tail was held high to balance the body. Urination and defecation was normal. Treatment was initiated with oral Carprofen 2mg/kg body weight and syrup Neurobion-forte along with restricted movement. In few days, there was deterioration in general body condition and atrophy of spinal muscles. Prominent visibility of vertebrae and kyphosis at thoracolumbar junction was evident. It was tranquilized with Xylazine and Ketamine at 2:3 ratio for spinal radiography, which revealed healing fracture at T13 and L1 with bridging callus formation. Treatment with oral Carprofen was continued for 10 days and syrup Neurobion-forte administered for a month. Meantime, the leopard was confined to holding room and soft bedding was provided to prevent pressure sore. Providing of sand bedding was found to be beneficial as the leopard was able to stand and ambulate better when compared to hay bedding. There was marked improvement and by the end of one month the leopard was able to ambulate with mild ataxia and the tail movement was normal.

WHM-46

AVIAN POX: A WIDESPREAD INFECTIOUS VIRAL DISEASE OF BIRDS

Akriti Ballabh
College of Veterinary & Animal Sciences, G.B. Pant University of Agriculture and Technology, Pantnagar-263145
akritibs161241@gmail.com

Avian pox, a viral disease, caused by one of the larger viruses of the poxvirus group. This is slow-developing disease characterized by discrete, proliferative lesions on the skin of the toes, legs, or head, and/or mucous membranes of the mouth and upper respiratory tract. In most cases, the bird survives and the nodules heal with some scarring. The eye nodules interfere the vision ability to see food or predators and can lead to death. In severe cases, birds may develop necrotic, yellow-white, cheese-like lesions in their mouths and upper respiratory tract, known as diphtheritic form of the disease which lead to decreased food intake, difficulty in breathing, and ultimately death. Avian pox infections in wild birds are often mild and self-limiting, some outbreaks cause high mortality rates. The disease has transmitted through biting insects such as mosquitoes,

mites, fleas, midges, and flies are most frequently responsible for transmitting avian pox. Captive birds may be treated by sterilizing the lesions and bathing the affected areas with diluted iodine. It is not recommended to try to remove these lesions. Broad-spectrum antibiotics may be given to prevent secondary bacterial infections. These methods will not eliminate the virus, and the disease will run its course with or without treatment. No treatment is available for free-ranging species. The Avian pox can be managed through preventing disease transmission achieved by mosquito control and elimination of breeding sites of poxvirus transmission along with removal of severely infected birds.

WHM-47

MANAGEMENT OF PYODERMA IN A SLOTH BEAR

Shalini A.S., Dhoot V.M., Upadhye S.V., Gawande A.P., Pawshe M.D. and Kolangath S.M.
Wildlife Research and Training Centre, Gorewada , Nagpur
a.sshalini@yahoo.com

A male sloth bear about 4.5 yrs was brought from Bramhapuri, Chandrapur (Dist.) to Wildlife Research and Training Centre, Gorewada, Nagpur with the history of injury at the abdominal region. On Clinical examination, it was found that the animal had intensepruritus, diffuse alopecia, purulent and foul smelling discharge with slugging of skin at the ventral side of the abdomen. Evaluation of skin scrapping revealed that it was negative for mange prasites and skin impression smear was found to be negative for yeast infection. Haematological examination was done and it was found that there was neutrophilia along with leukocytosis. Serum Biochemistry (BUN, Cr, Total protein, albumin, Globulin, SGOT, SGPT, ALP) was within normal range. On the basis of clinical, haemato-biochemical and skin scrapping examination, it was confirmed to be a case of pyoderma. The animals were treated with Inj. Intamox 1gm, Inj. Vetalgin and Inj. Avil given intramuscularly for a period of 7 days along with Tab. Bcozyme C forte given perorally for a period of 30 days. Also, dressing of ventral abdomen was done by spraying povidine iodine. The Sloth Bear made an uneventful recovery.

WHM-48

MANAGEMENT OF WOUND AT THE BASE OF EAR PINNA IN A SLOTH BEAR CUB

Shalini A.S., Upadhye S.V., Pawshe M.D, Kalyani Thakur and Kolangath S.M.
Wildlife Research and Training Centre, Gorewada , Nagpur
a.sshalini@yahoo.com

A one month old orphan Sloth bear cub, male weighing 4 kg was brought from Kinvat, Nanded (Dist.) with the history of injury at the base of ear pinna. Clinical examination revealed old injury at the base of right ear pinnae, ulcerated with loss of structure and no visibility of ear canal. Physical examination revealed that there was no other injury on the body. The area was clipped, shaved and cleaned. Dressing was done with povidine iodine for a period of 12 days. The sloth bear cub made an uneventful recovery.

WHM-49

TREATMENT OF WOUND AT THE METATARSAL REGION IN AN ADULT FEMALE BLUE BULL

Shalini A.S., Pawshe M.D, Badane B.K., Upadhye S.V., Dhoot V.M and S.M. Kolangath
Wildlife Research and Training Centre, Gorewada , Nagpur
a.sshalini@yahoo.com

An adult female Bull bull at the Gorewada Rescue Centre was found to be limping from left hind limb. Physical examination revealed deep injury at the medial aspect of metatarsal bone of the left hind limb with exposure of metarasal bone. The animal was treated with Inj. Clavam 1.2g (600mg each), Inj. Melonex 3.5 ml and Inj. Neuroxin 4 ml given intramuscularly for 3 days followed by Tab. Mox-Clav 1.25g (625mg each) for 5 days. Daily dressing of wound was done by removal of necrosed tissue, cleaning it with Normal Saline mixed with Betadine, Calendula powder and D Mag Spray was applied and bandaging was done for 21 days. The wound was completely healed and the animal made uneventful recovery.

WHM-50

SUCCESSFUL HAND REARING OF FOUR LEOPARD CUBS

Shalini A.S., Pawshe M.D., Dhoot V.M., Upadhye S.V. and S.M. Kolangath
Wildlife Research and Training Centre, Gorewada , Nagpur
a.sshalini@yahoo.com

Four orphan leopard cubs viz. two male and two female of a single litter brought from Patur, Akola (Dist.), about one month age, weighing of 1.005 kg, 0.875 kg, 0.740 kg and 0.854 kg respectively were successful hand reared at Wildlife Research and Training Centre, Nagpur. The feeding of cub was done under strict sterilization of feeding bottles and utensils. Commonly recommended feed such as goat milk, boiled chicken and beef along with calcium and multivitamin supplements were given in gradually increasing portions as per the need. The feed requirement and growth rate is reported.

WHM-51

HYPOTHERMIA IN A SUBADULT NILGAI - A CASE REPORT

Shalini A.S., Pawshe M.D, Upadhye S.V., S.M. Kolangath and Kriti Dohre
Wildlife Research and Training Centre, Gorewada , Nagpur
a.sshalini@yahoo.com

A one year old Nilgai calf at Gorewada Rescue Centre, Nagpur was found to be in lateral recumbency , shivering at the early morning hours. Clinical examination revealed the animal had submormal temperaturewith cold extremities, mucous membrane was moderately pale, capillary refill time was prolonged with tachycardia. The animal was provided with the room heaters and lukewarm fluids (Inj. Ringers lactate and Inj. Dextrose 5%), Inj. Dexona and Inj. Intamox was parentally administered. The animal recovered immediately after the treatment.

WHM-52

SUCCESSFUL MANAGEMENT OF HEPATOZOONOSIS IN A SUBADULT MALE TIGER *(Panthera tigris)*

Dhoot V.M., Shalini A.S., Kolte S.W., Pawshe M.D, Upadhye, S.V. and Kolangath S.M.
Wildlife Research and Training Centre, Gorewada , Nagpur
a.sshalini@yahoo.com

A male tiger of 9 month age from Khutwanda Beat, Katoda round, Tadoba range, TATR core with the history of severe tick infestation, anemia and debility was brought to

Wildlife Research and Training Centre, Gorewada, Nagpur with the signs of distension of the abdomen and stunted growth. Physical examination was done and all the vital parameters viz. HR, RR, Temperature etc. were within normal ranges. Haematology revealed monocytosis with severe leukocytosis. Some Sero-biochemical parameters were at higher side. On the basis of hematology and blood smear examination, it was confirmed to be case of hepatozoan infection. The tiger was successfully treated with Inj. Oxytetracycline in Normal saline given intravenously along with Tab. Silybon for 30 days. The tiger had an uneventful recovery.

WHM-53

SUCCESSFUL HAND REARING OF SLOTH BEAR CUB

Shalini A.S., Dhoot V.M., Upadhye S.V., Gawande A.P., Kolangath S.M. and Pawshe M.D.
Wildlife Research and Training Centre, Gorewada, Nagpur
a.sshalini@yahoo.com

An Orphan sloth bear cub, female of about 2 month age was received from Bhandara (Dist.). The cub was fed with cow milk, fruits, eggs, sweetened wheat porridge, honey and fish were given in gradually increasing proportions as per the need. Deworming and Vacccination was done at regular interval.Calcium and multivitamin supplements were given as per the need. The food requirement and growth rate is reported.

WHM-54

SURGICAL CORRECTION OF DEEP LACERATED WOUNDS IN AN INDIAN ROCK PYTHON *(Python molarsus)*

Reji Varghese[1], Laiju M. Philip[1], Praveen M. K[2]., Sharat Joshi[2]., Lavanya,B[2]. and Syam K. Venugopal[3]
[1] Assistant Professor, [2] MVSc scholar Department of Veterinary Surgery and Radiology,College of Veterinary and Animal Sciences, Mannuthy, Thrissur, Kerala, [3]Professor and Head, University Veterinary Hospital, Kokkalai, Kerala Veterinary and Animal Sciences University
praveen.mk6969@gmail.com

An Indian Rock Python (*Python molurus)* rescued by Kerala Forest and Wildlife Department was presented to UVH Kokkalai with two deep lacerated wounds over the dorsum in proximal third of the body, caused by a grass cutter. On clinical examination, the snake was found active and alert. Physical, radiographic and ultrasonographic

examinations ruled out injury to visceral organs. The snake was controlled manually on the table and lignocaine HCl 2% was infiltrated around the wound edges. The wound was cleaned with sterile normal saline solution and edges were debrided. Damaged muscles were sutured by Polyglactin 910 size 0 in simple interrupted suture pattern. Skin edges were also apposed in the same way. The wound was dressed with 5% povidone iodine solution, padded and bandaged. The snake was kept under observation with the forest department for a period of ten days. The snake had an uneventful recovery with a reasonable healing of woundand was left to wild on tenth post-operative day.

WHM-55

RETROSPECTIVE STUDY OF ANAESTHETIC MANAGEMENT OF SNAKES AT TRANSIT TREATMENT CENTRE

[1]Syed Bilal Ali, Mayur R. Kate and [2]Prabhu Nath Shukla
[1]Veterinary Officer, Transit Treatment Centre, Nagpur Forest Division, Nagpur, ,
[2]Deputy Conservator of Forests, Nagpur Forest Division, Nagpur.
drsyedbilalali086@gmail.com

During the year 2019-2020 total 243 rescued snakes were presented at transit treatment centre. Out of the total snakes presented, 20 snakes needed anaesthesia for different treatment protocol which included lacerations due to barbed wires, vehicle ran over body part, tearing by sharp objects while rescue, etc . Out 20, 9 snakes were treated under ketamine @ 15mg/kg, 5 snakes were treated with ketamine-Butorphenol @ 10mg/kg and 1mg/kg respectively and 6 snakes were treated with ketamine-Diazepam combination @ 10mg/kg and 0.2mg/kg respectively.

WHM-56

RETRIEVAL OF AIR GUN PELLETS FROM VARIOUS BODY LOCATIONS IN RAT SNAKE

Mayur R. Kate and Syed Bilal Ali
Veterinary Officer, Transit Treatment Centre, Nagpur Forest Division, Nagpur
mayurkate.kate4@gmail.com

Rat snakes weighing 2.2kg was rescued and presented at Transit Treatment Centre with the history of hard mass at different locations of various body parts and unable to crawl. On radiographic examination, air gun pellets were observed. The pellets were removed surgically using aseptic protocol under general anaesthesia using ketamine-Butorphenol @ 10mg/kg and 1mg/kg respectively. Post-operatively, fluid therapy with

inj. Ringers Lactate @ 20ml/kg, inj. Ceftazidine @ 20mg/kg IM, q72h and Meloxicam @0.5mg/kg was given. The dressing of wound was done with Muprocin and Placentrix ointment.

WHM-57

SURGICAL CORRECTION OF ENTEROCUTANEOUS FISTULAS IN INDIAN ROCK PYTHON (*Python molarsus*)

[1]Mayur R. Kate, [1]Syed Bilal Aliand [2]Tista Joseph
[1]Veterinary Officer, Transit Treatment Centre, Nagpur Forest Division, Nagpur
[2] Post graduate Scholar, Department of Veterinary of Surgery and Radiology, Nagpur
mayurkate.kate4@gmail.com

A python weighing 9.7kg was rescued and presented at Transit Treatment Center with opening over the body with decaying material lodged in it and nylon manja entangled around body. On examination, it was observed that; the python was suffering from dehydration and enterocutaneous fistula with necrotic pray bird lodged in it. Fistula occurred due to inability to pass the engulfed bird along the length of the alimentary tract. The fistula was corrected surgically using aseptic protocol. The stomach was sutured using chromic catgut 3-0. The operative procedure was carried under general anesthesia using Ketamine-Butorphenol combination @ 10mg/kg and 1mg/kg respectively. A standard post-operative protocol was given. However, the python succumbed due to its injury on next day.

WHM-58

INTRAMEDULLARY PINNING OF FEMUR IN BLACK BRITTEN

Mayur R. Kate and Syed Bilal Ali
[1]Veterinary Officer, Transit Treatment Centre, Nagpur Forest Division, Nagpur.
mayurkate.kate4@gmail.com

A Black Britten weighing 280 grams was rescued and presented at Transit Treatment Centre. On examination, it was observed that, the bird was unable to bear weight on right limb. A crepitus was felt on palpation at the femoral region during physical examination.Radiographic examination confirmed a simple, transverse, diaphyseal fracture of right femur. Bird was anaesthetized with ketamine-diazepam combination @ 15mg/kg and 1mg/kg respectively. Surgery was performed for introduction of K-wire to immobilize the fractured bone and external immobilization done to restrict movement. The standard post-operative treatment comprising of

antibiotic, anti-inflammatory and analgesics along with fluid therapy was given. Follow-up radiograph after four weeks showed complete union of fractured ends. The bird recovered uneventfully with complete weight bearing on affected limb and the K-wire was removed 6 weeks after the surgery. The bird was released to its natural habitat. Thus, intramedullary pinning under ketamine-diazepam combination anesthesia found to be safe technique for the repair of orthopedic surgeries in birds.

WHM-59

ACCIDENTAL MANDIBULAR FRACTURE IN A BLACK BUCK AND ITS SURGICAL MANAGEMENT

Mayur R. Kate and Syed Bilal Ali
Veterinary Officer, Transit Treatment Centre, Nagpur Forest Division, Nagpur.
mayurkate.kate4@gmail.com

A black buck hit by vehicle rescued from agricultural land with dropping of lower jaw was shifted at Transit Treatment Center. Radiographic examination showed oblique fracture at horizontal ramus of mandible. The fracture segments were stabilized by interfragmentary Wiring. The operative procedure was carried out under general anesthesia using xylaxine-ketamine combination @ 0.5mg/kg and 1mg/kg body weight respectively. However, the animal succumbed to its injury on next day.

WHM-60

SUCCESSFUL MANAGEMENT OF BILATERAL TARSOMETATARSUS (SHANK) IN A GREATER COUCAL CROW PHEASANT (BHARDWAJ)

Sanjay J.Gaikwad
Regional Joint Commissioner of Animal Husbandry, Aurangabad ,Maharashtra
sj66gaikwad@gmail.com

A Bhardwaj bird was rescued from road. It was injured by a vehicle while flying across the road. Both the tarsometatarsus showed compound complete fractures. After proper reduction and dressing both the fractured legs were set by using specially designed splints made from wire and using cohesive bandage. Cohesive bandage was very helpful and effective in birds due to its light weight and self-adhesive property. Postoperatively the bird was managed by proper feeding and watering for one month. After complete and eventful it was recovery released in its natural habitat by forest officials.

WHM-61

CASE REPORT OF POST MORTEM FINDINGS OF STRIPED DOLPHIN

Prasad Khedkar and Acharya P.R.
1. Veterinary Officer, Division forest office, Chiplun (Ratnagiri) and
2. Wildlife Veterinary officer, Wildlife SOS, India
prasadkh14@gmail.com

In the month of peak summer, a carcass of striped dolphin (*Stenella coeruleoalba*) was presented for necropsy with history of stranding on beach in between the rocks around seven hours. External examination revealed that it was an adult female of total length 229 cm and axillary girth 105cm. Carcass was moderately dehydrated, shrunken and dry eyes, body was covered with sand, several bruises and contusions noticed all over body parts with major wound at tail region. Clotted blood observed at mouth and genital slit. Upper digestive and respiratory tracts were filled with sand particles. Haemorrhagic heart and congested pericardium was observed along with multiple rib fractures. Congestion was observed in liver and kidneys. Excessive accumulation of blood in abdominal/coelomic cavity was noticed. Cause of death was diagnosed as may be due to hypovolemic shock.

WHM-62

SUCCESSFUL INTRAMEDULLARY PINNING FOR FRACTURE MANAGEMENT OF RADIUS ULNA BONE IN SHORT NOSED FRUIT BAT

Mayur R. Kate and Syed Bilal Ali
Veterinary Officer, Transit Treatment Centre, Nagpur Forest Division, Nagpur.
mayurkate.kate4@gmail.com

A short nosed fruit bat weighing 80gms rescued and presented to Transit Treatment Center with open fracture of radius ulna. Dehydrated, unable to take flight and emaciated. Radiographic examination was done to detect any other fracture. The bat was stabilized by giving supportive fluid therapy, antibiotics, anti-inflammatory and analgesic drugs. Further, surgical site was prepared aseptically and fracture was stabilized by retrograde technique of intramedullary using 22 gauge spinal needles. The surgical procedure was carried out under general anesthesia using midazolam-ketamine combination @ of 1mg/kg and 10 mg/kg. The surgical wound was closed in routine manner using vicryl 3-0. Post-operatively, rehydration, oral medication with Ceftazidime 25-30 mg/kg IM and Meloxicam @ 0.5 mg/kg was given once a day for 7 days. The bat

showed uneventful recovery. After, assessing the flight of the bat, it was then released in to its natural habitat.

WHM-63

STUDIES ON PREVALENCE AND THERAPEUTIC MANAGEMENT OF ENDOPARASITISM IN CAPTIVE WILD CARNIVORES OF CHHATTISGARH

S. Chandrakar, S. Roy*, J.K. Khutey, J. Singh, S.L. Ali, D. Markandey* and K. Jambagi*
Wildlife Health and Forensic Centre, *Department of Veterinary Medicine,
College of Veterinary Science & A.H., Anjora,
D.S.V.C. Kamdhenu Vishwavidyalaya, Durg, Chhattisgarh, India
vet_jasmeetsingh@rediffmail.com

A total of 180 faecal samples of captive wild carnivores were collected to study the prevalence of gastrointestinal parasites from 3 different zoos viz. Maitri Bagh Zoo, Bhilai, Nandanvan Zoo and Safari, Raipur and Kanan Pendari Zoo, Bilaspur, Chhattisgarh. The overall prevalence of gastrointestinal parasites was found to be 31.67% (57/180). The overall prevalence of gastrointestinal parasites was found to be highest in Kanan Pendari Zoo, Bilaspur (46.10%) followed by Maitri Bagh Zoo, Bhilai (33.33%) and Nandanvan Zoo, Raipur (17.14%). Young animals (36.00%) were found to be more susceptible for gastrointestinal parasites than adult ones (30.97%). Highest prevalence of gastrointestinal parasites was observed in leopard (50.00%) and Strongyle spp. was reported to be the most common endoparasitic infection in faecal samples of captive wild carnivores. A total of 20 captive wild carnivores infected with gastrointestinal parasites were treated orally with fenbendazole @ 10 mg/kg body weight orally mixed in meat and the drug was found to be 80.75% efficacious in eliminating gastrointestinal parasitic infection in captive wild carnivores.

WHM-64

PREVALENCE AND THERAPEUTIC MANAGEMENT OF GASTROINTESTINAL PARASITISM IN CAPTIVE WILD HERBIVORES OF CHHATTISGARH

S. Chandrakar, S. Roy*, J.K. Khutey, J. Singh, S. L. Ali, P.Dinkar and Seema Chelak
Wildlife Health and Forensic Centre, *Department of Veterinary Medicine,
College of Veterinary Science & A.H., Anjora,
D.S.V.C. Kamdhenu Vishwavidyalaya, Durg, Chhattisgarh, India
vet_jasmeetsingh@rediffmail.com

A total of 240 faecal samples of captive wild herbivores were collected to study the prevalence of gastrointestinal parasites from 3 different zoos viz. Maitri Bagh Zoo,

Bhilai, Nandanvan Zoo, Raipur and Kanan Pendari Zoo, Bilaspur, Chhattisgarh. The overall prevalence of gastrointestinal helminths was found to be 34.58% (83/240). The prevalence of gastro intestinal parasitic infection was found to be 31.25% at Maitri Bagh Zoo, Bhilai; 35.50% at Nandan Van Zoo, Raipur and 37.14% at Kanan Pendari Zoo, Bilaspur respectively. Among different captive herbivores, Blue bull showed highest prevalence (55.00%) of GI parasites. During the study, prevalence of nematodes was 43.37% (36/83), trematodes was 33.73% (23/83) while mixed infection was 22.89% (19/83). The gastro-intestinal parasitic infection was 46.65% in males and 22.95% in females. *Strongyle* spp., *Strogyloides* spp. and *Oesophagostomum* spp. were reported to be most common endoparasites observed in captive wild herbivores. A total of 25 captive wild herbivores found to be positive for gastrointestinal parasitic infection were treated with closantel @ 10mg/kg body weight orally mixed in feed. Egg per gram count in the treatment group on 0, 7 and 14th day following treatment revealed highly significant ($p< 0.01$) decrease in EPG values as compared to baseline values (0 day). Hence, drug closantel was found to be 85.28 % effective in eliminating the gastrointestinal parasitic infection in captive wild herbivores.

WHM-65

ACCIDENTAL SNAKE BITE IN VARIOUS PROFESSIONALS: AN OVERVIEW

J. Singh, S. Mallik*,S.L. Ali and Somesh Joshi
Wildlife Health & Forensic Centre, Anjora
D.S.V.C. Kamdhenu Vishwavidyalaya, Durg
*General Secretary, Snake Helpline
vet_jasmeetsingh@rediffmail.com

Snakebite in human beings has been a common occupational hazard in farmers and snake rescuers. However, there are several other occupational professionals which were being bitten by snake. The various types of professions include snake charmers, animal keepers in zoo, herpetologists, fishermen, forest professionals etc. The present study reports about overview of incidences of snake bite in workers of different professions. The various types of complications following snake bite have also been documented in this paper. Hence, it can be assumed that snake bite can be a potential occupational hazard irrespective of professions and necessary protective gears must be used by various professionals to reduce incidence of snake bite.

WHM-66

THERAPEUTIC MANAGEMENT OF INFECTIOUS STOMATITIS IN AN INDIAN ROCK PYTHON

J. Singh[1], S. Mallik[2], S.L. Ali[1], N.E. Gade[3], S. Meshram[3], K. Jambagi[3] and Bijendra Sahu[3]
[1]Wildlife Health & Forensic Centre, [2]General Secretary, Snake Helpline;
[3]College of Veterinary Science & A.H., Anjora
D.S.V.C. KamdhenuVishwavidyalaya, Durg-491001 (Chhattisgarh)
vet_jasmeetsingh@rediffmail.com

The present communication puts on record about a clinical case of an Indian Rock Python was presented with the history of foul smelling mucopurulent discharge from mouth, excessive frothy salivation and anorexia for last 02 weeks. Clinical examination revealed snake to be dull with reduced tongue flicking. Close examination of oral cavity revealed presence of yellowish white caseous lesions along with varying degree of necrotic lesions in oral cavity. Based on the clinical findings, it was tentatively diagnosed as infectious stomatitis and treatment was initiated with oral application of boroglycerine along with parentral enrofloxacin @ 10mg/kg IM every 72 hours interval. Oral administration of Vitamin A and C tablets was supplemented on alternate day for 02 weeks. Sterile swabs were collected from necrotic areas as well as other parts of oral cavity which were subjected for microbial isolation and antibiotic sensitivity. Growth of gram negative bacilli which produced colourless colonies on MacConkey agar and pink colonies on Brilliant Green Agar was observed. Isolate revealed IMVic pattern (-+-+), which confirmed salmonella to be the causative agent. Antibiotic sensitivity revealed high sensitivity to enrofloxacin and ciprofloxacin. Hence, the treatment was continued for 2 weeks at 72 hours interval and the python made an uneventful recovery.

WHM-67

SURGICAL EXCISION OF A FIBROMA IN AN INDIAN ROCK PYTHON *(Python molurus)*

Chetan Dilip Vanjari,
RESQ Wildlife Treatment and Transit Centre, Pune.
vanjarichetan18@gmail.com

A Female Indian Rock Python was found injured and brought to RESQ Wildlife Treatment and Transit Centre, Pune, for its treatment. On examination, it was observed that the python had a big ulcerated tumour attached to the horizontal ramus of its left mandible. She seemed dull, lethargic and incapable of hunting. Radiography was performed to assess the extent of the tumour. The wound was dressed and treated with

antibiotics and anti-inflammatory medication for three days. Surgical excision of the tumour was performed under gas anaesthesia on day four and the tumour was further sent to the laboratory for histopathology. The tumour was diagnosed to be a fibroma. Everting sutures were left intact for 6 weeks. During the recovery period, rehabilitation was done to assess if the python was able to use its jaw well. Once the python was able to hunt for herself, she was released back to same location where she was found.

WHM-68

MANAGEMENT OF CRANIAL INJURY IN INDIAN PYTHON (*Python molurus*)

Shobha Jawre, Devendra Podhade, Amol Rokdhe, Babita Das and Madhu Swami
School of Wild life Forensic and Health,
NDVSU, Jabalpur, 482001
s.jawre@rediffmail.com

An Indian python (*Python molurus*) was presented by the rescue squad with the history of injury in cranial region. Clinical examination revealed fracture of jaw bone, broken teeth and prolapse of right eye. The Python was almost entering towards grave prognosis. It was maintained under heating pad with full oxygenation and whole of the cranial region was cleaned with luke warm normal saline followed by antiseptic dressing with chlorehexidine gel under the local anaesthesia. Boric powder (1% aqueous solution) fomentation with Gatifloxacine eye ointment was applied regularly for one week with supportive medicines. Physiotherapy was also given with ultra violet lamps along with sunlight and environment surroundings. The python recovered uneventfully and released in safe corridors of forest.

WHM-69

BULLET SHOT INJURY AND DEATH IN A LEOPARD (*Panthera pardus*)

Manjunatha, S.S., Kavitha Rani, B. Jayaramu, G.M. and Vinay, S.
Department of Veterinary Pathology,
Veterinary College, Shivamogga
Karnataka Veterinary Animal and Fisheries Sciences University (KVAFSU),
Karnataka, India-577204
drssmsanjunatha@gmail.com

A Postmortem investigation of Female subadult Leopard died due to bullet shot injury in Anandapuram forest range, Shivamogga district, Karnataka, India was carried out. The Leopard was subjected to detailed necropsy and external examination revealed

bulged out eye balls, congested conjunctival mucous membrane, rectal prolapsed, cyanotic tongue and bleeding from oral cavity. Three circular shaped entry wounds and one exit wound was noticed, Inner thigh region at both hind legs revealed circular wound areas with bleeding. Internal examination revealed clotted blood in the thoracic cavity. Injury to the thoracic wall due to physical injury made from sharp object penetrating the lungs. Some lobes of lungs were damaged extensively leading to extensive bleeding and pneumopericardium. Right ventricular hypertrophy and congestive changes over tracheal mucosa was also observed. Entry wound at left shoulder region leading to entry of object fracturing sixth rib passing through lungs and entering through junction of eighth and ninth rib finally lodging of one pellet at right lateral body wall in muscular portion. One more entry wound near ventral aspect of neck leading to entry of sharp object and lodging at subcutaneous portion near right shoulder joint. Visceral organs revealed congestive changes. The cause of death in the leopard was attributed to hemorrhagic shock due to traumatic injury caused by entry of Bullet.

WHM-70

ISOLATION OF MULTIDRUG RESISTANT *Pseudomonas* SPP. FROM WOUNDS IN WILD ANIMALS: A POTENTIAL PUBLIC HEALTH CONCERN

J. Singh[1], S.L. Ali[1], C.Sannat[2], N.E.Gade [2], S. Meshram[2], K. Jambagi[2] and D. Markandey[2]
[1]Wildlife Health & Forensic Centre, [2]College of Veterinary Science & A.H., Anjora
D.S.V.C. KamdhenuVishwavidyalaya, Durg-491001 (Chhattisgarh)
vet_jasmeetsingh@rediffmail.com

The present communication reports about the presence of multidrug resistant Pseudomonas spp. in clinical cases of non healing wounds in various species of wild animals and birds. After thorough clinical examination of different wounds, sterile swab was used to collect microbiological sample for isolation and antibiotic sensitivity test. The presence of gram negative bacilli showing pink colonies on MLA and greenish pigmentation on nutrient agar was observed. Non-fermentative isolates were detected on TSI slant which were positive for catalase and oxidase. Hence, the isolates were confirmed as Pseudomonas spp. The antibiotic sensitivity pattern of isolates revealed susceptibility to doxycycline and azithromycin while isolates iwere ntermediately sensitive to amoxyclav, gentamicin, enrofloxacin, ciprofloxacin and erythromycin. However, the isolates were resistant to ampicillin, ciprofloxacin, chloramphenicol and erythromycin while the isolates were found to be resistant to ampicillin, cefixime, chloramphenicol, cirprofloxacin and penicillin. The observations of our study revealed

the presence of multidrug resistant *Pseudomonas* spp. as causative agent for non healing wounds in wild animals and birds.

WHM-71

SUCCESSFUL INTRAMEDULLARY PINNING FOR FRACTURE MANAGEMENT OF TIBIOTARSUS BONE IN YELLOW FOOTED GREEN PIGEON

Mayur R. Kate and Syed Bilal Ali
Veterinary Officer, Transit Treatment Centre, Nagpur Forest Division, Nagpur.
mayurkate.kate4@gmail.com

A Yellow Footed Green Pigeon rescued from Akola and presented to Transit Treatment Center with clinical symptoms of swelling, ecchymosed and crepitating of bone on palpation. Dehydration, unable to take flight and emaciated. The bird was given supportive fluid therapy @ 4ml/100gms, antibiotics, anti-inflammatory and analgesic drugs. Radiographic examination, confirmed complete fracture of tibiotarsus bone at its midshaft. The fracture was initially stabilized by applying splint. After improvement of activity and body condition. The surgical site was prepared aseptically for stabilization of fracture under general anesthesia with midazolam-ketamine combination @ of 1mg/kg and 20mg/kg. The fracture was stabilized by retrograde technique of intramedullary pinning and manipulation of bone segments using 1mm k-wire. The surgical wound was closed in routine manner using vicryl 3-0 and wound was covered with sterile bandage. Post-operatively, subcutaneous rehydration therapy was given along with oral medication with Clindamycin @ 150 mg/kg and Meloxicam @ 0.3 mg/kg orally for 10 days the bat showed uneventful recovery. After, assessing the flight of the bird, it was then released in to its natural habitat.

WHM-72

CASE REPORT OF SEIZURES IN INDIAN PALM CIVET CAT

Prasad Khedkar
Veterinary Officer, Division forest office, Chiplun (Ratnagiri)
prasadkh14@gmail.com

A case of was reported in plam civet cat (*Paradoxurus hermaphrodites*) was reported at Division forest office chiplun (Ratnagiri), with history of convulsion. Primary symptoms observed were plam civet circling movement with incardination, increased

breathing, increase the heart rate, tempreture 103.2F hence case was diagnosed for epilepsy. Animal was treated with inj.dexamethasone @2mg/kg Bwt intramuscular, Mannitol 15ml I/V for 40min, injection Meloxicam @0.2mg/kg Bwt. Intermittent episode of seizures where notice for 24hrs which last for 15 to 20 second. Hence above prenatal treatment was repeated after 12hrs and ors mixed water given after every 3hrs manually. No episodes of seizures were noticed for next 2 days after 24hrs.and after 2days animal was released at place of rescue.

WHM-73

REPAIR OF A COMPOUND FEMUR FRACTURE IN AN INDIAN JACKAL *(Canis aureus indicus)* BY INTERNAL FIXATION

Chetan Dilip Vanjari,
RESQ Wildlife Treatment and Transit Centre, Pune.
vanjarichetan18@gmail.com

A sub-adult Female Indian Jackal had accidentally fallen into a 20 ft deep well and was transported to RESQ Wildlife Treatment and Transit Centre, Pune by Forest Department, Solapur. On presentation, an infected wound was observed, cranio-lateral to the left stifle joint, with a fragment of the broken bone exposed through the skin. Radiography revealed the presence of a compound oblique fracture of distal metaphysis of left femur. Blood analysis indicated severe neutrophilia. Systemic antibiotics, analgesics and anti-inflammatory medicines were administered, along with daily wound lavage for five days, to control the infection at the wound site. Thereafter, internal fixation was performed using a 2.4mm recon titanium plate. Strict confinement was ensured for about six weeks, after which, another surgery was performed to remove the implant. After monitoring her activity and weight bearing ability of the affected limb, the jackal was transferred into a bigger enclosure for rehabilitation. On regaining appropriate mobility, strength, coordination and balance, the jackal was successfully released back to the location where she was found.

WHM-74

CERCLAGE WIRING AND ACRYLIC FOR FIXATION BEAK FRACTURE IN AN OSTRICH

K.Sridhar, Boon Alwin and Pa.Kalaignan
Wildlife Veterinarian, Arignar Anna Zoological Park, Chennai - 600048
dr.srivet@gmail.com

An ostrich, unable to feed and drink water was reported. On examination, there was a longitudinal fracture of the lower beak with tearing of soft tissue upto rostral pharynx was noticed. The bird's futile attempt to drink and eat food resulted in dropping of them out through the fracture and soft tissue opening. Under general anesthesia, with premedication of Midazolam 0.2mg/kg and Butorphanol 0.2mg/kg IM and induction with Ketamine 5mg/kg and midazolam 0.1mg/kg , IV, at enclosure. The edges of the torn pharynx tissue was debrided and the beak fracture was fixed with cerclage wiring and acrylic hybrid technique. The soft tissue tear was closed by simple continuous using PGA 2.0. The animal started feeding and drinking water normally from very next day without any discomfort and leakage. The suture wound healed completely on 10th post operative day.

WHM-75

CRYOSURGICAL MANAGEMENT OF CHRONIC TAIL WOUND IN AN INDIAN ROCK PYTHON

J. Singh[1], S. Mallik[2], S.L. Ali[1], D. Markandey[3], S. Meshram[3], K. Jambagi[3] and Bijendra Sahu[3]
[1]Wildlife Health & Forensic Centre, [2]General Secretary, Snake Helpline;
[3] Department of Veterinary Medicine, College of Veterinary Science & A.H., Anjora
D.S.V.C. Kamdhenu Vishwavidyalaya, Durg-491001 (Chhattisgarh)
vet_jasmeetsingh@rediffmail.com

An Indian Rock Python was presented with the history of chronic non healing wound on left lateral region of tail for past 2 months. Clinical examination of wound revealed presence of necrotic tissue inside the cavity of wound. Careful excision of dead tissue was carried out using surgical blade followed by application of liquid nitrogen via cotton swab method at weekly interval for 3 occasions. Broad spectrum antibiotics enrofloxacin @ 10mg/kg IM every 72 hours interval was administered on 3 occasions along with daily antiseptic wound dressing with povidone iodine. The wound healed adequately by 26th day and the animal was released in wilderness after a week long observation.

WHM-76

TOXOCARA ELEPHANTIS *(Ascariasis)* INFESTATION IN AN ASIAN ELEPHANT CALF AND IT'S THERAPEUTIC MANAGEMENT

1.Nikitasha Bora, 2. Samshul Ali, 3.Kalyan Sarma, 4. Parimal Roychoudhury, 5.Chethan G.E., 6.H. Prasad, 7.J. B. Rajesh, 8.G. Jagan Mohan Rao, 9.S. K. Behera,10. Dhruba Das and 11. Bhaskar Choudhury

College of Veterinary Sciences and Animal Husbandry Central Agricultural University Selesih, Aizawl, Mizoram

1,10 M..V.Sc. Scholar, 2. Dept. of Veterinary Medicine, 3. ManagerCWRC, 6.Associate Professor, Dept. of Veterinary Medicine, 4. Associate Professor, 5,9 Dept. of Veterinary Microbiology, 6. Assistant Professor, Dept. of Veterinary Medicine, 7. Professor & Head, Dept. of Veterinary Medicine, 8. Assistant Professor,Assistant Professor, Dept. of Veterinary Biochemistry,

11.Deputy Director, CWRC

nikitashavet13@gmail.com

The present clinical case reports ascariasis in a wild young Asian elephant calf and its management. A 5 years old female Asian elephant residing in the rehabilitation centre in Kaziranga was showing mild diarrhoea, inappetence, weight loss and lethargy. Clinical examination revealed normal body temperature, congested mucous membrane, increased pulse rate and eupnoea. Faecal examination revealed the presence of adult Ascarid spp. in stool and microscopic-coprological examination of the faecal sample showed the presence of Toxocara elephantis ova. The haematological analysis revealed an elevation in Hb, TEC, PCV and eosinophil level. Biochemical analysis showed an increased level of AST, BUN and creatinine level. The LPO level was increased and SOD, TAOA and Zn level was found in decreased level. The animal was treated with Albendazole, Zinc glycinate and probiotics Lactobacillus bulgaricus with other supportive therapy. After examination of faecal samples on 10th-day post-treatment, no Toxocara elephantis eggs were observed and after completion of the therapeutic process, animal regained normal health condition.

WHM-77

THE ELEPHANT CALF KILLER – ELEPHANT ENDOTHELIOTROPIC HERPES VIRUS – A SUCCESSFUL TREATMENT STORY

Dayamon D. Mathew[1,2,3],. C. S. Jayakumar[1,2],. Ajithkumar G. S.[2,3], Manu M. [3], Naresh Kumar Singh[3] and Rahul K. Udehiya[3]
[1] Kerala Forests and Wildlife Department, Govt. of Kerala, [2] Department of Animal Husbandry, Govt. of Kerala[3], Faculty of Veterinary and Animal Sciences, Banaras Hindu University
dayamon@gmail.com

Elephant endotheliotropic herpes virus (EEHV) is a virus specifically seen in Elephants. Young Asian elephants are most commonly affected with a mortality rate of approximately 85%. Three elephant calves belonging to Kerala Forests and Wildlife Department were presented with symptoms of lethargy and lameness and acute symptoms appeared all of a sudden. It was diagnosed as EEHV based on RT-PCR done on blood samples and treated famciclovir which was given a dose rate of 16 mg/kg for 2 days and 14 mg/kg for next 12 days orally. Ceftiofur was used at a dose rate of 2.2 mg/kg intramuscularly for 7 days and furosemide and flunixine meglumine was at a dose rate of 300 mg/animal and 1 mg/kg respectively intravenously for 14 days. However, crystalloids were administered at a dose rate of 50 mg/kg/day intravenously and vitamin C (100 mg) fed daily orally. The calves were also given zinc supplements and Immunol™ along with Diakur™ along with atleast two liters of tender coconut water daily. Along side the calves were also given glucose. The enclosures were kept clean and kept soil free, moisture free and was kept warm for early healing. Blood samples were collected on day 14 for screening and the results were negative for EEHV. This is the first report on successful management of EEHV infection in elephant calves in India.

WHM-78

SUCCESSFUL MANAGEMENT OF PARTIAL TENDON RUPTURE IN BLACK KITE

Sawant S. S.[1], Ingawale M.V.[2], Patil M.G.[3], Pawshe C.H.[4], Acharya P.R.[5].
Post Graduate Institute of Veterinary and Animal Sciences, Akola-444001, Maharashtra, India
[1]M. V. Sc scholar,[2], [3] Assistant professor, Department of Animal Reproduction, Gynaecology and Obstetrics, [4] Associate professor, Department of Animal Reproduction, Gynaecology and Obstetrics, [5] Wildlife Veterinary Officer, Wildlife SOS, India.
sawantsujata4540@gmail.com

A young black kite (*Milvus migrans*) weighing about 600grams with the history of injury due to kite thread, mild oozing of blood from wing, unable to hold wing

properly hence bird was not able to fly was presented. Physical examination revealed the bird to be dull and depressed. Radiographic examination confirms the partial rupture of patagial tendon of right side. Dressing of wound was done with povidon iodine ointment and calendula powder. Body bandage was applied. Post operatively oral suspension of Meloxicam and Levofloxacin were administered along with antiseptic wound dressing for 10 days. Muscle and liver pieces of poultry was fed orally. After 10 days there was fibrous healing of tendon occur and bird started holding injured wing with his body normally. Bird was released in their territory.

WHM-79

SURGICAL MANAGEMENT OF COMPOUND TIBIOTARSUS FRACTURE IN A ROSE RINGED PARROT *(Psittacula krameri)*

Rajesh Kumar, Aakanksha, Manjusha, $S_{2,}$ N.K. Verma1 and M. Hoque$_3$
[1]Division of Surgery, ICAR-Indian Veterinary Research Institute,
Izatnagar, Bareilly, Uttar Pradesh
vetrajeshkumar@rediffmail.com

Orthopaedic injuries are common in avian practice. The common causes are falling, an impact with a window or ceiling fan, a crushing incident such as being stepped on, or an encounter with a dog or cat. A fractured leg (broken bone) in a bird can be an emergency. They have very little blood, and blood loss can occur from the bone. They are also susceptible to pain and shock, which can be life threatening. The management of fracture in avian is very challenging due to the anatomic peculiarity of large bones in which medullary cavity is large and cortex is thin. A Rose ringed parrot *(Psittacula krameri*) was presented to referral Veterinary Polyclinic, Indian Veterinary Research Institute, Izatnagar with the history of traumatic injury on left hind limb .Clinical examination revealed compound fracture of mid tibiotarsus bone. Lateral radiograph of left hind limb showed complete mid shaft transverse fracture of tibiotartus and decided to correct by intramedullary pinning. Parrot was anesthetized using Ketmine 60 mg/kg body weight intramuscularly. Following the aseptic preparation of surgical site, a 1.5 mm K-wire was inserted in a retrograde fashion into the medullary cavity so as to fix the fractured bone fragments in proper alignment. After the proper apposition of the bone fragments, muscle and skin incisions were sutured in standard manner. Post-operatively limb was immobilised by bandaging and bird was treated with antibiotics for 5 days and anti-inflammatory drugs for 3 days. The parrot made an uneventful recovery.

WHM-80

BENEFITS OF OPERANT CONDITIONING IN EFFECTIVE VETERINARY CARE OF CAPTIVE SLOTH BEAR *(Melursus ursinus)*

Karthikeyan C.[1] and Hussain Basha[1]
[1]Bear care staff, Wildlife SOS, Bannerghatta Bear Rescue Centre, Bangalore 560083
bbrc@wildlifesos.org

Various behavioral objectives could be achieved through positive conditioning of captive wildlife. Wildlife SOS established four sloth bear rescue and rehabilitation facilities. Once such facility is Bannerghatta bear rescue center and the staff have come up with set of effective practices and achieved voluntary blood collection in 38 Sloth bears in past one year. The animal has been conditioned to give hands out through an opening in the cage and hold trainers hand without pulling and the blood has been collected through cephalic vein for all Sloth bears. They have been introduced to clicker sound through target training. Diluted honey is used as reward which is filled in an empty water bottle and tiny hole is made on the cap. Sloth bear are myrmecophagous, they search, suck ants, termite and other insects. The tiny hole in the bottle acts as a small puzzle feeder and makes the bear completely focused to suck the food, while drawing the blood.

Bears are conditioned to place the hands out and reward puzzle feeder is given through the mesh of the feeding den cage. Each bear will take its own time to get adjusted and desensitized with the touch, clipping the fur and pricked by the needle. The reward makes the bear more focused towards the food and it gives enough time for the vets to collect blood through cephalic vein. The patience of the staff and consistence session on a daily basis plays a vital role in achieving the goal.

WHM-81

CANINE DISTEMPER IN AN ASIAN PALM CIVET *(Paradoxurus hermaphroditus)* AND IT'S IMPLICATIONS IN ANIMAL HEALTH

Ranjini A. R., Sherin B Sarangam ., Varsha Mary Mathai . and Jayasree K. S.
Regional Disease Diagnostic Laboratory, Kannur, Kerala - 670 001
rddl3kannur@gmail.com

An unusual fatality among Asian palm civets (*Paradoxurus hermaphroditus*) in different localities of Kannavam forest range, Kannur, Kerala was reported by public. The animals were frequently found with convulsions and at times were "found dead" in field. One among them was presented with severe vomiting, diarrhea and nasal discharge.

Clinical examination showed paw pad hyperkeratosis, pustules in lower abdomen and perianal region, and seizures. The whole blood, serum, nasal swab, throat swab, rectal swab, cerebrospinal fluid, corneal impression and peripheral blood were collected for detailed investigation. Haematology revealed anaemia and thrombocytopenia. Peripheral blood smear revealed *Mycoplasma hemofelis.* Cerebrospinal fluid and corneal impression were found negative for rabies by fluorescent antibody technique. Antigen test for other infections such as canine and feline corona virus and parvo viral enteritis were negative. Nasal swab was found positive for canine distemper virus antigen using CDV antigen lateral flow test kit. The case was confirmed as Canine Distemper virus infection complicated with *Mycoplasma hemofelis*. The animal was given supportive therapy but succumbed to death on the fourth day. Post mortem examination revealed pneumonia, gastroenteritis, meningitis, splenomegaly and petechiae all over serosa. Being a fatal and highly contagious disease, canine distemper could threaten their life and pose serious threat to house-hold pets, stray dogs and zoo and wild animals.Routine immunization should be done for house-hold pets and zoo animals. Proper awareness and timely diagnosis could alleviate the anxiety among public.

WHM-82

CHRONIC KIDNEY DISEASE IN A RESCUED SLOTH BEAR (*Melursus ursinus ursinus*) – A CASE REPORT

Arun A Sha[1] and Adhithyan N K[2]
[1]Director - Research & Veterinary Operations
[2] Wildlife Veterinary Officer - Bannerghatta bear rescue centre - Bangalore 560083 Karnataka
adhithyan@wildlifesos.org

A seven-year-old rescued sloth bear (*Melursus ursinus ursinus*) housed in Wildlife SOS, Bannerghatta Bear Rescue Centre, was diagnosed with chronic kidney disease. Despite all the attempts with treatment, the animal succumbed after six months from the time of diagnosis. The animal showed progressive loss of body condition, loss of appetite, anemia, polyuria, poor coat condition with a change in coat color . The animal was treated symptomatically using hematinics and fluids mixed with electrolytes. A specialized diet containing a reduced amount of protein was fed. Herbal kidney protectants were supplemented along with the diet, and the animal was kept under observation and continuous monitoring. Even after one month of medical and dietary management, the animal's condition deteriorated with high serum creatinine 4.39 mg/dL and BUN 48 mg/dL . The animal started to exhibit anorexia, severe diarrhea and vomiting. Aggressive clinical management was initiated with fluid therapy and parenteral nutrition. Despite all this, the animal went into lateral recumbency along with signs of

uremic breath, severe dyspnea and anuria. The serum biochemistry revealed significantly elevated creatinine 17.02mg/dL and BUN 202mg/dL.Haematological parameters also showed a gradual decline over the course of disease. Hb was reduced from 10.6g/dL to 6.7g/dL. Following three days of recumbency, the Sloth bear passed away. Postmortem findings revealed severe dehydration and anemia, pale and atrophied kidneys, congested mesenteric blood vessels and lungs, generalized pallor of the vital organs including liver and intestinal serosa. Histopathological lesions of the kidneys were consistent with chronic kidney failure in canines.

WHM-83

SURGICAL MANAGEMENT OF TRAUMATIC CROP FISTULA IN WILD PIGEON

Mayank Parwari and Jignasha M Parmar
Kalapurnashree Karunadham Animal Hospital
Mundra Road, Bhuj, Kuttch-370427
dr.mayankvet1992@gmail.com

A pigeon of about 6 months of age was presented at our hospital with complain of food grains draining through open wound on lower cervical esophageal (neck) and chest region. Crop is a thin muscular expansion of esophagus which temporarily store food. When the crop is full of food, it is often susceptible for trauma. On the basis of clinical examination the condition was diagnosed as a traumatic crop fistula. The surgery was carried out under the light plane of general anesthesia using ketamine hydrochloride @ 35 mg/kg body weight and diazepam (5 mg/kg) anesthesia. The crop was sutured with 2-0 polygalactine 910 and skin was sutured separately with 2-0 polyamide. The bird was treated with amoxicillin with clavulanic acid @ 125mg/kg PO every 24 hours and drops meloxicam @ .2 mg/kg body weight (2drops) every 24 hours orally. The bird was followed for 15 days and recovered uneventfully.

WHM-84

FORELIMB AMPUTATION IN A GOLDEN JACKAL *(Cuon aurius)*

Dhanalakshmi, S[1]., Vanishree[2], Malati Naik[1] and Rashmi L[1]
[1]Assistant Professor, Veterinary College, Hombal Road, Gadag – 582101 Karnataka.
[2]Veterinary Officer, Sri Atal Bihari Vajpayee Zoological Park, Kamalapur, Hospet-583223 Karnataka.
vanihirmath44@gmail.com

Golden Jackal is a very timid animal and requires meticulous handling for successful treatment in traumatized condition caused by infighting. A 3year old, female, Golden Jackal, at Kamalapur Zoo had extensive bite wounds with non-weight bearing

lameness of left forelimb. There were deep lacerations and loss of soft tissue in the cranial and medial aspect of the limb extending from distal humerus to the carpal joint. Flexion of elbow and carpal joint with loss of motor and sensory response was evident indicative of damage to extensors and radial nerve. Initial treatment included patient stabilized with fluid therapy, supportive treatment, control of haemorrhage and primary wound management by physical restraint. Since there was progressive necrosis of affected limb and deterioration in systemic condition, forelimb amputation was undertaken on 3rd day. Body weight was 9.45kg. Blood values had low haemoglobin and PCV. General anesthesia achieved with a mixture of atropine 0.3mg, xylazine 10mg and ketamine 50mg IM route and maintenance with IV bolus dose of ketamine as required. The affected limb was detached from thoracic attachments by scapulectomy. Haemorrhage was controlled by electrocoagulation and ligation. Muscles were opposed by inversion suture and skin incision closed by cross mattress suture using polyglactin 910 size 2-0. Post-operatively, thick padded bandage applied around thoracic region and e-collar applied to prevent automutilation. Supportive treatment, fluid therapy, wound dressing and nutritional management was undertaken for a week. Animal recovered uneventfully and was able to ambulate in three limbs. Scapulectomy was feasible technique in this case.

WHM-85

GIGANTIC ILLNESSES- AN EXPLORATION BY AUTOPSY

*****Nandakumar.S., Ajithkumar.G.S. and Jayakumar.C.S
* Disease Investigation Officer, Centre for Wildlife Sciences, SIAD, Palode, Kerala
Veterinary Surgeon, Centre for Wildlife Sciences, SIAD, Palode, Kerala
Assistant Director, Department of Animal Husbandry,Kerala
drnand@yahoo.com

Based on the investigations conducted over two decades, this paper outlines five different interesting cases where autopsies have lead to a confirmatory diagnosis .The first is a case of sudden death of a captive tusker which showed signs of exercise intolerance. Autopsy revealed suppurative pneumonia where in large abscesses were noticed throughout the lung parenchyma with caseous pus oozing out from the cut surface. This might have resulted from exposure to some environmental pathogen in an unclean enclosure. The second case was an elephant which had severe impaction of the colon where in the terminal bowel segment was seen incarcerated by huge impacted boli resulting in toxaemia and death. The elephants in captive conditions are stall fed and there is hardly any exertion leading to bowel stasis. The third case was a captive elephant

which was treated for chronic indigestion. Autopsy revealed large pitting ulcers in the gastric mucosa, peritonitis and large quantity of gravel was found in the stomach.The fourth case was an elephant calf which was lethargic, dehydrated and on autopsy, the gross lesions observed were generalised visceral congestion and perforation of the oesophagus caused by obstructing stones leading to fatal toxaemia. Animals born wild when kept under captivity are likely to show vices like pica and this might have resulted in the condition. The last case was an abandoned elephant calf which became febrile with accompanying malaise, facial oedema and cyanosis of tongue. Autopsy revealed haemorrhagic lesions-epicardial petichiae and mesentric vasculitis suggestive of Elephant Endotheliotropic Herpes Virus. Diseases, poor management and faulty feeding practices may take a heavy toll on lives of elephants and necropsy is certainly a fool proof diagnostic method for confirmation of the cause.

WHM-86

CARAPACE FRACTURE AND ITS MANAGEMENT IN AN INDIAN FLAPSHELL TURTLE (*Lissemys punctata)*- A CASE REPORT

Prabha Sharma[i], Amolak Sharma[ii], Gulshan Kumar[iii] and RP Pandey[iv]
prabhasharmadr@gmail.com

A 7-year-old male turtle weighing around 2 kg was presented to Teaching Veterinary Clinical Complex, Mathura with a history of a road accident. Clinical examination revealed fractured carapace along with an eviscerated mass. In radiography, there was no injury to the vertebral column. The wound was thoroughly cleaned with diluted povidone iodine and replaced back in the body cavity using a sterile gauze. The broken shell was put into alignment and was fixed by using super glue (commercial cyanoacrylate) and bandaged with adhesive tape. The anti-inflammatory drugs (meloxicam@ 0.1mg/kg) and antibiotics(enrofloxacin@10mg/kg) were given. The owner was advised to restrict the movement of animal. After 3 months of follow up, the animal was ambulatory with progressive healing of carapace.

WHM-87

SURGICAL CORRECTION OF RECTAL PROLAPSE IN AN INDIAN GREY MONGOOSE PUP (*Herpestes edwardsii*)

Lavanya, B.[1], Reji Varghese[2], Laiju M. Philip[2], Sharat Joshi[1], Praveen M. K.[1],
Syam K. Venugopal[3]
[1]M.V.Sc. Scholar, [2]Assistant Professor, Department of Veterinary Surgery and Radiology,
College of Veterinary and Animal Sciences, Mannuthy, Thrissur, Kerala
[3]Professor and Head, University Veterinary Hospital, Kokkalai, Thrissur
Kerala Veterinary and Animal Sciences University
lavanyasophie@gmail.com

An Indian grey mongoose pup (*Herpestes edwardsii*), of approximately 3 months old, was brought to University Veterinary Hospital, Kokkalai with a history of a

mass hanging near anal region since one day. On clinical examination, the mass was diagnosed as rectal prolapse. The animal was restrained in a closed box with gas inlet. General anaesthesia was induced using chamber induction method with isoflurane @4 L/min and it was maintained at 1L/min after induction. Under general anaesthesia, the prolapsed mass was thoroughly irrigated with normal saline to remove dirt and debris. Lignocaine 2% gel was applied all over the surface of the mass. Then the mass was gently pushed inside using the tip of the thermometer. The mass was secured inside carefully by a purse string suture applied around the anus using silk size 1 suture. Post-operatively the animal was administered with oral antibiotic Tab. Cefalexin @15mg per Kg B.W. for five days. Gross examination of the faecal sample revealed the presence of larva of strongyle spp. Albendazole oral suspension (5%) @ 5mg per Kg B.W. was given for deworming. Seven days of after treatment, animal succumbed to death due to unknown reasons.

WHM-88

BREECH PRESENTATION – A CASE REPORT OF FOETAL DYSTOKIA IN RHESUS MACAQUE

Prajakta[1],Ilayaraja S[2],Acharya P.R.[1] Shivani[1], Baiju raj MV[5.]and Arun A.Sha[4]
([1]Wildlife Veterinary officer, Wildlife SOS, India.,[2]Deputy Director Veterinary Services, Wildlife SOS, India., [3]Director Conservation Project, Wildlife SOS, India., [4]Director of Veterinary Services and Research, Wildlife SOS, India)
vetprajakta@wildlifesos.org

A case of dystokia in Rhesus macaque (*Macaca mulata)* was reported at wildlife hospital, WildlifeSOS, Agra with a history of dystokia since 3 hours. An adult female Rhesus macaque was observed with partial expulsion of foetus which was hanging at vaginal opening, severe straining and labour pain. The dead foetus found with all the four limbs out and head stuck in vaginal passage. Hence, the case was diagnosed for foetal dystokia due to breech presentation. Animal was immobilized by inj. Xylazine @ 2mg/Kg.Bwt. and inj. Ketamine @ 2.5mg/Kg.Bwt. intramuscularly, which occurred on 12th min. The female was restrained in sternal recumbency and 5 ml of liquid paraffin was poured in vaginal passage and the hanging died male foetus was removed applying mild traction by hand. Catheter was inserted in uterine cavity and flushed by inj. Metrogyl @ 60 ml (Total dose). Inj. RL @ 300 ml (Total dose) i/v, inj. Melonex @ 0.2 mg/Kg.Bwt. and inj. Tribivet @ 2ml (Total dose) i/v was given during sedation. Animal was recovered from sedation after 40 min and kept under observation for 3 days. No abnormality was noticed, and on 4th day monkey was released at place of rescue in troops.

WHM-89

A CASE REPORT OF SUBMANDIBULAR ABSCESS IN LEOPARD

Bawaskar, S.S., A. B. Motghare, M.S. Bawaskar and R.S. Khobragade
Maharajbag Zoo, College of Agriculture, Nagpur
abhijeet.motghare@rediffmail.com

An adult male leopard of Maharajbag Zoo, College of Agriculture, Nagpur was dull in movement and showed swelling on right mandible. Feed and water intake was normal. On clinical examination submandibular swelling was extended up to right ear and aural discharge was seen. Abscess was drained with 18 G needle and irrigated with Tr. Iodine and H_2O_2 along with injection Monocef, injection Melonex and Topicure spray. After seven days of treatment animal recovered uneventfully.

WHM-90

AURAL ABSCESS IN A RED EARED SLIDER *(Trachemys scripta elegans)* AND IT'S SURGICAL MANAGEMENT

J. Singh*, S.L. Ali*, D. Markandey, K. Jambagi, Govinda Sahu and U. Baghel
*Wildlife Health and Forensic Centre, Department of Veterinary Medicine,
College of Veterinary Science & A.H., Anjora,
D.S.V.C. Kamdhenu Vishwavidyalaya, Durg, Chhattisgarh, India
vet_jasmeetsingh@rediffmail.com

The present communication deals with a Red-eared slider presented with previous history of swelling near lateral aspect of head for 2 weeks. The case was already being attempted by local veterinarian with negative outcome. The mass appeared to be gradually increasing leading to tilting of head of turtle to affected side. Clinical examination of the swelling revealed doughy appearance which led to tentative diagnosis as aural abscess. The surgical intervention as planned to remove the pus under ketamine anaesthesia. The pus ball was removed from the cavity and the cavity was cleaned with sterile swab followed by flushing of cavity with povidone iodine. The wound was left unsutured to prevent recurrence. Post-operative administration of broad spectrum antibiotic cephalexin @ 10 drops BID for 5 days and analgesic meloxicam @ 5 drops BID for 3 days was carried out along with topical dressing with mupirocin ointment. The patient made an uneventful recovery by end of 7th day and swelling did not recurred during followup period of 1 month.

WHM-91

SURGICAL MANAGEMENT OF AN EXCESSIVELY LARGE TESTICULAR TUMOR IN A BLUE BULL *(Boselaphus tragocamelus)*

J. Singh[1], S.L. Ali[1], R.K. Verma[2], R.L. Rakesh[2], B. Shrimali[2], S.Jaiswal[3] and P.Sao[3]
[1]Wildlife Health and Forensic Centre, [2]Veterinary Officer, Forest Department- Chhattisgarh,
[3]College of Veterinary Science & A.H., Anjora,
D.S.V.C. Kamdhenu Vishwavidyalaya, Durg, Chhattisgarh, India
vet_jasmeetsingh@rediffmail.com

The present clinical case deals with surgical management of massive sized testicular tumor in a male blue bull housed at Nandanvan Zoo, Raipur. A six years old male blue bull was presented with history of football sized testicular swelling for last 2 months. The case was initially being treated as an inflammatory swelling but the swelling continued to increase gradually and it became massively enlarged to cause hindrance in movement of the animal. The animal was kept off fed for 24 hours followed by anaestheic administration of xylazine-ketamine combination using projectile syringe. After adequate level of anaesthesiia was achieved, the mass was aseptically prepared and scrotal ablation was carried out by using Vicryl no.1 as suture material for ligation of thickened spermatic cord. Double ligation as carried out at 2 different levels about 1 inch apart followed by severing of spermatic cord just 2 cm below the distal ligation. Skin was sutured using Silk no.1 followed by antiseptic and fly repellant application. Oral administration of broad spectrum antibiotic amoxirum forte @ 1 boli BID for 5 days and analgesic bolus melonex @1 boli OD for 3 days was prescribed along with topical spray of fly repellant and antiseptic solution over suture line for 10 days. The animal made an uneventful recovery and no recurrence has been reported for last 6 months.

WHM-92

CHALLENGING EXPERIENCE DURING TREATMENT OF OCULAR INJURY IN WILD BUFFALO *(Bubalis arnee)*

J. Singh[1], R.K. Verma[2], S.Joshi[2], N.E.Gade[3], S.L. Ali[1], K. Jambagi[3] andPreety Singh[4]
[1]Wildlife Health and Forensic Centre, [2]Veterinary Officer, Forest Department- Chhattisgarh,
[3]College of Veterinary Science & A.H., Anjora, D.S.V.C. Kamdhenu Vishwavidyalaya, Durg,
[4]Indian Veterinary Research Institute, Izatnagar, Bareilly
vet_jasmeetsingh@rediffmail.com

A male wild buffalo named ‘Chhotu’ aged 16 years and weighing approximately 800kg belonging to Wild Buffalo Conservation Centre, Gariyaband was presented with history of swelling in right eye for last 3 days. There were signs of excessive lacrimation

along with slight mucopurulent discharge from affected eye. The case was initially treated by Forest department Veterinarian, USTR with oral meloxicam and vitamin A preparations once daily. However, the medicinal therapy failed to relive the condition and hence expert opinion was sought from Wildlife Health and Forensic Centre and Senior Forest Veterinary Officer, Raipur. The animal was dragged towards a plain area inside the big enclosed area and darted with xylazine-ketamine cocktail using projectile syringe. Once the patient seemed adequately anaesthetized, ophthalmoscopic examination was carried out for affected eye keeping normal eye blinded. The findings of ocular examination revealed that there were small abrasions in eyelids along with conjunctivitis while the cornea was unaffected. It was decided to clean the affected eye using normal saline and boric acid solution followed by instillation of topical antibiotics moxifloxacin and placentrex ointment. Parenteral administration of brad spectrum antibiotic ceftriaxone 6 gram IM along with Vitamin A 20ml IM was carried out followed by administration of yohimbine. The patient revived from anaesthesia within 5 minutes but immediately after recovery, the animal started running towards water source. Despite of animal keepers hitting the animal with bamboo sticks, it jumped inside the water pond. A major portion of body of the animal got drowned inside the pond and due to muddy base of pond the animal got stuck. Courageous team of Veterinarians immediately came to action and roped the horns of wild buffalo despite of all odd risky situations. Successful lifting of head portion of animal was done to prevent its head from drowning followed by pulling of the animal gradually using help of handlers. The animal was also administered dexamethasone to prevent stress of excessive handling. After struggling inside pond water for 1 hours and taking a big risk, the team of Vets along with forest staff could bring the animal out of water and drag him to deep enclosure area. Oral administration of broad spectrum antibiotics amoxirum forte and oral vitamin A capsules @ 15 capsules once daily was carried out for 5 days and patient made an uneventful recovery. The animal is doing well till date with no visual impairment in affected eye.

WHM-93

SUCCESSFUL RELEASE OF SEIZED INDIAN PANGOLIN (*Manis crassicaudata)* TO IT'S NATURAL HABITAT

S.K. Joshi[1], R.K.Verma[1], J.Singh[2], R.L.Rakesh[1], Preety Singh[3], A, Sonwani[2] and B. Shrimali[2]

[1]Veterinary Officer, Forest Department-Chhattisgarh, [2]Wildlife Health and Forensic Centre, D.S.V.C. Kamdhenu Vishwavidyalaya, Durg [3]Indian Veterinary Research Institute, Izatnagar, Bareilly

vet_jasmeetsingh@rediffmail.com

A female Indian Pangolin was seized at the Udanti Sitanadi Tiger Reserve's buffer area from poachers of neighboring district. Morphological parameters were 09kg

body weight, body length 76cm, head length 9cm, tail length 45cm, shoulder height 17cm, hind leg and fore leg length 16cm & 13cm respectively, ear length 3cm, neck girth 22cm, chest girth 38cm, size of scale of different body parts, head 0.8cm neck 2.9cm back 3.9cm rump 4.2cm tail base 3.8cm tail tip 1.3cm long. The seized animal was observed as healthy and passed urine and defecated immediately after keeping it inside a simulated caged enclosure with shrubs & termites. After completing all legal formalities against poachers, chief judicial magistrate issued order for release of seized Indian Pangolin to their natural habitat and the animal was released in core area of USTR on next day evening.

WHM-94

TRANSLOCATION OF WILD BUFFALOES FROM ASSAM TO CHHATTISGARH DESPITE COVID LOCKDOWN

J. Singh[1], R. K.Verma[2], S.K. Joshi[2], A.Sonwani[2], B. Choudhary[3], S Ali[3] and P. Balasumatry[4]
[1]Wildlife Health and Forensic Centre, D.S.V.C. Kamdhenu Vishwavidyalaya, Durg, Chhattisgarh
[2]Veterinary Officer, Forest Department- Chhattisgarh [3]Wildlife Trust of India, [4]Veterinary Officer, Forest Department- Assam
vet_jasmeetsingh@rediffmail.com

The present communication deals with first ever longest translocation of wild buffaloes via road from Manas National Park (MNP), Assam to Barnawapara Wildlife Sanctuary (BWLS), Chhattisgarh. A complete one and half month time frame was estimated for capture, conditioning of the animal, genetic testing of the animal and transportation of animals. Capture teams were made comprising of Veterinarians and forest staff officials from WTI and Govt. of Assam. Combination of Etorphine, Thiafentanil and Azaperone for darting from elephant's back in Bansbari range, MNP led to capture of sub-adult female on 12th February, 2020 followed by capturing male buffalo by ambushing on tree top on 15th February, 2020. The biggest challenge which arose was COVID lockdown from 25th March, 2020. Immediately after getting perimission on 14th April, 2020, two teams were made to capture male and female immediately after sedation from boma and transfer to transport truck in morning of 15th April, 2020. Transport vehicle was cleaned and animals were offered fresh feed, fodder and watered at every 200km interval and final destination of Wild Buffalo Breeding Centre, BWLS was reached on noon of 18th April, 2020. Both animals were given a final bath inside transport vehicle before finally releasing them inside holding enclosure and were provided with fodder and water inside enclosure immediately after their release into enclosure. The team was finally handed over to health officials for further formalities and

were sent to quarantine facility established at Prayatak Gram situated at Bar Village inside BWLS.

WHM-95

POST MORTEM EXPERIENCE OF RESCUED INDIAN PANGOLIN *(Manis crassicaudata)*

R.L.Rakesh [1], S.K.Joshi[1], J. Singh[2], R.K.Verma[1], Preety Singh[3], B. Shrimali[1], S. Mishra[1], A.Sonwani[1] and Lileshwar Chaudhary[1]

[1]Veterinary Officer, Forest Department- Chhattisgarh [2]Wildlife Health and Forensic Centre, D.S.V.C. Kamdhenu Vishwavidyalaya, Durg, Chhattisgarh [3] Indian Veterinary Research Institute, Izatnagar, Bareilly

vet_jasmeetsingh@rediffmail.com

The present communication puts on record post mortem findings of 4 years old female Indian Pangolin brought to Nandanvan Jungle Safari, Nava Raipur by Forest department officials of Mahasamund division, Chhattisgarh on 14th June, 2020. The post mortem examination was performed according to standard protocols. Gross examination revealed pus discharge from wounds near shoulder region and a couple of skin lacerations. The whole body was opened and representative samples of different organs were collected in 10% formalin for histopathological examination. There were congestion and haemorrhages, heavy infiltration of mononuclear cells in bronchiole and accumulation of serofibrinous exudate in lungs, widespread degenerative and necrotic changes in hepatocytes and haemorrhages in liver were observed, severe depletion of lymphocytes from Malpighian corpuscle of spleen and oedema were observed, congestion with degenerative and necrotic changes in myocardial fibers were noticed in heart, in kidney congestion, haemorrhages, degenerative and necrotic changes in glomerulus, proximal and distal convoluted tubules with albuminous cast were observed, in intestine congestion and desquamation of mucosal epithelium were observed, cystic dilatation of few endometrial glands was observed in uterus. The possible cause of death in present case could be due to multiple organ failure.

WHM-96

MANAGEMENT OF AGED CAPTIVE WILD ANIMALS IN ZOOS: ISSUES AND CHALLENGES

Dr. K. Raja Kishore and Dr. B. Sravani

Sri Venkateswara Veterinary University, Department of Animal Nutrition

NTR College of Veterinary Science, Gannavaram-521 102, Andhra Pradesh, India

dr_rajakishore@yahoo.co.in

Proper management of wild animals in captivity incorporates both husbandry skills and applied nutritional sciences. Many animals experience physical and

behavioural changes as they age. Age-related changes in physical or mental ability can limit the opportunities for animals to experience positive well-being. The physical and psychological changes colloquially referred to as 'ageing' are more technically defined as 'senescence'. Senescence is characterized by a suite of physiological changes leading to decline or cessation of reproduction and increased risk of mortality. Physical changes include change in body mass and composition (decrease in lean body mass and increase in body fat), loss of elasticity in their skin, feather and coat with age (decline in collagen production) and dental issues (abnormal tooth wear and pain may contribute to digestive problems). Cognitive and behavioural changes reflect normal ageing which may be related to changes to various sleep disorders (changes in the time of awake and sleep) and declined overall activity levels. Ageing animals can lose social standing within a group if they are no longer able to actively engage in social interactions with other individuals. Sensory decline is common in aged animals and also associated with neoplasia, cardiovascular and metabolic diseases. No discussion of ageing animal care would be complete without considering end-of-life decision making and humane euthanasia. In zoos and aquariums, veterinarians are responsible for identifying cases where humane euthanasia is medically appropriate to relieve untreatable pain and suffering of an individual. Caring for aged animals requires different areas of expertise which needs an input from nutritionists, general veterinary practitioners, veterinary specialists, behaviourists, trainers, exhibit designers, or construction experts. It is important to maintain open communication with outside consultants when needed, and to provide training opportunities for staff to help develop the institution's working knowledge of how to manage aged animals across taxa. Planning ahead for different life stages is therefore critical for the welfare of all animals living in zoos. It is concluded that, ageing animals may be uniquely vulnerable to a number of negative welfare experiences compared to younger animals and hence, individualized management with critical care would maximize positive welfare opportunities for ageing animals under human care.

WHM-97

MEDICAL MANAGEMENT OF MANGE IN A CAPTIVE ROSY PELICAN *(Pelicanus onocrotalus)*

Powar Komal[1], Valsarajan Dipika[1], Tripathi Sanjay A.[1], Kale Madhumita[1],and Shah Neha[1]
[1]Veermata Jijabai Bhosale Udyan & Zoo, Mumbai (V.J.B.Udyan & Zoo)
vjbudyanzoo@yahoo.co.in

Mange in birds is common where many birds are housed together. It is caused by mites and the site of the lesions varies depending on the species of mite. Veermata Jijabai

Bhosale Udyan and Zoo, Mumbai, currently has two Rosy Pelicans of approximately 25-30 years of age which are housed in the aquatic bird aviary along with other species of aquatic birds. One of the Pelicans was observed to be aggressively preening and biting the back feathers. The Pelican was shifted to the hospital and on examination, the right lateral side of the back appeared raised and inflamed with small superficial wounds and loss of feathers. Skin scraping from the affected site was taken and presence of mite infestation was confirmed on microscopic examination.

The Pelican was administered 0.5mg/kg Meloxicam I/m and a topical application of 0.5ml of injectable Ivermectin on the skin at the base of the tail feathers. Topical Ivermectin application was repeated after a week.

The aggressive preening and biting behaviour had reduced a day after the first topical application of Ivermectin. Skin scraping examination was negative for mites after two weeks with gradual growth of feathers on the affected area.

The Pelican was thus treated successfully for mange with only Ivermectin spot on treatment and wound cleaning.

WHM-98

IMPING OF FLIGHT FEATHERS IN A BLACK KITE *(Milvus migrans)*

Shivani Jain, Meghana Pemmaiah, Purva Nimkar, and Silambarasan R
shivanijain1101@gmail.com

A sub-adult black kite rescued from a locality was brought to People for Animals, Wildlife Hospital, Bangalore. The bird was unable to fly and on examination six of its primary flight feathers were broken. Imping of these feathers was done using the feathers collected from a deceased bird using tissue adhesive. After a days rest in a large enclosure, the flight was checked again and found to have drastically improved and the bird was released after 48 hrs.

WHM-99

GERIATRIC MANAGEMENT OF A HYBRID LIONESS

Khandekar Yashwant[1*], Karawle M.S.l[1], Tripathi Sanjay A[1], and Powar Komal[1]
[1]Veermata JijabaiBhosaleUdyan& Zoo, Mumbai
*KhandekarYashwant- Animal Keeper
vjbudyanzoo@yahoo.co.in

Geriatric management can be challenging in wild animals considering their wild nature and the stress related to handling and restraining. Zoo keepers and vets play an

important role for a stress free geriatric management of zoo animals. It is important that the zoo animals feel less threatened and are cooperative during their care and treatment procedures. The bond between the zoo keeper and the animal and the experience of handling old animals play a major role in their geriatric care.

Here we discuss how the zoo keepers and vets managed geriatric care for a hybrid lioness at Veermata Jijabai Bhosale Udyan and Zoo. The Hybrid lioness was hand raised at the zoo by the keepers and was used to human interaction making the treatments easier. She was trained for routine physical examinations, cleaning and bathing procedures and hand feeding. Towards her later stage of life she developed neurologic problems due to which she was always recumbent and had lost her appetite. However, the keepers managed her care which involved cleaning and bathing her, hand feeding small pieces of meat and boiled eggs, massaging her legs, physiotherapy and assisting the vets during her acupuncture treatments.

Keepers' knowledge about the lioness's behaviour as she was hand raised helped in her stress free geriatric management

WHM-100

SUCCESSFUL MANAGEMENT OF TRANSPORTATION STRESS IN A LEOPARDESS *(Panthera pardus fusca)* AND ROYAL BENGAL TIGRESS *(Panthera tigris tigris)* DURING QUARANTINE PERIOD USING ENRICHMENT ACTIVITIES AND INTERACTION

Shinde Amol[1*], Powar Komal[1], Valsarajan Dipika[1], Sirsat Devanand[1], Satam Abhishek[1], and Tripathi Sanjay A[1]

[1]Veermata Jijabai Bhosale Udyan & Zoo, Mumbai

vjbudyanzoo@yahoo.co.in

Zoos in India follow animal exchange programme between zoos to avoid inbreeding of zoo animals. In April 2019, as a part of animal exchange program, Veermata Jijabai Bhosale Udyan and Zoo, Mumbai received a pair of Leopard from Pilikula Biological Park, Karnataka and in February 2020, the zoo received a pair of Royal Bengal Tiger from Siddharth Garden & Zoo, Aurangabad, Maharashtra.

Transportation stress is a common factor encountered in animals during exchange programme. Moreover, adapting to a new enclosure and animal keeper also adds to the stress. The male Leopard and Royal Bengal Tiger showed less stress and easily accustomed themselves to the quarantine enclosure and new animal keeper. However, the female Leopard and Royal Bengal Tigress were shy, spent most of the day time hiding under the sitting platform, consumed less meat and showed aggressive behaviour when approached.

During this quarantine period, the animal keeper used interaction and enrichment activities to reduce stress in the female big cats thereby helping them bond with the keeper. Hard plastic balls hung from the ceiling, dry hay, meat hidden in card board boxes *etc*. were used for the enrichment activities. Only the animal keeper and vets were allowed to interact with them during the quarantine period.

Eventually, after two weeks, the female big cats appeared less stressed, less aggressive and even allowed the keeper to touch them. There was also gradual increase in their feed intake. Transportation stress in the female Leopard and Tiger was thus successfully managed by simple enrichment activities and interaction with them.

WHM-101

INDUCTION OF MOLTING IN A CAPTIVE FEMALE HUMBOLDT PENGUIN *(Spheniscus humblodti)* USING MANAGEMENTAL PRACTICES

Kale Madhumita[1], Tripathi Sanjay A.[1], Mangnale Govind[1], Shah Neha[1], and Shejul Ranjit[1]
Veermata Jijabai Bhosale Udyan and Zoo, Mumbai
madhumita.kale@gmail.com

Molting is an annual process in the life of a penguin, during which old feathers are replaced with new ones. The average molting period observed in Veermata Jijabai Bhosale Udyan & Zoo is 15-20 days. In V.J.B. Udyan & Zoo, the penguins usually molt between the months of August and November. In captivity, some birds either fail to undergo molting annually or have arrested molt. Molting problems in captivity are associated with photoperiod, light intensity and spectrum, nutrition, deficiencies, and ambient environment.

A female Humboldt Penguin aged 4.5 years was unable to undergo her annual molting. Signs of depression, reduced appetite, weight loss and isolation were noted. Loss of dorsal hock feathers with progressive loss of back feathers was observed. Certain managemental changes were made in her daily routine to stimulate molting with an aim of syncing her reproductive cycle.

Treatment plan included supplementation with Thiamine, Vitamin E, Seacod, Silymarin and Calcium along with daily sunlight exposure for 30 mins. The most effective managemental practice was provision of dummy egg. The dummy egg was incubated for 40 days, during which she was fed only oily fish such as sardines and mackerel at the nest. Upon removal of dummy egg, positive progress was noted in her behaviour and molting occurred within a month.

We were successfully able to stimulate this penguins' molting by only changing some aspects of captive management, without usage of exogenous hormonal treatment. This penguin finally went on to lay eggs for the first time after completion of her molting.

WHM-102

STUDY OF CHANGES IN SERUM BIOCHEMICAL PARAMETERS DURING FRACTURE HEALING IN WILD RABBIT

Jyotsana Bhatt, NS Jadon, Priyanka Pandey and Sara Kaushal
Department of Veterinary Surgery & Radiology
College of Veterinary & Animal Sciences
GBPUAT, Pantnagar- 263145
bhattjyotsana24@gmail.com

Changes in serum biochemical parameters viz. calcium, phosphorous and alkaline phosphatase were studied in four wild rabbits presented with radial fracture. Fractures were stabilized using suitable cardboard splint. Radiographs were taken at weekly intervals upto 6 weeks to analyse fracture healing. Serum was taken from the animals at day 0, 30 and 45 post treatment. Calcium, phosphorous and alkaline phosphatase values were analysed using autoanalyser with Erba kits. All three parameters showed fluctuation in its value on different days of evaluation. There was significant increase in calcium levels on day 30 as compared to day 0. Phosphorous and alkaline phosphatase values showed a significant decrease at day 45 with respect to day 30. This study showed that serum calcium levels increase from day 0 to 45 and phosphorous and alkaline phosphatase values showed a peak at day 30 which gradually decreases to base levels at day 45 after complete fracture healing.

WHM-103

SUCCESSFUL HAND REARING OF THREE WILD TIGER CUBS

Kundan Hate[1], and Sunil Bawaskar[2]
[1]Member – State Wildlife Advisory Board , Maharashtra State,[2]Officer In-charge,
Maharajabag Zoo, Nagpur
kundanhate@gmail.com

Three orphan tiger cubs were successfully hand reared at Maharajabag Zoo. The cubs were rescued from the buffer area of Tadoba Tiger reserve. The cubs were reared for 9 months. For initial days, the cubs were fed with cow milk. Feeding of the cow milk

was not efficient as; feeding cow milk resulted to diarrhoea in cubs. However, the feeding of cow milk with anti-diarrhoeal drugs was also not beneficial. So, taking digestibility into consideration, the goat milk was fed to cubs @ 200 ml twice a day. Further, minced chicken with goat milk was fed from 8th day onward till 45days. Gradually, the cubs were fed with minced chicken and beef without milk. Deworming of the cubs was carried out at the age of 2.5 months. Nearly after, 3month of age cubs were fed with boneless meat. As it was observed that, the cubs were feeding on boneless meat normally. It was decided; to feed the cubs with bigger pieces of meat along with bone. During whole period of rearing nutritional supplements were fed to cubs mixed with milk as cubs avoided taking supplement over the meat.

WHM-104

RECONSTRUCTIVE SURGERY PERFORMED TO RESTORE COMPLETE FLYING ABILITY OF THREE PELICANS (*Pelecanus)* WITH PATAGIUM AND PRO-PATAGIUM LACERATION

Ushma Patel, Shirish Upadhye, Chetan Patond, Rohit Gangwal, and
Abhishekh Narayanan
Raksha and Wildlife Trust of India, Jaipur
drushmapatel11@gmail.com

Two Dalmatian pelicans and one Rosy pelican, on three consecutive days, were presented with deep wing lacerations due to Chinese manjha. The rescuers applied pressure bandage for haemostasis in the field before transporting them to the bird treatment camp.

On clinical examination, one bird had hyperthermia which was managed by cold water enema. Second bird had hypothermia which was counteracted with orthopaedic heating pad. All the birds were catheterised and given intravenous fluids for rehydration. Anti-inflammatories, styptics and antibiotics were administered. Each bird was induced with isoflurane by mask followed by endotracheal intubation for maintenance of anaesthesia. The surgical site was scrubbed, plucked and prepared aseptically.

The anatomical restoration of the patagial and propatagial ligament was undertaken. Muscles, skin and associated soft tissues were sutured. An '8'-figure bandage was applied to the wing. The birds were given clindamycin @ 50mg/kg P/O and meloxicam @ 0.3mg/kg P/O drugs for one week. The birds were supported by tube feeding and passive physiotherapy during post-op period.

They were shifted to larger enclosures one week post operatively for flight practice fitted with different coloured bands on their leg for identification. After complete assessment with respect to their feeding, flight and health, the birds were released back successfully after 25 days. This is the first such case reported from India.

WHM-105

MANAGEMENT OF STRESS AND LAMENESS IN A LONG BILLED VULTURE *(Gyps indicus)*

Devendra Podhade, Ranjeet Harne, Amol Rokde, Nidhi Rajput and Somesh Singh
School of Wildlife Forensic and Health, N.D.V.S.U., Jabalpur
drdevendrapodhade@rediffmail.com

A long billed vulture (*Gyps indicus*) was admitted to the School of Wildlife Forensic and Health, N.D.V.S.U., Jabalpur by the Rescue Squad, Jabalpur with the history of been caught and hit with wooden stick by the villagers near its feeding ground. Physical examination revealed no external injuries but bird was unable to bear the weight on its right limb. Clinical examinations were conducted to access its physiological parameters and biological samples were also collected for further laboratory investigations. Based on the assessment, treatment was started for stress and lameness; and within a week the bird started to bear weight on both the limbs. Finally, it was released back to its natural habitat. Vulture is a very sensitive species and in this particular report, management of stress and lameness in rescued vulture with minimal human intervention was followed.

WHM-106

UNPREDICTED MORTALITY OF SPOTTED DEER (*Axis axis)* AT MINIZOOPAHALGAM, KASHMIR DURING PRE SEASONAL HEAVY SNOWFALL -DIAGNOSIS, TREATMENT RESCUEANDCONTROL

Umar Nazir Zahid[1], Dil Mohammed Makhdoomi[2], A M Pawde[3],K N Vishwas[3]K Mahendran[3],Rashid Yahya Naqash[1], Rouf Zargar[1], and M.A Gazi[4]
Shere-kashmir University of Agricultural Sciences and Technology of Kashmir
dmmakhdoomi@gmail.com

Pahalgam is a world famous hill station located in Kashmir Valley, India with the GPS coordinates of 34° 0' 58.9428" N and 75° 19' 4.9944" E,houses a MiniZoo. During unseasoned heavy snowfall with the accumulation of 8 to 12 feet snow around the habitat /housing of deers during winters of 2019-20,the death of 6 of 15Spotted Deer (*Axis Axis)*of either sex was recorded.Failure to check the mortality, the team of experts from the University of Jurisdiction was called and after adopting prescribed protocol, the

mortality continued.A team from IVRI with a member from SKUAST-K attended the cases and remaining 5 animals survived . Amongst these 10 animals, 9 (90%) animals died of peracute disease, whereas acute death was observed in only 1 case. Significantly high mortality was recorded in 8 gravid females (80%) amongst 10 affected animals. None of the animals that died from peracute disease showed any overt clinical signs or symptoms; however, the acute case showed clear signs of acute anorexia, isolation from the herd, marked depression and recumbency. A few carcases were preserved under 5 feet deep snow, and were excavated by the visiting scientists and the detailed necropsy was conducted.Affected viscera were subjected to microbial culture and isolation and histopathological examinations. Culture and isolation of heart, liver, abomasum and intestinal content revealed presence of *Clostridium perfringens* type A, later confirmed by Polymerase Chain Reaction (PCR) analysis.Necropsies revealed hydroperitoneum, hydropericardium, haemorrhagic abomasitis, severe serosal/mucosal haemorrhages of intestines, and pale and friable liver.

The post-mortem lesions, histopathological findings, isolation of microorganisms and confirmation by PCR ,treatment, control measures that prevented further mortalityshall be discussed in presentation.To the best of author's knowledge, this is the first documented report of a clostridial outbreak in Spotted Deer (*Axis axis*) from Kashmir Valley, India which was timely controlled during inclement harsh minus temperatures at high altitude.

WHM-107

MANAGEMENT OF SNARE TRAP WOUND IN SLOTH BEAR (*Melursus ursinus*) AT GOREWADA RESCUE CENTRE, NAGPUR, INDIA

Upadhye S.V., Dhoot V.M., Pawshe M.D., Shalini A.S.and Kolangath S.M
Wildlife Research & Training Centre, Gorewada, Nagpur
Opp. Hindustan Lever Godown Square, Mahurzhari Road, Fetri, Nagpur 441501
shirishupadhye@gmail.com

A sub-adult female slothbear was reported to be snared by poachers using a nylon rope in the forests of Rui-Khed beat of the Akola division of Maharashtra state. Clinical examination revealed that the sloth bear was dull, with congested mucous membranes, highly dehydrated, respiration laboured and shallow, temperature 103º F, pulse rate 56/min and extensive open wound with maggot infestion, on the right forelimb. On further examination, it was revealed that nylon snare was still intact leading to constriction of underlying deep and superficial blood vessels causing ischemic necrosis. The strangulation lead to gangrene, due to which the metacarpal and phalanges were exposed. In the process digits were detached from the right forelimb and were found to be hanging with the support of skin and devitalized necrosed muscles. The wound was

deep with no active bleeding, necrotic, highly contaminated and gangrenous.The animal was distracted and using a scalpel the snare was safely cut and gently seperated from the animalsuccessfully. The wound was rationally treated and the attached phallages sloughed off on the 10th day after which the wound showed a considerable improvement. The granulation tissue was evident by day 15, after which there was a rapid progress in the healing. By day 20 the skin formation as distinct islands was seen. The care and management continued till day 28 untill complete healing was evident.

WHM-108

SURGICAL MANAGEMENT OF AVIAN LONG BONE FRACTURES USING INTRAMAEDULLARY PINNING ALONE IN COMPARISON TO INTRAMEDULLARY PINNING AND POLYMETHYL METHACRYLATE

Ushma Patel, B. M. Gahlod, S.V. Upadhye, P.T. Jadhao, S.B.Akhare, Shalaka Salvekar and Gauri Khante
drushmapatel11@gmail.com

Birds presented with long bone fractures at Teaching veterinary Clinical Complex, Nagpur were subjected to various immobilization methods which were best suited for the case. The data recorded was divided into two equal groups that were operated by intramedullay pinning alone and by intramedullary pinning and polymathy methacrylate. The bone fractures were resultant of traumatic injuries of different etiologies and birds were stabilized prior to diagnostic procedures. Measures were undertaken to control haemorrhages, hypothermia, hypovolemia and shock by giving fluid therapy, oxygen therapy and keeping bird in warm place using heating pads.

Birds were fasted for two hours before surgery. To reduce handling stress, the preparation of patient was done after induction.

In group I, internal fixation was performed using K-wire or hypodermic needle of appropriate size. In group II, internal fixation was performed using K-wire or hypodermic needle that occupied ≤ 50% of the medullary canal along with PMMA. The PMMA powder and liquid monomer mixed for 30 seconds and dough introduced followed by immediate apposition of fractured ends and insertion of pin in both the fragments. Wound sepsis or osteomyelitis was not observed in group II and it could be due to the antibiotic impregnated bone cement used in the study.

Postoperatively, enrofloxacin was given @ 10mg/kg and meloxicam was given @ 0.3mg/kg along with calcium and multivitamin supplements. Bandaging and supportive splints were applied postoperatively. Soft padding and ‘8’ figure vetwrap bandage was

applied in wing fracture in a flexed position and it was changed and taken off when bird was able to support the leg or wing on its own.

Physiotherapy was given to the birds during bandage change and it helped to avoid patagial contraction which is a common in case of wing bone fracture. All birds were kept initially in small cage followed by large cage to see flight ability and provided adequate exercise before release.

Significant increase in SAP and non significant alterations in serum calcium and phosphorus values were observed in both the groups. All the values were in normal physiological limits.

Clinical evaluation of fracture was assessed by external palpable callus, weight bearing or usage of wing and radiographic examination. During the study, the stability of fracture, weight bearing or wing function returned to normalcy earlier in group II than group I. Intramedullary pinning was useful but limitations like micro movements and rotational instability were noted. The thin avian bone cortex made placement of pins difficult. However, IM pin with PMMA overcome this limitations offered instant stability of fractured fragments and immobilized fractures earlier than IM pin alone in birds.

WHM-109

A COMPARATIVE STUDY BETWEEN ISOFLURANE, HALOTHANE AND XYLAZINE-KETAMINE COMBINATION FOR GENERAL ANAESTHESIA IN BIRDS

Ushma Patel, B.M.Gahlod, P. T. Jadhao, S. V. Upadhye, Gauri Khante, Shalaka Salvekar and S.B.Akhare
drushmapatel11@gmail.com

Total 32 birds of different species including wild and domestic were presented for various affection which required surgical interventions at Nagpur veterinary College, Nagpur. The aesthetic protocol included the use of gaseous general anaesthesia using halothane, isoflurane and injectable anaesthesia using a combination of xylazine and ketamine. The quality of anaesthesia was evaluated by monitoring various physiological parameters, reflexes, muscle relaxation and complications at different intervals before, during and after the surgical procedure. Isoflurane was found superior to other anesthetic protocols.

WHM-110

INTERVENTION FOR MANAGEMENT OF A SIBERIAN BIRD IN SHOCK

J. L. Singh, R. S. Sandhu, Arun Kumar, Manish Kumar, and Shivam kartikey Bhardwaj
College of Veterinary Sciences, GBPUAT, Pantnagar , U.S.Nagar, Uttarakhand
drjlsingh@rediffmail.com

A Siberian bird weighing around 1.2 Kg was brought to TVCC Pantnagar on the evening of 5th November after been hit by a speed boat during boating. These birds are generally migratory birds that come a long way from different countries during the autumn season. These birds generally live in a flock and move together. After being hit by a speed boat the bird came in shock and was unable to move and atypically unconscious. Parameters were recorded using infra-red thermometer and general palpation. Temperature recorded was 106.5 ^{0} F, heart rate was 182/min. the bird was in shock and was handled accordingly by administration of injectable anabolic steroids (Inj. Nandrolone 0.1 ml intramuscularly), Nervine tonic, i.e. Vit. B_1, B_2, B_6 and B_{12} (Neurobion) 0.2ml intramuscularly and antibiotics (Amoxirum forte 30 mg intramuscularly), lukewarm fluid (DNS) per-os after lavage of the crop and tract with help of an infant feeding tube and normal saline. The feeding tract of the bird was found clear. The wild bird social/ welfare worker was the advised to keep the bird away from excessive sound and light inside a box with holes to prevent from further deterioration of condition and advised to offer the bird fingerlings of fishes as feed . The bird was bought the next day to TVCC Pantnagar and was active and alert. Further treatment was administered to the bird orally and the owner was advised to confine the birds in Ranibagh Rescue centre for further 3 days treatment and advised to release the bird from the area of capture for rescuing. Accordingly bird was rescued after 3 days of said medication and release in presence of the local SDO of forest deptt.

WHM-111

MANAGEMENT OF SEPTIC WOUND CREATED AFTER PARTIAL ELECTROCUTION, IN AN INDIAN LANGUR (*Semnopithecus*) BY SURGICAL INTERVENTION

J.L.Singh, R.S. Sandhu, Arun Kumar, Manish Kumar, Shivam kartikey Bhardwaj and Animesh kumar Mishra.
College of Veterinary Sciences, GBPUAT, Pantnagar, U.S.Nagar, Uttarakhand
drjlsingh@rediffmail.com

An Indian Langur (Semnopithecus) was admitted to TVCC Pantnagar on the evening of 23rd September,2020 after falling from height of electric pole . The animal

was presented in shock condition and had deep cuts on the back and loin region. The animal was palpated thoroughly for detection any deep seated pain and X ray was carried out to rule out fracture and dislocations.. Surgical intervention was necessary to close the wounds but the animal was in shock. Necessary life saving medication medication was given to the animal by administration of intravenous DNS-5%, and Dexamethasone (steroids) and necessary antimicrobial antibiotics (amoxixillin+sulbactam and supportive therapy comprised of Nervine tonics (Neurobion) and oral feeding of banana n roasted gram and adlib ORS . Initilly the wounds were covered with sterile surgical gauges soaked in Betadine lotion . The animal was rested for the evening and was called for surgical intervention after 48hrs .After 2 days the wounds on the back and loin were lavaged trimmed and sutured under sedation using diazepam and ketamine and instillation of local anaesthetic locally. The wounds were closed using simple continuous suture pattern and synthetic absorbable suture (Vicryl no.2-0). The animal was further treated by administration of injectable antibiotics and local dressing (with ointbetadine) for the next 7 days. The animal was then sent to Ranibagh rescue centre for wild animals in distt. Nainital, Uttarkhand.

WHM-112

MANAGEMENT OF A CASE OF ELECTROCUTION, SEPTIC WOUND AND SHOCK IN MONKEY *(Macaca fasciacularis)*

J. L. Singh, Anand Kumar Singh, Sawan Kumar, Himanshu Kumar and R. S. Sandhu
College of Veterinary Sciences, GBPUAT, Pantnagar, U.S.Nagar, Uttarakhand
drjlsingh@rediffmail.com

A case of monkey was presented to Teaching Veterinary Clinical complex, College of Veterinary and Animal Sciences, Pantnagar, dated 28/11/2020, with a history of electric shock to ailing monkey four days ago. Accompanied wild animal social workers said that they found the monkey in field where animal was found in moribund and screeching condition along with expression of agony and was found lateral recumbency. An overt clinical and physical examination was conducted which revealed that the animal was severely dehydrated (15%), pallority of mucous membrane , a septic wound on both hind limbs and at the perineal region, the pus was oozing out from the wound, rectal temperature -95° F, respiration rate -25/min and heart rate - 60 bpm. Fecal examination was negative for any parasitic ova and ocyst, X-ray examination showed no fracture in limbs. The detailed clinical and physical examination concluded that the animal was suffering from electrocution and septic shock condition with a grave prognosis.

The treatment of animal was started with corticosteroid, antihistaminics, antibiotics and antiseptic dressing of septic wounds by Povidone Iodine lotion painting followed by immediate administration of 5% DNS, RL, and Normal saline solution @ 500 ml of each IV with multi vitamin infusion. After receving the treatment animal showed some signs of recovery and takes some amount of water but unfortunately after 3 hrs time the animal was died after a massive convulsive bouts.

WHM-113

MANAGEMENT OF ELECTROCUTION WOUNDS IN A LEOPARD *(Panthera pardus)* USING PULSED LAVAGE THERAPY

Upadhye S.V., Dhoot V.M., Shalini A.S., Kolangath S.M., Pawshe M.D. Bhadane B.K. and Tista Joseph
Wildlife Research & Training Centre, Gorewada, MAFSU, Nagpur
Opp. Hindustan Lever Godown Square, Mahurzhari Road, Fetri, Nagpur 441501
shirishupadhye@gmail.com

A leopard was referred to Wildlife Research and Training Centre (WRTC), Gorewada, MAFSU, Nagpur with a history of extensive wounds over both shoulders. The wounds were stained with mud and appeared contaminated. The wounds were lavaged with warm (37-39°C) one percent povidone iodine in normal saline using a 50 ml syringe and a needle to direct the jet. The jet was intermittently pulsed cranio-caudally for 10 minutes 5 times a day.The wound appeared red in the inflammatory stage and moist pink throughout the resolution phase, the edges exhibited gradual closure and epithelialization until uneventful healing on both shoulders following which the regime was discontinued. Pulsed lavage can prove a boon to the wound management especially in wild animals owing to the ease of application, reduced captive time, reduced stress and abridged use of antibiotics and supplemental pain management therapy.

WHM-114

SHELL FRACTURE REPAIR IN AN INDIAN TENT TURTLE *(Pangshura tentoria)* USING EPOXY AND FIBREGLASS MESH- A CASE STUDY

Khante G.S.*, Tista Joseph**, Ambika Arvind**, Upadhye S.V.***, and Akhare, S.B.***
* SMS Surgery, Nagpur Veterinary College, MAFSU, ** Masters Scholar (II year), Dept. of Veterinary Surgery & Radiology, Nagpur Veterinary College, MAFSU
*** Professor, Dept. of Veterinary Surgery & Radiology, Nagpur Veterinary College, MAFSU
tistajoseph@gmail.com

An Indian tent turtle was presented at the TVCC, Nagpur with history of being found on the road with a broken shell. The fracture line extended from the cranial border

of the left side of the shell caudally, eventually transversing the tent and crossing over to the right side. The chelonian retained a healthy appetite post injury. The fracture did not appear to have caused any severe internal damage. The same was confirmed via radiography. As there was visible bleeding at the fracture line, immediate surgical procedure was not performed. The fracture line was flushed with 0.1% povidone iodine daily and mupirocin ointment was applied along the fracture line twice a day for 5 days. The fragments were temporarily stabilised with cotton tape. Ceftazidime @ 50mg/kg BW SC q72hrs for a total of 4 doses (including post procedure), Meloxicam @ 0.2mg/kg once q48 hrs IM and Tramadol HCL @ 4mg/kg BW IM q48 hrs were administered (2 doses pre-surgically, 3 doses post-surgically).

The turtle was placed in water with a few drops of chlorhexidineupto the tail level 6-8 times a day, but otherwise kept out of moisture. For the surgery anaesthesia used was as follows: Ketamine@40mg/kg BW IM and Diazepam@ 0.2mg/kg BW IM. Fiberglass mesh was cut based on fracture measurements taken. Shell edges were brought in alignment manually. The mesh was placed over the fracture line and epoxy-resin (Araldite ®) was painted over the mesh. Manual pressure was continued for an hour, following which cotton tapes kept the ends apposed for 24 hours. A heating pad was used to mitigate hypothermia. Recovery was uneventful.

Radiographs were repeated post surgically on day 1 and day 30, day 60 and after one year.Day 30 showed healing along a total length equivalent to one-third of the fracture line, day 60 showed fracture line recovery along a total length equivalent to half the fracture line and one year post procedure the fracture line had healed almost completely.

WHM-115

IDIOPATHIC EPILEPSY AND ITS MANAGEMENT IN CAPTIVE SLOTH BEARS

Acharya P.R.[1], Shivani[1], Prajakta[1] Ilayaraja S[2], Baiju raj MV[5], and Arun A.Sha[4]
Wildlife SOS, India.
[1]Wildlife Veterinary officer, [2]Deputy Director Veterinary Services [3]Director Conservation Project, [4]Director of Veterinary Services and Research,
pritamchr@gmail.com

At Agra Bear Rescue Facility, two different cases of epilepsy of unknown origin were observed in captive sloth bears. Both cases were observed in adult male sloth bears in peak summer days at afternoon hours and shown almost similar signs. Incoordination, tachycardia, hyperpnoea with harsh and loud rales, left lateral recumbency and hyperthermia were prominent clinically observed signs. Both animals were noticed

during period of epilepsy in socialization fields at noon hours and were taken inside den using animal stretcher. Intravenous administration of inj. Ringer lactate was started immediately and inj. Phenytoin sodium @ 2mg/Kg.Bwt. was given along with it. Inj. Meloxicam @ 0.2mg/Kg.Bwt. i/v, inj. Tribivet @ 5 ml (Total dose) i/v & inj. Avil @ 4 ml (Total dose) i/m, was given in both cases. During treatment both animals were shifted to sternal recumbency and assisted ventilation was provided by opening the oral cavity and holding the toung in craniolateral direction. In Case 1, inj. RL (1 litre, Total dose) was administered over a period of 35 min. Gradual reduction of tachycardia and hyperpnoea was noticed, and complete recovery from episode of epilepsy was observed after one and half hour. In Case 2, inj. RL (700 ml Total dose) was administered over a period of 20 min and complete recovery was noticed on 45th min. After episodes of epilepsy both animals were quarantined, Tab. Phenytoin sodium @ 50 mg O.D. and syrup Nurokind @ 10 ml O.D. was followed for a month.

WHM-116

MANDIBULAR FRACTURE REPAIR IN AN INDIAN FLAPSHELL TURTLE (*Lissemys punctata*)

Upadhye S.V[3]., Tista Joseph[2], Ambika Arvind[2], Khante G.S.[1], and Ransingh A.[4]
Dept. of Veterinary Surgery & Radiology, Nagpur Veterinary College, MAFSU
[1] SMS Surgery, [2] Masters Scholar (II year), [3] Professor, [4]Masters Scholar (I year)
tistajoseph@gmail.com

An Indian Flapshell Turtle was presented at the TVCC, Nagpur after an automobile accident. The patient was dull with obvious cranial swelling and a broken mandible. The patient was stabilised with mannitol, intra coelomic fluids, tramadol and enrofloxacin.Radiography (dorso-ventral, ventro-dorsal and lateral views) revealed multiple fractures of the mandible.The patient was sedated with Ketamine@40mg/kg BW IM and Diazepam@ 0.2mg/kg BW IM. Pre-medication was done with enrofloxacin @ 5mg/kg BW dil. IM, meloxicam @ 0.2mg/kg IM and tramadol @ 4mg/kg BW IM and taken for surgery. Prolene 3-0 were used to join the fractured fragments. An infant feeding tube No. 4 was passed into the stomach via oesophagotomyand confirmed radiographically to be in position.The surgical site was dressed with povidone iodine and mupirocin ointment daily. Enrofloxacin q 72 hrs, Meloxicam q 48hrs, Tramadol q 48hrs. Buccal cavity lavage was performed with diluted chorhexidine. The turtle was also placed in a wet towel during the recovery period.The oesophagotomy wound was left to heal without sutures to avoid chances of stenosis. A heating pad was used to mitigate hypothermia. Feeding was performed via the stomach tube. While the mandibular fractures showed signs of healing by day 7, the turtle passed away on day 10 possibly due to extensive head trauma.

WHM-117

PREVALENCE OF INTESTINAL HELMINTHS INFECTION IN AILING PIGEONS

Panchbhai C.G., Dhoot V.M., Bhojne G.R., Kalyani Thakur, Kriti Dohre and Sameeksha C.
Department of Clinical Medicine, Ethics and Jurisprudence,
Nagpur Veterinary College, Nagpur
checkpunch@rediffmail.com

In the past few years, a number of deaths of pigeons have been reported from different parts of the country, however causes have remained unknown. This investigation is an important criterion to derive data that can be used for disease control and reduce mortality in pigeons. Helminth infections may have particularly deleterious or debilitating effects on infected birds, especially the young birds (squabs), causing retarding growth and interfering with healthy development and making older birds prone to secondary infections. The faecal samples of domestic pigeons *Columbia livia* were examined parasitologically for helminths aimed at providing information on their species composition and prevalence. A total of 1,166 pigeons were studied. The overall helminth infection observed can be specified as *Capillaria columbae* (46.42%), *Ascardia columbae* (30.35%), *Syngamus trachea* (12.5%), *Raillietina cesticillus*, (10.71%) and *Heterakis gallinarum* (8.92%).

WHM-118

AVIAN BOTULISM OUTBREAK IN MIGRATORY BIRDS - AN ABRUPT FLIGHT TO SAMBHAR LAKE, RESCUE AND REHABILITATION

Rohit Gangwal, N.V.K. Ashraf, Abhishek Narayanan, Ushma Patel, Bharghavi, Disha Sharma, , Shamshul Ali, Henna Ganjawala, Nikita Mehta, Joy Gardner and Mrugank Prabhu
Sambharlake, Rajasthan
1.Raksha, Jaipur, 2-9 Wildlife Trust of India. IFAW,
10 Hope & Beyond, Jaipur, 11. BNHS
rohit@raksha.org.in

About 18000 migratory birds were found dead at the Sambhar lake, Rajasthan. A make shift shelter was made for the birds that could be rescued alive for treatment. These birds showed signs of greenish diahrroea, lateral recumbency or sternal recumbency, hypothermia, dyspnea and thereby open mouth breathing, paralysis of the wings and legs, drooping of necks and critical birds did not respond to light when checked for pupillary reflex. On the basis of the signs and symtoms, the birds were treated for Avian Botulism

which was later confirmed by Indian Veterinary Research Institute, Bareilly and specifically of Type C strain. The bacteria can thrive in aerobic condition with high alkalinity making it a very conducive environment for binary fission of bacteria and pathogens. They were treated with oral clindamycin @50mg/kg, probiotic, vitamin B syrup, intravenous fluid therapy with warm RL @ 30ml/kg body weight, crop feeding with critical care formula, ceramic heat emitter and sling therapy. Birds showed recovery in 5-7 days and were scientifically ringed by BNHS before releasing them back at a non-contaminated fresh water lake. No repeat infections were noted. A total 1293 of 30 different species of birds were rescued out of which 514 birds were released after full recovery. Carcasses of birds were disposed in a scientific manner to reduce further spread. This exercise helped in setting up local and national SOPs for the rescue, treatment and rehabilitation of avian wildlife in view of such a humongous outbreak of botulism in future.

WHM-119

AN ATTEMPT TO TAKE NORMAL BODY TEMPERATURE IN CAPTIVE SLOTH BEARS

Acharya P.R.[1], Atul Gupta[2], Ilayaraja S[3], Baiju raj MV[4] and Arun A.Sha[5]
Wildlife SOS, India
[1] Wildlife Veterinary officer, [2]Veterinary officer, Van Vihar National Park, Bhopal[3] Deputy Director Veterinary Services,. [4]Director Conservation Project, [5]Director of Veterinary Services and Research
pritamchr@gmail.com

Per-rectal body temperature is one of the major health parameters to diagnose the disease conditions or health status of animals. Taking per-rectal body temperature in captive wild animals is really a task. Two major methods of restraining are followed in India to take per-rectal body temperature and other body parameter collection or treatment in captive wild animals i.e., physical and chemical restraining. In physical method, most commonly used technique is squeeze cage method, which generally involves lots of struggling and hyperactivity of animals into it. In chemical method, Ketamin HCL and Xylazine HCL are used @ 5 mg/Kg.Bwt. & 2 mg/Kg.Bwt. respectively to restrain the sloth bears. Both drugs are well known for their body temperature altering activity during chemical restrain of animals. In both cases, fluctuation from normal body temperature in captive wild animals is obvious and this is going to affect the diagnosis and treatment of captive sloth bears. Van Vihar Bear Rescue Facility is having a sound population of captive sloth bears. Two female and one male, adult, apparently healthy captive sloth bears were conditioned positively and per-rectal

body temperatures were taken for regular observations and those were 98.4 ^{0}F, 98.1 ^{0}F & 98.6 ^{0}F, respectively. All the three sloth bears were taken into normal cage with enough space to move animal in all directions. Honey is used as a reward treat to comfortably stand the animal into cage and per-rectal temperature were taken through a window using digital thermometer for minimum 45 sec. Hence, positive conditioning the captive sloth bears for obtaining per-rectal temperature is best and reliable method compared to physical and chemical restraining which involves high stress to the animal and chemical fluctuation of body temperature.

WHM-120

OESOPHAGOTOMY IN AN INDIAN FLAPSHELL TURTLE (*Lissemys punctata*) FOR REMOVAL OF FISH HOOK

Tista Joseph[4], Upadhye S.V.[1], Ambika Arvind[4], Adey K.[5] Khante G.S.[2], Amit Kshirsagar[3]and Aditya Singh[4]
Dept. of Veterinary Surgery & Radiology, Nagpur Veterinary College, MAFSU
[1]Professor, [2] SMS Surgery, [3]PhD Scholar, [4]Masters Scholar (II year),
[5] Masters Scholar (I year)
tistajoseph@gmail.com

An Indian Flapshell Turtle was presented at the TVCC, Nagpur with history of a fishing thread hanging from the mouth. The patient was active and alert and was suspected with accidental fish hook consumption. Radiography (dorso-ventral, ventro-dorsal and lateral views) post sedation with Ketamine@40mg/kg BW IM and Diazepam@ 0.2mg/kg BW IM revealed a fish hook lodged in the cervical region, positioned ventro-laterally to the left. The patient was pre-medicated with enrofloxacin @ 5mg/kg BW dil. IM, meloxicam @ 0.2mg/kg IM and tramadol @ 4mg/kg BW IM and taken for surgery. Oesophagotomy was performed via a left lateral approach and after palpating and grasping the hook externally. The hook was removed. The oesophagotomy wound was left to heal without sutures to avoid chances of stenosis. A heating pad was used to mitigate hypothermia. Recovery was uneventful. The patient was kept nil by mouth for 5 days, with adequate intra-coelomic fluids provided. The surgical site was dressed with povidone iodine and mupirocin ointment daily. Enrofloxacin q 72 hrs, Meloxicam q 48hrs, Tramadol q 48hrs. The turtle was also placed in a wet towel during the recovery period. Suture site recovery was complete by day 10 and the patient started consuming normal diet by day 15.

WHM-121

INTESTINAL OBTRUCTION IN ELEPHANTS

A.G Dubey, N. Lakshminarayanan and AS Kumar
Wildlife Institute of India, Dehradun, Uttarakhand
drankushdubey@gmail.com

There are plenty publications available on nutritional requirement of the elephants but still, it is little known about requirement and nutritional physiology (Olson D 2002). The elephant has a Glandular stomach present on left side but involves less in the digestion process. The microbial digestion of cellulose takes place in the sacculated caecum-colon. Cecum is named as a first important site of fermentation, next is duodenum and colon due to richness of protozoa. enlarged colon allows microbial fermentation of fibrous diet. the fermentation process of the elephant is similar to other herbivorous species.

Benedict & Lee (1938) documented that only 40 % of food consumed by elephant gets digested due to which they are in continuous search of food to maintain their body weight. Wild elephantsconsume large variety of grasses, tree leaves, twigs, barks of trees, roots, fruits and even flowers. Captive elephants received balanced ration according to the feeding chart. Gastrointestinal impaction or Intestinal obstruction is disease condition affect elephant in any stage of life, it is moreover of dietary origin. Partial or complete obstruction, volvulus or intussusception, aerophagia, improper mastication, restricted movement with lack of exercise, Tendency of mahout is to feed and water immediately after walk are some of the causes. Head pressing, stretching, borborygmi, abdominal distension and repeatedly lie down and stretch are some common signs. Feeding of a purgative/ laxative can be effective in the initial stage, oral administration of Liquid paraffin works fine. Administration of Flunixinmeglumine, calcium pantothenate, Metaclopramide increases the peristalsis, calcium borogluconate can be effective. Intravenous Fluid should be given for rehydration, Parasympathetic stimulant should be used like Carbachole. Per-rectal administration of lukewarm fluid and electrolyte solution is very effective for rehydrating animal. laxative and stools softeners like mineral oil can also be added during per-rectal administration of fluid.

WHM-122

MANAGEMENT OF UROPHAGIA INDUCED BALANOPOSTHITIS IN CAPTIVE SLOTH BEARS

Acharya P.R.[1], Shivani[1], Prajakta[1] Ilayaraja S[2], Baiju raj MV[5] and Arun A.Sha[4]
Wildlife SOS, India
[1] Wildlife Veterinary officer, [2] Deputy Director Veterinary Services, [3]Director Conservation Project, [4]Director of Veterinary Services and Research
pritamchr@gmail.com

Agra Bear Rescue Facility is world's largest rehabilitation facility for rescued sloth bears which accommodating the major population of captive sloth bears in India. Urophagia is considered as one of the vices encountered generally in captive male sloth bears. Balanoposthitis is a common sequel of urophagic behaviour, which in severe cases may affect urogenital system and leads to secondary complications associated with it. In this abstract we are discussing four cases of urophagia induced balanoposthitis in male sloth bears and its management. Case 1&2 were observed as moderate inflammatory swelling at urethral tip with both animals showing intermittent urophagic behaviour. Topical pouring of 2ml Neem Seed Oil (*Azadiracta indica*) is done thrice daily. Remarkable effect is observed with reduced swelling and frequency of urophagia on very next day which supposed to be due to anti-inflammatory activity and acrid taste of NSO. Case 3 was diagnosed with mild balanoposthitis with initial development of urophagic behaviour due to boredom in captivity. Use of structural, environmental and feeding enrichments and positive conditioning of animal showed impressively increased animal activity and reduced urophagic behaviour. Case 4 was a typical urophagia induced balanoposthitis complicated with secondary maggot infestation. Using positive conditioning manual removal of maggots from site was done and flushing of cavity with ice cold normal saline and maggoticidal & fly repellent spray was done. Animal was recovered completely on 24th day uneventfully. However, above four cases in captive sloth bears shown complete recovery, still causes and recurrence of urophagic behaviour is a topic of furthermore study.

WHM-123

SURGICAL REPAIR OF TRAUMATIC CROP FISTULA IN A PIGEON (*Columba livia*)

Rajesh kumar[1] Aakanksha[2] N.K. Verma1 and M. hoque[3]
Division of Veterinary Surgery & Radiology, IVRI Bareilly (UP)
[1]. Ph D Scholar, [2]. PG Scholar, [3]. Principal Scientist
vetrajeshkumar@rediffmail.com

The crop is a muscular pouches which extent from oesophagus in the birds. Crop allows birds to eat large amount food in a single sitting. When the crop is full of food, it is often susceptible for trauma. Penetrating wounds can result in formation of fistula in the crop. A pigeon was reported to refferal Veterinary Polyclinic of Indian Veterinary Research Institute, Izatnagar having history of oozing of ingested feed below neck region. It occurred due to injury with cat nail. Careful clinical examination revealed oozing of feed content from damage crop, but not internal damage was observed. Based on history and clinical examination, it was diagnosed as a case of crop fistula and decided for surgical repair. General anaesthesia achieved by Ketamine 60.0 mg/kg body weights intramuscularly. The ruptured crop edges were freshened and closed by using no. 3-0 vicryl. Skin was closed routinely with polyamide by cross mattress suture. Post-operatively advice Syr. Cefpodoxime proxetil 5 drops twice for 5 days and Syr. Meloxicam 2 drops daily for 3 days. Bird fully recovered after 8 days without any complication.

WHM-124

SUCCESSFUL AMBULATION AFTER TIBIAL FRACTURE REPAIR BY EXTERNAL COAPTATION IN INDIAN PEAFOWL *(Pavo cristatus)*

S. S Vende, S. S. Pawar, G. S. Khandekar, S. A. Chauhan, S. V. Gaikwad., A. Barate and G. V. Pande.
Veterinary Polyclinic Nashik
drvendevet@gmail.com

An Indian peafowl (Pavo cristatus) was presented to Veterinary Polyclinic Nashik with a history of lameness in the left leg with no weight bearing. Xray reveals fracture diaphysary, overriding transverse in the upper one third and an impacted fracture at lower one third of Left Tibia by breaking the bone in three long fragments. The fracture was reduced by traction and counter traction under the general anaesthesia with Ketamine hydrochloride @ 15-20 mg/kg body weight. The anaesthesia lasted for 20 to 25 minutes until the cast was applied and the complete recovery was observed in 30 minutes.

The left limb was immobilized with external coaptation for 21 days and the bird started slight weight bearing. X Ray on 21st day revealed endosteal callus formation in the distal fracture however there were overriding fracture fragments with the periosteal callus in the proximal fracture, hence the bird was replastered. Complete recovery with weight bearing and ambulation was observed on 32nd day post injury however with the complication of slight limb shortening. From the case it could be concluded that the limb fractures could be treated efficiently with external coaptation under ketamine anaesthesia when the other fixation techniques are unavailable.

WHM-125

SUCCESSFUL MANAGEMENT OF VARIOUS SURGICAL AFFECTIONS IN REPTILES - A RETROSPECTIVE STUDY

S. D. Raibole, Dharma. Raibole, G. S. Khandekar, S. A. Chauhan, S. D. Tripathi, V. Nimbalkar and G. S. Khandekar.
Mumbai Veterinary College, Mumbai,
Maharashtra Animal and Fishery Sciences University
ssalvekar@gmail.com

Traumatic injuries are the most common surgical affections seen in reptiles, especially in snakes that are found in the human vicinity. Snakes versus human conflicts are possibly the oldest and largest examples of the human - animal conflicts reported. The injuries mostly involved vertebral fractures, evisceration wounds, head injury, jaw fractures, burn wounds in a variety of reptiles like Indian king cobra (2), Indian rock python (2), rat snake (1) etc. Few other surgical conditions like growth in sand boa, abscess in indian rock python and congenital case of two headed russell's viper was also reported. Basic treatment principle being the same as other animals however reptiles being the cold blooded creatures, and the metabolism of the anesthetic drugs and the drugs used strictly depend on the external conditions provided. Therefore this paper includes the cases reported in clinical practice of the most populated city of Mumbai which surprisingly included a variety of venomous and non venomous snakes and monitor lizards, theri anaesthesia, post operative care, immobilization and the challenges faced in treating them.

WHM-126

SUCCESSFUL MANAGEMENT AND POST-OPERATIVE CARE OF RUPTURED EPULIS IN CAPTIVE DANCING SLOTH BEAR

Acharya P.R.[1], Shivani[1], Prajakta[1] Ilayaraja S[2], Baiju raj MV[5] and Arun A.Sha[4]
Wildlife SOS, India
[1] Wildlife Veterinary officer, [2] Deputy Director Veterinary Services, [3]Director Conservation Project, [4]Director of Veterinary Services and Research
pritamchr@gmail.com

Epulis i.e. swelling of gums, in rescued dancing sloth bear is one of common oral cavity affections. A case is reported at Agra Bear Rescue Facility with rupture of epulis due to infighting in captive sloth bears. A 25 years old, male sloth bear was observed with bleeding and hanging hard tissue mass from oral cavity at right premolar region. Using positive conditioning topical spraying of inj. Adrenaline and 10% lidocaine spray, hanging mass was removed by forcep providing torsion at pedicle, followed by a thorough oral cavity flushing with chlorhexidine solution. Bolus Styplon @ ½ O.D. for next three days was continued. Antibiotic Tab. Moxikind CV @ 1 Tab. O.D. for next seven days and pain management was done with Tab. Rutoheal @ 1 Tab. B.I.D. & Bolus Melonex @ ½ O.D. for next five days. Addition to these, animal was isolated in a concrete floor den for next seven days to prevent mud digging and foraging activity which may create chance for secondary bacterial infection. Therapeutic diet was planned for a month with only liquid diet for initial three days, i.e. a litre of milk, curd, and watermelon juice was provided by intervals. Forth day onwards, 4 to 4.5 kg semisolid porridge with added milk was provided twice daily and 2 kg pulp of watermelon once daily, was followed for a month. Since the day 0, flushing of oral cavity with chlorhexidine solution after each meal was strictly followed.

WHM-127

METASTATIC HEMANGIOSARCOMA IN A ROYAL BENGAL TIGER

Chandrashekhar S. Mote[1*], R.V. Jadhav[2], V.S. Dhaygude[1], B.P. Kamdi[1],
N.K. Nighot[2] and Divya Sabharwal[1]
1. Department of Veterinary Pathology, Krantisinh Nana Patil College of Veterinary Science, Shirwal, Satara, (MS), 2. Rajiv Gandhi Zoo and Wildlife Research Center, Pune, (MS)
drcsmote1@gmail.com

A male Royal Bengal Tiger (*Panthera tigris tigris*) of 12 years was presented for necropsy with clinical history of anorexia and dullness for more than 2 weeks. A systemic necropsy was performed for gross pathological lesions which revealed diffuse

spread of metastatic neoplastic masses in multiple vital organs and lymphatic organs. The lungs showed diffuse spread of neoplastic round masses of 0.5 to 1 cm size on the surface. The liver showed presence of variable sized round dark brownish coloured masses with soft and pulpy consistency. Cut open parenchyma of liver and lung also showed presence of small to large sized brownish coloured round growths. The myocardium of left ventricle also showed presence of metastatic growths of tumours masses of brown colour. The spleen and lymph nodes remarkably showed presence of variable sized round masses which were raised on the surface. The lymphnodes of mesenteric region as well as from sub-cutaneous tissue were enlarged with irregular surface with degenerative, necrotic and hemorrhagic features on cut surface with presence of reddish brown coloured semi-solid content in the parenchyma. Tracheal lumen also showed presence of small to medium sized brown coloured masses in the mucosal linings. Pancreatic tissue showed diffuse presence of multiple round to oval neoplastic masses. The mucosa of urinary bladder showed small sized metastasized masses. The histopathological examination of neoplastic masses in various organs showed highly vascularized tissue with accumulation of RBCs in lumen suggestive of hemangiosarcoma. Liver showed variable sized masses in the hepatic parenchyma with congested and dilated blood vessels. Splenic tissue showed presence of numerous blood vessels as a part of neoplastic tissue mass. The lung, liver, spleen, and pancreas showed neoangiogenesis with large sized vascular endothelium with karyomegaly and presence of mitotic figures in the nucleus of endothelium and pleomorphism of vascular neoplastic endothelium. Based on the gross and histopathological observations, it was diagnosed as a case of hemangiosarcoma with diffuse metastatic spread in abdominal and thoracic cavity in a tiger.

WHM-128

MANAGEMENT OF PORCUPINE QUILL INJURY IN WILD TIGER CUB IN TIPESHWAR WILDLIFE SANCTUARY, MAHARASHTRA

Chetan Patond[1], Ravikiran Govekar[2], Subhash Puranik[3] and Sandip Chavan[4]
[1]Veterinary Officer, Pench Tiger Reserve, Nagpur, M.S., [2]CCF and FD, Pench Tiger Reserve, Nagpur, M.S., [3]DFO, Pandharkawda Forest Division (WL), Pandharkawda,[4] ACF, Pandharkawda Forest Division (WL), Pandharkawda
drchetanpatond@gmail.com

Two male Tiger cubs were separated from the tigress TWLS T1 at the age of 10 months during December 2019. These cubs were not experienced enough to hunt the wild prey. One of the cubs tried to kill a porcupine; instead he received several porcupine quills on the face, neck and the oral cavity. The cub tried to remove those quills for next

few days. He managed to take out many quills but not all.Considering it as a natural phenomenon, cub was observed for couple of weeks. On close observations, it was noticed that the cub was mostly immobile, weak and emaciated and was not able to hunt. More importantly his male sibling, who was constantly accompanying him throughout this period, also stopped moving away from the injured cub or hunting. Considering the threat to the life of both the cubs due to this atypical situation, it was decided to intervene. The injured cub was rescued by tranquilizing it with combination of Inj.Xylazine and Inj.Ketamine @ 1.5 mg/kgand 2 mg/kg body weight respectively using a syringe projector. Porcupine quills were removed from the face, oral cavity, paw region and ventral abdomen. The quills had caused abscessesat various places. The abscesses were drained and wounds were flushed, cleaned and dressed. Anti-inflammatory and antibiotics along with multivitamins were administered, followed by administration of reversal agent Inj. Yohimbine@0.125mg/kg. The Tiger cub was kept under observation in cage. The cub consumed good quantity of meat, water and supplementary medicines orally through the meat. After confirming his healthy behaviour, he was released in the same area after 24 hours. Feeding support was given in the wild for about two weeks. Presently, both these cubs are surviving in the wild on their own. Minimum human intervention at right time have saved the life of cub. These kinds of field approaches can help to save the life of the Tigers with minimum captivity period with minimum stress.

WHM-129

PALLIATIVE AND REHABILITATIVE SILICON BASED PROSTHETIC FLIPPER FOR A LARGE OLIVE RIDLEY SEA TURTLE " VASUNDHARA"

S. B Walvekar, G. S. Khandekar, S. A. Chauhan, C.Halyal, K. R. Powar, V. Kamble and S. Sawant
Veterinary Polyclinic, PON, Kolhapur circle,
Maharashtra Forest Department
ssalvekar@gmail.com

Silicon is an non biodegradable, long lasting, chemically inert biomaterial A large olive ridley sea turtle named Vasundhara was brought to the Veterinary polyclinic, PON, Kolhapur circle, Maharashtra Forest Department with the amputated 3/4th of the left front flipper due to old injury and the hind flipper was also brutally damaged due to its entanglement in the net . The residual limb measurements were taken and a baseline design was achieved by tracing the right flipper that was mirrored exact in the clay medium. Further a mould was prepared with the dental plaster and the design of the flipper was armature in the metal wires, to which the silicon was poured to prepare a proper shaped, light yet sturdy flipper. The flipper was designed and tested for

hydrodynamics and displacement and was very similar to the turtle's natural flipper. It could be concluded that the prosthetic flipper thus prepared was comfortable, durable and safe for vasundhara and allowed her to swim effectively and move freely in the large water bodies.

WHM-130

SURGICALLY CORRECTION OF TRAPPED FISHING HOOK IN INDIAN SOFTSHELL AND INDIAN NILSSONIA TURTLE

S. B. Walvekar, G. S. Khandekar, S. P. Salvekar, S. V. Sonawale, R. R. Mestri Sutar and A. D. Kumbhar, D. H. Bhosale and A. V. Suryawanshi
Veterinary Polyclinic, PON, Kolhapur circle, Maharashtra Forest Department
ssalvekar@gmail.com

A total 7 turtles were there 6 were Indian softshell turtle and one was Indian Nilssonia turtle. All were suffering due to trapped fishing hook in mouth and neck region. Out of these four were treated by performing open surgical method and remaining three already had the hook pierced through in skin which was removed by using micro motor. During these surgeries all the turtles were anaesthetized with Ketamine @ dose rate of 5mg/Kg. Post-operative pain management by Meloxicam @ 0.2mg/Kg and antibiotic Enrofloxacin @10-15mg/Kg. After recovery safely released in their habitat.

WHM-131

CORRECTION OF FRACTURED WING BONES IN WILD BIRDS BY MEDULLARY PINNING

S. B. Walvekar, V. Climent Ben, G. S. Khandekar, R. R. Kale, S. P. Salvekar, V.D. Kamble, S.V. Sawant, R. R. Mestri Sutar, A. D. Kumbhar, S. Y. Harale and A. S. Kulkarni
Veterinary Polyclinic, PON, Kolhapur circle, Maharashtra Forest Department
ssalvekar@gmail.com

20 wild birds with history of humeral wing bone fractured were presented, out of which 16 wild birds including 5 Black kite, 2 Brahminy Kite, 4 Mottled wood owl, 3 Grey Heron, 2 Little Banded Goshawk were selected for medullary pinning. During medullary pinning, bird were anaesthetized by ketamine 10-15mg/kg. Post-operative pain management by Meloxicam 0.2mg/Kg and antibiotic Enrofloxacin @ 10mg/Kg.out of 16,

11 were successfully treated and released and 5 were retained due to post-operative complications like septicemic stress and disturbed fracture setting due to excessive wing movements.

WHM-132

SUCCESSFUL CLINICAL MANAGEMENT OF DYSTOCIA IN NANITI SNAKE

S.S.Pawar and Vende S.S.
Veterinary Polyclinic, Nashik
sspawar339@rediffmail.com

Herpetology is a rapidly growing interest in this country, reptiles being kept both for research purposes and as pets. Breeding snakes for fun and/or profit is becoming common place for reptile enthusiasts. Complications with laying eggs or giving birth to young are common sequelae of breeding snakes. A clinical case of Naniti snake breed was presented at Veterinary Polyclinic Nashik having symptoms of swelling at anus region and Owner was complaining about the difficulty in free moving of the snake. On clinical examination snake was found with eggs obstruction. After proper diagnosis, decision was made to apply Pendistrin-SH tube for the proper lubrication to remove the obstructed eggs and with this proper lubrication all the eggs were removed gently one by one. After relieving the eggs snake was completely recovered. By viewing this case it was concluded with the thought thatt the consulting veterinarian should be familiar with the literature on the common methods for initiating breeding activity and cycling, gestation, fecundity, and incubation techniques for the various species of snakes seen in practice.

WHM-133

MANAGEMENT OF OUTBREAK OF HAEMORRHAGIC SEPTICAEMIA AND CHRONIC FASCIOLOSIS IN SPOTTED DEER *(Axis axis)*

M Karikalan, K. Mahendran, Hira Ram[1], Chandra Mohan S, M Saminathan[2], KN Viswas[3] and A.M. Pawde
Centre for Wildlife Conservation, Management and Disease Surveillance
ICAR- Indian Veterinary Research Institute, Izatnagar 243 122 UP India
[1]Division of Veterinary Parasitology, [2]Division of Pathology
[3]Division of Bacteriology & Mycology
karyvet11@gmail.com

Mortality of six spotted deer *(Axis axis)* in three days of duration (July 2019) was recorded in small deer park, Bareilly. The clinical signs observed were depression, excessive salivation and a profuse serous nasal discharge, dyspnoea, edematous swelling

in the submandibular region and neck. All the carcasses were systematically necropsied. The gross lesions were consistent with severe sepsis and characterized by widespread haemorrhages, edema and hyperaemia. Subcutaneous edema was found in the submandibular region and neck. The thoracic and pericardial sac contained serous to serofibrinous fluid. Ecchymotic haemorrhages were found, particularly on the epicardium of the heart. The lungs were diffusely congested and edematous and had haemorrhages. Foam was also found in the airway. Petechial to ecchymotic haemorrhages were also noticed in all the visceral organs. The liver was very hard to cut and had multiple calcified nodules, i.e cut surface flukes were noticed. Heart blood, serofibrinous fluid and lung were collected on ice for bacterial isolation. All the major visceral organs were collected in 10 % formalin for histopathological examination. A fluke in the liver was collected in 70% ethanol. Impression smears from heart and lung revealed bipolar organisms on Giemsa staining. *Pasteurella multocida* type B were isolated using blood agar culture from heart blood and lung tissue and also further it was confirmed by PCR based on capsular antigen serotyping. Histopathological examination revealed serofibrinous bronchopneumonia and severe sepsis in all the visceral organs. The liver showed severe fibrosis around the bile duct with multifocal areas of calcification. Some of the bile ducts had adult Fasciola fluke. The accompany animals which survived were isolated and treated with parentral injection of flunixin meglumine 50mg, enrofloxacin 100 mg and dexamethasone 8mg intramuscularly. Further, the complete herd was dewormed using triclabendazole 120 mg and levamisole 75mg per 10 kg body weight. The present investigation describes the pathology of haemorrhagic septicaemia in spotted deer *(Axis axis)* with chronic fasciolosis and successful management under captivity.

WHM-134

RECOVERY OF AIR GUN PELLETS FROM RESCUED LEOPARD AT POST-MORTEM EXAMINATION

Pawshe M.D., Kolangath S.M., Upadhye S.V., Dhoot V. M., Shalini A.S. and Megha Kaore
Wildlife Research & Training Centre, Gorewada, Nagpur
Opp. Hindustan Lever Godown Square, Mahurzhari Road, Fetri, Nagpur 441501
drmayurpawshe@gmail.com

An Adult female leopard was found paralyzed at Arjuni Dist. Gondia by department of Forest, Maharashtra. The animal was rescued and shifted to Wildlife Research & Training Centre, Gorewada, Nagpur for treatment and care. The animal succumbed to the injuries after 10 days. Prior to the post mortem, radiological examination of the carcass was performed, which indicated round radio-dense objects

lodged subcutaneously in the neck, thigh and lumbar region of the carcass. During the post mortem examination four air gun pellets were recovered from the carcass. The findings highlight the prevalence of use of air gun to deter endangered leopard population in protected areas.

WHM-135

MANANGEMENT OF COLIC IN AN ORPHANED NILGAI CALF (*Boselaphus tragocamelus*)

Pawshe M.D., Shalini A.S., Upadhye S.V., Dhoot V.M., Kolangath S.M., Bhojane G.R., and Gawande A.P. and Bhadane B. K.
Wildlife Research & Training Centre, Gorewada, MAFSU, Nagpur
Opp. Hindustan Lever Godown Square, Mahurzhari Road, Fetri, Nagpur 441501
drmayurpawshe@gmail.com

An orphaned Nilgai (*Boselaphus tragocamelus*) calf was presented to Wildlife Research & Training Centre, Gorewada, Nagpur for care and rehabilitation. During the care the calf was found dull and separated from the rest of the calves and showed signs of inappetence. The calf was clinically examined, the temperature was normal, conjunctival mucous membranes were moist pink and appeared mildly bloated. The calf was seen kicking its abdomen and showed signs of uneasiness. The calf was given 10 drops of syrup containing Dill Oil, Fennel Oil and Simethicone bid, Syrup Ofloxacin and Metronidazole and Inj. Flunixin Meglumine and the calf was house separately to check for urine and feces. The treatment was continued until the calf showed progress in feeding and passed feces and urine normally. The report highlights prompt veterinary intervention and distress management in cases of colic in neonate herbivores.

WHM-136

SUCCESSFUL MANAGEMENT OF SUBCUTAEOUS ABCESS IN A NILGAI CALF

Pawshe M.D, Shalini A.S., Upadhye S.V., Dhoot V.M., S.M. Kolangath, Bhadane B.K., Gawande A.P. and Patil M. S.
Wildlife Research and Training Centre, Gorewada, Nagpur
Opp. Hindustan Lever Godown Square, Mahurzhari Road, Fetri, Nagpur 441501
drmayurpawshe@gmail.com

A two month Nilgai calf was brought at Wildlife Research and Training Centre, Gorewada, Nagpur with the history of inappetence and pyrexia. Physical examination revealed a large pus filled mass hot, foul smelling abscess, soft in consistency was found

at the left lateral region of the lumbar region. Hematological examination revealed that all the parameters were within normal ranges. The abscess was drained and cleaned with Povidine iodine along with parenteral administration of Inj. Intamox and Inj. Melonex for 5 days with daily dressing of abscess. The calf successfully recovered after two weeks of treatment.

WHM-137

ANCYLOSTOMUM INFECTION IN A SLOTH BEAR- A CASE REPORT

Pawshe M.D., Shalini A.S., Dhoot V.M., Upadhye S.V., Bhojne G.R., S.M. Kolangath and Kolte S.W.
Wildlife Research and Training Centre, Gorewada, Nagpur
Opp. Hindustan Lever Godown Square, Mahurzhari Road, Fetri, Nagpur 441501
drmayurpawshe@gmail.com

A female Sloth bear, approx. 3 yrs at Gorerwada Rescue Centre, Nagpur had a history of inappetance, profuse vomition and loose tarry faeces since one day. Clinical examination viz. Temperature, RR, HR was within normal ranges. The fecal sample examination inclusive of egg per gram was done and it was found to be positive for Ancylostomum ova. The Sloth bear was treated with Tab. Nemocid 250mg per orally once and Inj. Rantac and Inj. Odensetron were given intramuscularly for three days. Fecal samples were taken on 3rd and 21st day after treatment. The sloth bear had an uneventful recovery.

WHM-138

SUCCESSFUL REMOVAL OF FOREIGN BODY OBSTRUCTION (BONE) FROM THE ORAL CAVITY OF A FEMALE TIGRESS

Shalini A.S., Upadhye S.V., Dhoot V. M., Pawshe M.D., Gawande A.P., and Kolangath S.M.
Wildlife Research and Training Centre, Gorewada, Nagpur
Opp. Hindustan Lever Godown Square, Mahurzhari Road, Fetri, Nagpur 441501
a.sshalini@yahoo.com

A female tiger of about 5 yrs at the Gorewada Rescue Centre, Nagpur was found struggling to remove a piece of bone lodged in the oral cavity. As the tigress was not able to remove the piece of bone on its own, the tigress was taken inside the treatment cage with huge efforts. The Tigress was examined and it was found that a large femoral head bone was penetrated deeply into the right lower canine. The bone was carefully dislodged manually and was successfully removed without anaesthesia.

SESSION-IV
ZOO BIOLOGY
&
CONSERVATION

TEACHING HUMANE CARE: IMPROVING ELEPHANT WELFARE

Steve Koyle
Founder Elephant Care
Ex-animal keeper phoenix zoo
steve.koyle@elephantcareunchained.com

Asian elephants which were once widely distributed across Southeast Asia have now shown a dramatic decline in their population owing to habitat fragmentation, poaching, man-animal conflict *etc*. There are four subspecies of Asian elephants namely, Indian, Sri Lankan, Sumatran and Borneo. The Indian subcontinent is home to majority of the Asian elephant population. There is also a fair captive population of elephants in Asia which include zoo elephants, rescued elephants due to natural calamities or human-animal conflict, forest elephants, elephants used for joy rides, temple elephants, elephants used in the logging industry *etc*. These elephants come to the captive environment at different stages of their lives, either as young as a few month old orphaned calf or as adolescent crop raiders or even as old circus elephants.

Asian elephants are known to have complex individual personalities and are also highly intelligent. Some elephants are docile and inquisitive while some are tough and aggressive. Studies show that they are able to demonstrate compassion, grief, strong maternal instinct and close knitted herd behavior, mind blowing problem solving abilities and long term memory. Getting such intelligent animals habituated to daily handling for their care and management in captive conditions therefore requires skill and patience and this is where elephant keepers/ care takers play a significant role. The bond between the elephant and the keeper has a great impact on their welfare.

In this article, we will discuss on few aspects of Captive Elephant Welfare
Keeping space and financial constraints in mind: Enrichment:

Wild elephants spend most part of their day foraging in the forests which involves walking long distances, use of their sensory organs, use of their trunk and neck muscles to grasp branches and leaves from trees, *etc.* The rest part of the day is spent socializing with the other elephants, mud bathing, playing and sleeping. In captivity, with little or no activity, elephants tend to develop stereotypic behaviour like swaying and head bobbing. It is therefore important to plan various enrichment activities for the captive elephants keeping in mind their natural behaviour.

In captive conditions, the exhibits can be designed to accommodate structures which will serve as enrichment points for the elephants, for example, water ponds for

bathing and cooling off during Summer, a mud patch for mud baths, erect poles which can be used to hang sturdy enrichment toys like wooden barrels with hay, rubber tyres, bells *etc.* to push and pull. Large rough bristled sweeping brushes drilled on walls or tied around trees can serve as a scratching post. Dietary enrichment can include whole tender coconut, water melons, pumpkins *etc.* for them to trample and eat the juicy part of the fruits. Scattering feed items on their exhibit ground and hiding feed items which are not part of their daily diet in huge card board boxes or earthen pots can also be used as dietary and behavioural enrichments. Small berries and nuts can be hidden in bamboo with small holes so that every time the elephant flicks the bamboo with its trunk it'll be rewarded with the berries and nuts. To stimulate the olfactory senses, different scents can be used to mark in their exhibits like rubbing lemon grass, mint leaves, honey, urine of other animals, *etc*. on walls or enrichment poles. Engaging the elephants in these activities can serve as an alternative for the physical energy they usually spend during foraging in the wild and also help the of use neck muscles which is less used in captive elephants.

Keeping human-animal bonding and healthcare at all stages of life and illness in mind: Positive Reinforcement Training (PRT) and Target Training:

In Asia, negative reinforcement methods were used in traditional training of elephants. These methods included developing fear in elephants by inflicting pain using pointed iron sticks (ankush) or bamboo sticks to make the elephant perform certain tasks as simple as sitting, lying down, lifting *etc.* These methods mentally break them down and can be a very stressful experience. Such animals can turn aggressive and lack trust in humans making them less cooperative during routine health checks and treatments which are very important in captive conditions.

Elephants being highly intelligent species with a good memory can have a positive or negative lifelong relationship with their keepers depending on how they were trained. It is therefore important to bring changes to the age old training practices and introduce positive reinforcement methods. In positive reinforcement methods, the fear component is replaced by a pleasant reward every time the elephant performs a desired task. This in turn stimulates their problem solving abilities, creativity, decision making *etc*. Using positive reinforcement, captive elephants can be trained to be cooperative during veterinary procedures like drawing blood, trunk wash, administration of medications, examination of feet *etc*. This method has also proved to be useful in training dominant elephants to accept a new elephant in its herd. A strong positive elephant and keeper bond is not only rewarding for the elephants but also leads to a great degree of job satisfaction for the keeper.

Elephant Foot-care in brief:

In the wild, elephant feet undergo natural pedicure due to their constant movement on different terrain like rocky areas, soft soil cover, swamps *etc*. Elephant foot has a large fat pad concentrated at the heel. While the elephant walks on its tiptoes, their body weight is evenly distributed across the fat pad of the heel thereby reducing foot pressure. In most captive set ups, the night shelters have hard concrete floors which means the elephant has to spend the night hours on the hard surface. Less wear and tear can result in overgrown toe nails leading to increased pressure on the tip of the toe nail causing cracks on them. Moreover, their urine and feces get accumulated on the hard floor surface and can be a source foot pad infection. Foot diseases are evident only at the later stages making treatments challenging and therefore routine feet inspection and foot care are very important.

Elephants new to foot care can be trained by following few short routine foot checks and trimming after bath since the sole and toe nails are softer after bath. During the foot care procedures the elephant can be rewarded with treats whenever it is compliant to the keeper's orders and can also be fed the routine feed to keep it distracted. After a number of such short routine checks and procedures, the elephant will be cooperative and the foot care time can gradually be increased.

Basic foot inspection involves checking the length of the toe nails and cuticles, checking the foot pad for open wounds and cracks and checking for dirt filled cracks on the toe nails and between the lamellae. Keeping hoof trimming tools including a hoofknife, rasper and a small blade is mandatory for elephant foot care. Long toe nails can either be rasped or trimmed and rounded using a hoof knife. Overgrown cuticles are usually controlled by the elephants by rubbing the foot on its opposite leg. Applying neem or vegetable oil to the cuticles will soften the cuticles and make the process easier. The cracks on the sole and heels caused by moist floors can be debrided to prevent easy bacterial entry. Use of KMnO4 wash or povidone iodine irrigation along with oral/parenteral medications can prevent major foot problems. Toe nail and sole trimming should be carried out once a month.

Elephant care and management thus involves multiple aspects which can be humanely carried out without causing much stress to the elephants by maintaining a good elephant and keeper relationship.

ZBC LP-2

FROM THE KILLER SNARES TO THE ACTIVE RADIO-COLLARS: THE MANAGEMENT OF SNARE INJURIES IN TIGER (*Panthera tigris)* AND STUDYING THEIR DISPERSAL IN TIPESHWAR WILDLIFE SANCTUARY, MAHARASHTRA, INDIA.

[1*]**Ravikiran Govekar**, [2]Parag Nigam, [2]Bilal Habib, [1]Chetan Patond, [1]Pramod Panchbhai and [1]Sandip Chavan.
([1] Pench Tiger Reserve, Nagpur, Maharashtra; [2]Wildlife Institute of India, Dehradun.)
govekiran@yahoo.com

The policy level initiatives taken by the governments, the legal protection provided, the systematic and scientific management practices and the other proactive conservation measures which have been taken up for over past four decades have resulted in increase in the numbers of tiger, other co-predators and their prey species in India. This increased number however resulted into increased human-wildlife negative interface cases in some of the tiger bearing areas. Wild animals started using the human dominated landscape for the food, water and dispersal. Crop depredation by the wild herbivores prompted the farmers to indulge in illegal activities such as killing the animals by electrocution, poisoning, snaring etc. Often, these illegal techniques are also used for purposeful hunting. Wild animals often fall prey to different types of traps and snares deployed in the forests bordering the agricultural areas. Sometimes, the tigers get trapped in the snares set up for the herbivores. If timely action is not taken, these snares can lead to the death of the animals. Such snares have been a great threat throughout the tiger range countries in Asia. Prompt action and wise management can lead to a normal and healthy life of the injured animal. We have discussed in this paper two such cases of the rescue of the sub-adult tigers, their treatment and radio-collaring and post-collaring dispersal in Tipeshwar wildlife sanctuary during the period February 2019 to March 2020.One of the two tigers has created a world record of walking the longest recorded distance of over 3017 km in 13 months. The third case study of the mortality of a female tiger due to the snare injury is also discussed.

Tipeshwar wildlife sanctuary is an important protected area in Vidarbha, Maharashtra, with an area of 148.62 sq. Km. It is an undulated landscape with a dry deciduous forest habitat having predominance of teak forest. Tipeshwar falls in Tadoba landscape and is connected with Tadoba-Andhari Tiger Reserve, Kawal tiger Reserve and Painganga Sanctuary through the forested corridors. At present (2020) there are 5adult and 9sub-adult tigers.(DFO WL Pandharkawada. Commu.). The sanctuary is surrounded by 20 villages within a distance of 2 km from its boundary and therefore forest-agricultural area interface is very prominent, resulting into tigers often venturing into

agricultural areas for cattle depredation. After the reporting of three cases as described below, several anti-snare drives were implemented and efforts were made to minimize the chances of animals being snared. No other incidence of tiger being snared was reported thereafter.

Case 1: In the third week of February 2019, a sub-adult male tiger TWLS T1-C1, age about 22months was seen in Pilkhan area of sanctuary with an elongated injury on abdominal region causing deep and lacerated wound on the body. The prompt managerial interventions were undertaken for minimizing the disturbance to the animal in trauma and for ensuring the quick rescue operation. The tourism area was closed immediately, camera traps were placed at various locations and about ten monitoring teams were deployed for localizing the animal. Well planned monitoring resulted into quick localization of the injured sub-adult tiger, who used to move along with his male sibling, C2. On 27th February morning, the animal was darted though the moving jeep, as he was quite elusive due to the lantana thickets. After tranquilization, it was observed that the injury was caused due to the tight clutch-wire snare and it had extended to both sides of the body. The metal wire snare was removed from the body and injury was treated. A VHF-GPS Collar (Vetronix) with drop-off facility was fitted around the neck as a part of the long-term project on the tiger dispersal studies in Vidarbha landscape, a joint project by the Maharashtra Forest Department and Wildlife Institute of India.

Case 2: In the second incidence, another sub-adult male tiger (TWLS T1-C3, sibling of TWLS T1-C1) which was fitted with a GPS collar (Vetronix-iridium) on February 25, was found limping due to some injury to his right foreleg. On close observations, a nylon rope snare was noticed which had caused a deep and lacerated wound on the fore leg. The rescue operation was also initiated immediately by identifying the vantage points and deploying teams over machans, as the entire area was full of lantana thickets. New paths were created to traverse the area easily with the darting material. Despite very limited scope for aiming, the animal was tranquilized from the vehicle on 1 June, 2019. In this case, the injury was found extending up to the metacarpal bones.

Both the sub-adult males (C3& C1) were tranquillized using combination of Inj. *Medetomidine* (50 ug/kg) and Inj. *Ketamine* (2 mg/kg) with a Dan-inject syringe projector. After about 15 minutes, animals were approached. Nylon snare from the foreleg and clutch wire snare from abdomen were removed from the body and the wounds were flushed, cleaned and dressed, and the anti-inflammatory drugs and antibiotics were administered intramuscularly. This was followed by injecting reversal

agent Inj. *Atipamazole 25 mg.* All records of vital body indicators were recorded. The Induction and recovery was smooth in both the cases.

In each case, the camera traps were deployed at various places to capture the tiger movements and the healing injuries were continuously monitored. The injuries healed over a period of a month. VHF ground tracking and camera trap images indicted that both the tigers had started hunting normally. Since both the tigers were fitted with GPS based radio collar, their entire movements could be recorded from February 2019 for about the next one year. The sub-adult C3 travelled across the Maharashtra-Telangana borders, travelled through Pandharkawada division, Adilabad division and then returned to settle down in the parts of Tipeshwar wildlife sanctuary. He is now fully-grown adult tiger defending his own territory.

TWLS T1-C1, however has explored the huge landscape. Leaving the Tipeshwar wildlife sanctuary in June 2019 he continuously travelled for about 10 months from Tipeshwar to Pandharkawada division, Adilabad division, Painganga sanctuary, Nanded division, Pusad division, Hingoli division, Washim division, Akola division, Buldana-Dnyanganaga sanctuary, Jalna district and up to Aurangabad district till famous Ajanta hills. In total 13 months since radio-collaring, he travelled for about 3017 Km and walked through 2 states, 10 forest division, 2 regions of Maharashtra, and catchment area of east flowing Godavari and west flowing Tapti river. This entire journey through human-dominated area was however without any conflict -barring one avoidable attack on an intruder; and without many cases of cattle depredation. All the movements of tiger were closely monitored by systematic coordination among satellite data, field formation and the Pench headquarter at Nagpur. The tiger was finally found settled in Dhyanganga sanctuary in Akola district in January 2020. The radio-collar was then remotely removed on 28th March, 2020

Thus, both the snared tigers were successfully rescued to give them a new lease of life, which has further added to nuances in the tiger dispersal pattern in human dominated areas after the satellite telemetry studies.

Case 3: This case is about an adult tigress TWLS T4 who was found with a nylon snare around her neck in September2017.Several attempts were undertaken to capture and to treat the tigress; however, she could not be captured due to her shy and elusive nature, having movement in the night hours, inconsistent territorial nature and her movement outside of the sanctuary for the considerable amount of time. After spending about one year outside the sanctuary, she returned to sanctuary in March 2019. She was found in a weak and emaciated condition with wound around her neck. Attempt was

made to capture the tigress. She was captured and caged too, but could not survive for long. Necropsy examination, revealed presence of maggot wound of size 12-15 cm around the neck. Thousands of maggots destroyed most of the connective tissues, exposed cervical vertebrae's and resulted in hanging of head. The female was unable to hunt or even drink water, which had resulted in the emaciation, dehydration, cachexia, and the death occurred because of cardio-pulmonary arrest.

Conclusion: The treatment of a non-captive tigers under trauma requires a great deal of planning and precise execution. Proper response system and well planned search operations help localizing the animals quickly, which can lead to early capture for the further treatment. A simple activity of removal of snares from the body along with flushing and dressing of wound of the tigers just once not only saved their lives, but also enabled them to lead a normal life and disperse naturally. It also provided us with vital information on their territorial and dispersing behaviour. If capture and treatment of the snared animal is delayed, the injuries can take the life of the animal, as was seen in the case of TWLS4. It is always a good strategy for the managers to undertake frequent anti-snaring drives in such sensitive areas to detect and remove the snares. From all these three case studies, there are many lessons to be learnt for the better management of the tigers in human dominated areas.

References:

1. Bilal Habib, Parag Nigam, Pallavi Ghaskadbi, Mr. Zehidul Hussain, 2020: A Brief Report on Monitoring of Cub C1 from Collaring to Collar Drop off by MFD and WII.
2. Bhorade R S & Rathod, B P. Management Plan of Tipeshwar Wildlife Sanctuary (2015-16 to 2024-25), Government of Maharashtra.
3. https://timesofindia.indiatimes.com/city/nagpur/tipeshwar-tiger-freed-of-snare-released/articleshow/69613281.cms
4. https://www.ndtv.com/india-news/tigers-longest-walk-ever-in-india-search-of-new-territory-2142773
5. https://www.traffic.org/news/asias-tigers-face-devastating-snaring-crisis/
6. Jhala, Y.V., Qureshi, Q. and Nayak, A.K., 2020. Status of tigers, co-predators and prey in India, 2018. (https://ntca.gov.in/assets/uploads/Reports/AITM/Tiger_Status_Report_2018.pdf)

ZBC LP-3

BRITTLE AND FRAGILE LEOPARD SKIN TROPHY RESTORED

Leena Zilpe Haate and B.V.Kharbade
1. Chief Executive Officer, Heritage Conservation Services
2. Ex-Director General, National Research Laboratory for Conservation of Cultural Property
heritageconservationservice@gmail.com

A leopard trophy belonging to 118 Infantry Battalion, Fort Sitabuildi, Nagpur was received for conservation treatment. The trophy was found in a bad state of conservation. After examination, documentation and diagnostic analysis, conservation treatment was planned and accordingly, stepwise treatment that includes cleaning, smoothing and consolidation of skin and then mending of torn and lost parts was carried out. The treated object was then given new canvas lining and the trophy was properly mounted to make it ready for display .

Conservation treatment carried out was as per global standard practices that ensure a long durability and arrest further deterioration if the object is kept under prescribed environmental conditions.

Introduction

During colonial time in India, hunting of wild animals was a popular sport among the rulers. With the establishment of Van ingen and van ingen firm under the patronage of Mysore Maharaja, stuffing and making trophies of hunted animals skin was on the boom. These wild life specimens are now found in various museums, military regiments, government offices and with private owners. Such collections are our national treasure as a resources of knowledge and entertainment and conserving them for future generations is utmost important. Heritage Conservation Services received one leopard skin trophy for conservation from 118 Infantry Battalion, Sitabuildi Fort, Nagpur. It was a challenging task to conserve this specimen as it was in highly deteriorated condition. This paper describes systematic and scientific approach of conserving a leopard skin trophy.

Quarantine

The specimen over the years gets deposited with dust, dirt, pollutants and microbial infestations which may be an allergens for the human beings. Hence, it is necessary to quarantine the specimen before going for its treatment. Leopard trophy was quarantined by keeping with menthol in a sealed tin trunk for 15 days .

Examination and documentation

Leopard trophy measured as length 7feet 3 inches from head to tail, width 4feet 7inches front and behind, width 2 feet 1 inch in the central part. On visual and microscopic examination, prominent hair loss and fall, brittle, torn , folded skin was observed. Cavity of head cranium was filled with mud mixed with jute fibres. Some portions of the skin were missing as well as tail was found broken in to pieces . Hair of the skin lost in patches clearly indicated insect infestation. Trophy was repaired earlier using improper material and technique that caused more harm to the skin.

Treatment

Cleaning

After quarantine, examination, documentation and performing hair fall taste ensuring whether to sustain cleaning, mechanical cleaning was done gently with soft brush. Crazy dust mingled with hairs was carefully removed using comb and pointed brush. For removing dirt bonded with skin and hair roots, cotton poultice wet in a mixture of ethyl alcohol and water was applied and allowed it to remain on the surface for 20-30 minutes. This process was repeatedly done till cleaning was satisfactory. Greasy stains were removed by rubbing wet poultice in mineral spirit. Mud mixed with jute filled in head cavity was removed carefully and then the cavity was cleaned thoroughly.

Softening and consolidation

Skin was allowed to dry completely after cleaning, then inside skin surface rubbed hard eraser to make open skin pores allowing to absorb softening solution. British Leather dressing solution containing anhydrous lanolin as a main ingredient was applied with brush 1-2 coat and then allowed to penetrate inside the skin. One more coat leather dressing solution was applied again after a week.

Mending and mounting

The missing parts were mended by cobbler stitches using old tanned goat leather purchased from the local market. Holes and tears were mended by pasting goat skin using compatible neutral rubber adhesive. Head cavity was filled with a mixture of paraffin and bees wax. Lastly, to make ready the trophy for mounting, it was given canvas lining stitched on cloth broad border.

Conclusions

Menthol used as fumigant has no harmful effect on skin, whereas, commonly used fumigant thymol, PDB (paradichlorobenzene) are reported for causing damage to skin (1, 2). British leather formulation is a tasted solution being used all over the world treating brittle skin and its application in this case gave very satisfactory results in achieving a

good flexibility to brittle skin. The remarkable difference in before and after treatment, figure 1 to 5, indicates itself that a highly deteriorated leopard skin trophy is rejuvenated to new life for another century if it is preserved properly in the prescribed environmental condition.

Acknowledgements

The author would like to thank the authority of 118 Infantry Battalion, SItabuildi Fort, Nagpur for providing us opportunity to restore their leopard skin trophy. I also express my sincere gratitude to Dr B. V.Kharbade, Ex –Director General, NRLC, Lucknow for his ready help and advice during the treatment. Help in treatment of trophy of A. Moses and Aaradhana Shinde is highly acknowledged .

References

1. Plenderleith H. J. , The Conservation of Antiquities and Works of Art , Treatment , repair and restoration , Oxord University Press , London , 1956.

2. Aisling Macken and Magaret J. Smith , Solvent vapour use – the unintended consequences in textile conservation , Studies in Conservation , 64(6) , 2019 352-362.

ZBC LP-4

IS GURNEY'S PITTA ON THE BRINK OF EXTINCTION?

Nay Myo Shwe[1,2], Niti Sukumal[1], Mark Grindley[2], Tommaso Savini[1]
1. Conservation Ecology Program, King Mongkut's University of Technology Thonburi, Bangkok, Thailand
2. Fauna & Flora International, Myanmar Program
naymyo.shwe@fauna-flora.org

Over the past half century global biodiversity have been declining with this trend mostly accentuated in tropical regions among which Southeast Asia showed the highest probability of vertebrate extinctions Taninthayi, in the most southern part of Myanmar, is home to one of the few remaining large patch of forest in Mainland Southeast Asia. The aim of this work to define the overall extension of the remaining suitable habitat in the Taninthayi for the Gurney's Pitta. We focus in all mainland forested areas in south Taninthayi mainly in Lenya, Nga Woun and Parchan Reserved Forest from 7°N to12°N latitude which represent the north and south limit of the species based on historical and recent observations. We collected the coordinate of all detections reported in Eames et al (2005) and Donalds et al (2014), for a total of 147 detections ranging between 2003 and 2012. We re-visited those 147 location from January to October 2016 to first confirm the availability of suitable habitat. In less than two decades the suitable habitat for the endemic lowland Gurney's pitta has declined from 3395 km^2 to only 656 km^2 (81%) in what was once considered the species stronghold, the south Tanintharyi.

Keywords deforestation, Lenya national Park, *Hydrornis gurneyi*, south Taninthayi, strongholds

ZBC LP-5

A REVIEW OF *Hipposideros lankadiva* KELAART, 1850 (*Chiroptera: Hipposideridae)* WITH A DESCRIPTION OF A NEW SUBSPECIES FROM MYANMAR

PAUL BATES[1], OHNMAR TUN[2], **MOE MOE AUNG[3]**, AUNG LU[2], M. ROI LUM[2] AND MIE MIE SEIN[4]

1 Harrison Institute, Bowerwood House, St Botolph's Road, Sevenoaks, Kent, TN13 3AQ, UK
2 Department of Zoology, Myitkyina University, Myitkyina, MYANMAR
3 Department of Zoology, University of Yangon, MYANMAR
4 Department of Zoology, University of Mandalay, MYANMAR
moeaung189@googlemail.com

Although systematic research of bats in Myanmar has been conducted since 1863, limited study was conducted in Kachin State. Therefore sequence of surveys was conducted and a colony of *Hipposideros lankadiva* was discovered in Kachin State, upper Myanmar in 2011. The large size of the specimens when compared to those from peninsular India led to a review of the taxonomy of the species and the description of a new subspecies from Myanmar, with material from north-east India referred to this new taxon. The distribution of the species from throughout its range is summarized and mapped. Based on the material from Myanmar, new information is provided on the acoustic characters and the bacular morphology. Short notes are provided on its ecology in Myanmar and north-east India.

ZBC LP-6

ANIMAL WELFARE ANDETHICAL CONCERNS INWILDLIFE VETERINARY PRACTICE IN INDIA

A. Sha Arun
Director – Research & Veterinary Operations Wildlife SOS
arun4webseminar@gmail.com

The subject of wild animal welfare and ethics in both captive and free ranging wildlife care is poorly understood and hardly in practice. The upkeep of an animal both physically and behaviourally healthy is a paramount important in wildlife veterinary practice too. In this article, "Animal welfare and ethics in wildlife veterinary practice" I would like to discuss about various disciplines and wildlife husbandry practices involved in wildlife veterinary practice. The primary objectives, including examples and interactive discussions with the intention of reinforcing our awareness, understanding and approach regarding the subject.

With eighteen plus years of experience in rescuing and rehabilitating wild animals which include Sloth bears (*Melursus ursinus*), Leopards (*Panthera pardus*), Indian Elephant (*Elephas maximus indicus*), Snakes of different species (suborder: Serpentes) and Striped hyenas (*Hyaena hyaena*), it would be humbling to discuss the subject of animal welfare & ethics with respect to our wild friends that are perhaps equally deserving if not more than their domestic counterparts in leading a life with dignity, at least in their later years.

THE EMERGENCE OF ANIMAL WELFARE AND ETHICS:

Ethics stem from the moral dimensions that back our everyday decisions. There is consistent evidence of 'respect' towards animals in the Indian sub-continent that can be found in the ancient scriptures. Reference to Kamadhenu, the miraculous 'all giving' cow in Hindu mythology and the many animals each attributed as the official mascot of different gods namely the spectacled cobra (*Naja naja*) associated with Lord Shiva, Peacock (*Pavo cristatus*) associated with Lord Subramanya, Garuda the Kite (*Haliastur indus*) associated with Lord Vishnu or even the much hated rodent species like the mice (*Mus booduga*) associated with Lord Ganesh all point towards our reverence towards fellow species and an apparent attempt to co-exist. Modern philosophers and thinkers from the west have debated elaborately on the necessity for being ethical towards animals and thereafter about the degree to which ethics is applicable to animals. While some have discounted the very idea of showing moral consideration to these sentient beings, others have had a more consequentialist or obligatory approach in this regard. Modern ethical theories namely Contractarian theory, Utilitarian theory, the theory of animal rights,

relational views and respect for nature each reflect on the three-perspective mentioned earlier.

The science of animal welfare concerns how sentient animals experience their life in terms of their physical functioning, mental state / feelings, and natural behaviours. A change in one of these aspects could very much result in the welfare of the animal being compromised. Application of the modern ethical theories to areas concerning animal welfare will yield a holistic view and help set the tone to the line of action. Breeding dogs / captive wild animals with heritable defects, farming animals for meat, controlling infectious diseases in animals (zoonotic or otherwise) and use of animals in research are some areas to be covered taking into consideration the socio-economic angle. A discussion on standard veterinary practices in the above-mentioned areas of concern shall help in arriving at a common consensus within the veterinary community to better the animals' welfare.

ETHICAL CONCERNS:

A chapter dedicated to animal welfare and ethics in wild animals will help refine our perspective in understanding the subject considering the rarity of these species where requirements are far more stringent and laws far less lenient, taking into consideration the five freedoms of animal welfare. Legal concerns, Ethical animal exhibits, enclosure designing, hygiene- sanitation, quarantine, disease control, biosecurity, Enrichment of wild animals in captivity to simulate situations in the wild, animal welfare audit for wild animals in captivity, sampling, data collection, research, and publication would be making some interesting examples. Similarly, in free ranging wildlife, the conservation areas of conflict mitigation measures, rescues, reuniting the orphaned wildlife with mother, rehabilitation, veterinary care, disease prevention, necropsy procedures, various aspects of documentation and dissemination of knowledge would certainly have a strong hold of ethical practice. In general, the challenges in various aspects of following animal welfare and ethical practices and possible solutions are discussed in detail during the presentation.

ACKNOWLEDGMENTS:

I am thankful to Ms Geeta Seshamani and Mr. Kartick Satyanarayan, Co-Founders, Wildlife SOS, for providing me the opportunity to serve and learn from wildlife veterinarians and biologists. I extend my thanks to Central Zoo Authority, State Forest Departments, and Zoos of India. I also thank the staff at Wildlife SOS, MLRC, Agra and Bannerghatta Bear Rescue Centre, for their valuable field assistance and co operations. Special thanks to Mr Shreyas Sudhindra, Ms Prajakta Rao, Dr Adhithyan and Dr Pushkar for helping me to prepare the presentation.

ZBC LP-7

PROBLEMS OF "TOO FEW" AND "TOO MANY"- CONSERVATION CHALLENGES OF ELEPHANTS IN MYANMAR

Dr. Khyne U Mar
BVS, M Sc (Wild Animal Health), M Phil., PhD, FRVCS IndependentConsultant
IUCN/Asian Elephant Specialist Group European Association of Zoo and Aquarian

The Asian elephant (*Elephas maximus*) is globally endangered and listed in CITES Appendix I The surviving populations of Asian elephants are estimated to be between 30,000–50,000, according to the World Wildlife Fund for Nature (WWF). These elephants are restricted to just 15% of their original range in fragmented and isolated populations within south and south-east Asia.

Myanmar manages the largest captive elephant population in Asia and globally, primarily because elephants were the backbone of Myanmar's forest industry for many years. Myanmar has a total of ≈ 6000 elephants in captivity; half is owned by the state-run Myanmar Timber Enterprise (MTE) and half is privately owned according to Myanmar Government data. Many of these private-owned elephants have been rented to MTE to work as logging elephants. About 2000 Asian elephants are thought to survive in the wild in Myanmar, decreased from 10,000 individuals in 1940s, ≈6000 in 1960-1970, 4639 in 1991 and ≈2000 in 2018 according to the government and other conservation specialist estimates.

Myanmar has fewer elephants in the wild, compared to the neighboring countries.

Habitat loss together with physical disturbances such as development projects and road expansions that block the continuity of the elephant movement are regarded as the major causes of declining numbers of wild elephants of Myanmar. Fragmentation of elephant populations is a major driver of decline. Illegal killing of elephants for trade in body parts, such as elephant skin, teeth, bones, genitalia, and trunks is an additional threat to Myanmar's wild elephant populations. There are worrying indications that the illegal live-captures of wild elephants has emerged in Myanmar during the past couple of years based on the reports of confiscation of partially sedated elephants found unattended on heavy goods vehicles (HGV) near checkpoints or discovered on highways by traffic officers. Although China took the monumental step of banning elephant ivory trade in 2017, a black market that prizes elephant products is fueled by a burgeoning demand by wealthy Chinese who view jewelry made of elephant skin and ivory as a token of good luck and/or herbal medicine.

Myanmar has too many elephants in captivity, compared to its neighbors.

In April2014, the Myanmar Government imposed a ban on exporting raw teak and timber allowing only the export of high-end finished timber products. This ban reduced timber extraction by 50% and MTE stopped leasing privately-owned elephants for logging. The majority of these private- owned elephants are redundant and the owners are now facing the financial burden of keeping them in captivity. In order to meet these burdens, it is expected that these elephants will now be used in the tourist industry, as in Thailand.

My presentation will cover the conservation needs of Myanmar elephants, which will include the followings:

1. Habitat needs to be properly protected for both wild and captive elephants
2. Effective control of illegal killing, captures, and trade in elephants and their parts, especiallyivoryandskin,primarilythroughlawenforcementandthepropermonitoring and management of that law enforcement
3. Management of human-elephant conflict to mitigate the threat to wild elephants and their habitats
4. Creation of a self-sustaining well-managed captive elephant population, as a source for the long-term conservation of wild elephants and as a resource for revenue-generating elephant-friendly internationally accepted tourism using captive elephants
5. Capacity building of professional mahouts and elephant veterinarians

Abstracts

ZBC-01

WEIGHT AND BODY MEASURMENTS OF HAND REARED FOUR HORNED ANTILOPE FAWN

Bawaskar S.S., A. B. Motghare, M.S. Bawaskar and R.S. Khobragade
Maharajbag Zoo, College of Agriculture, Nagpur
abhijeet.motghare@rediffmail.com

The experiment involved two (1:1) hand reared Four Horned Antilope aged about 15 days at Maharaj bag Zoo, College of Agriculture, Nagpur. Observations were made on body weight and body measurements. The fawns were weighed and measurements made at about one month interval for three months. Male was somewhat heavier than female. At the age of three months males weighed about 5.87 kg and female weighed about 5.42 kg. Body measurements i.e. body length, shoulder height, head length, head width, mandible length, ear length, and chest circumference (cm) average were 35.00, 34.33, 16.00, 26.33, 7.33, 9.67 and 4.33 respectively for male. 31.33, 36.33, 15.00, 26.33, 9.33, 9.33 and 39.33 respectively for female animal.

ZBC-02

TIGER (*Panthera tigris*) IN NON-PROTECTED AREAS- THE CASE STUDY OF THE KATLABODI TIGRESS OF KALMESHWAR-KONDHALI BLOCK, NAGPUR, MAHARASHTRA

Kundan Hate[1]and Dhanusha Kawalkar[2]
[1]Member – State Wildlife Advisory board , Maharashtra State,
[2]Senior Research Biologist, Division of Conservation Ecology, Sálim Ali Centre for Ornithology and Natural History (SACON), Anaikatty P.O., Coimbatore, Tamilnadu, India – 641108
kundanhate@gmail.com

Every protected area (PA) has a carrying capacity which it can support. However, the spill-over tiger population of every protected area needs a place to settle and survive. A non-protected area (Non-PA), therefore, not only plays a critical role in providing refuge to the species but also supports their long-term survival. One such, let alone non-protected area is the Kalmeshwar-Kondhali block, is playing an essential role by serving as a breeding ground. This extended critical habitat for tigers is necessary for the specie's future and serves as a vital link between various habitat patches. Nine years ago, deep in the 35ft dry well, on 7th February 2011 near Katlabodi village, Kondhali Forest Range, a tigress, was rescued. Safely rescued, she was brought to Nagpur for treatment. However, because of falling in the dry well, she had a few injuries and delivered a still litter. Subsequent to her treatment, Kalmeshwar range was chosen as a potential habitat

comprising of a prey base for her release. The tigress was successfully released post-recovery on 14th February 2011. As, the tigress was rescued from the Katlabodi village gave her the identity of Katlabodi tigress. Following to her release, the forest department began monitoring using camera traps and continuous efforts were done for habitat restoration and improvisation. The Katlabodi tigress (T1) delivered her first litter in the 2013. The first litter survived and are assumed to be dispersed to nearby area protected or non-protected areas. However, due to lack of systematic monitoring in the KKB, the dispersal route and exact location of the cubs couldn't be estimated. Further, in 2015, the second litter was observed at the Kalmeshwar range with Katlabodi tigress and were named Shivani (T3), Nawab (T4), and Bhavani (T5). These tigers were usually sighted in both the Kondhali range established their territories. A few years ago, T4's presence was documented using camera traps in the Pohra-Malkhed region of Amravati district. Presently, the tigers, T3, and T5 continue to live in the Kondhali range. Soon after the four litter (3 cubs), the Katlabodi tigress was captured on the camera traps with another litter (third) in 2016 and recently (2019-2020) was recorded with her fourth litter (3 cubs). Kalmeshwar – Kondhali Block is a perfect example and a model of how can such small block of approximately 160 sq.km can hold a healthy tiger population. As number of tigers increase in the protected areas the spillover population comes out in the search of new territories. Further, to ensure and safeguard the survival of the umbrella species like tiger survival research and conservation is recommended in the non-protected areas. Also, it is important to understand that the preserving these extended critical habitats is the only way out for protecting the last surviving populations of the big cats.

ZBC-03

MANAGEMENT OF THEILARIOSIS IN A FRIESWAL CATTLE FARM AFTER THE LANDSLIDE IN KERALA

Seena, T.X, Archana,S.N, Amitha Thomas, Justin Davis and Metilda Joseph
Cattle breeding farm ,Thumburmuzhy ,KVASU Kerala
drseenatx@gmail.com

The Cattle Breeding Farm, Thumburmuzhy (CBFT) is an educational institution under Kerala Veterinary & Animal Sciences, University with the objective of teaching, research and extension, rearing more than 200 Frieswal Cattle. The farm located in an ecologically fragile, hot humid region of Pariyaram forest range of Thrissur District in Kerala. It shares one Kilometer rear border with Sambar Deer dwelling forest region of Kumblanmudy hills, separated by strong Galvanized iron fencing to avoid the intrusion of wild animals. In the year 2018, the farm faced a natural calamity in the form of great

landslide during the south- west monsoon of Kerala and the fencing was broken. The yearly screening of animals revealed zero prevalence of haemoprotozoal diseases in the farm when compared to its high incidence in two neighbouring Panchayats. But the screening of animals after the landslide revealed that 32.86 % of stray and 28.57% of animals positive for theilerial organisms. The affected animals showed symptoms like anaemia, and downer syndrome during early postpartum period. Also the tick population increased tremendously. On investigation, it was found that the encroachment of Sambar deer carrying tick vectors of Theilerial organisms was the causative agent. To control this, immediate actions were taken to prevent the encroachment of wild animals, treated the grazing area with parasiticide (gluteraldehyde), burned the plants and shrubs at the buffer zone of forest boundary. All the stray and positive animals for theileria were treated with the Buparvaquone along with supportive medicines. The result of blood smear examination after two weeks revealed the absence of organisms. It is concluded that the incidence of haemoprotozoal disease from the wild ruminants can be expected after landslide in a heat stress area and here we could efficiently control the disease without affecting the production status of CBFT.

ZBC-04

EMERGENCE OF ZOONOSES DUE TO HUMAN INTERVENTION AMONG THE WILDLIFE: A CASE STUDY OF KYASANUR FOREST DISEASE OUTBREAKS IN KERALA

Gayathri S. Lal[1*] and Muhammed Asif M.[2]
[1*] PhD Scholar, LPM Section, ICAR-NDRI, Karnal, Haryana-132001
[2]MVSc Scholar, College of Veterinary and Animal Sciences, Mannuthy
Kerala Veterinary and Animal Sciences University, Pookode, Wayanad, Kerala-673576
gayathrisherlylal@gmail.com

Kyasanur Forest Disease (KFD)/monkey disease/monkey fever is a re-emerging zoonotic viral haemorrhagic fever caused by virus of genus *flavivirus* and family Flaviviridae, spread by ticks of genera *Haemaphysalis* -reservoirs as well as vectors of virus, to humans. It was first discovered in 1957 from Kyasanur forest area, Shimoga district of Karnataka. A total of 20 cases were reported during 2019 and 41 cases during 2020 (up to 30 April 2020) among the tribal communities of Sulthan Bathery and Mananthavadi areas of Wayanad district, Kerala. Previously during 2013, the first case in Wayanad district was reported, followed by 184 cases in 2015 (9 death), 9 cases in 2016, 2 suspected cases in 2017. The epidemic period usually begins in October or November and peaks from January to April, then declines by May and June. The number of cases

reported among the tribes is increasing every year and there is a gradual expansion of the disease affected area. Vaccination protocols (2 dose followed by booster dose at 6-9months - annual dosage) for the age group of 7-65years is widely recommended for tribes of vulnerable areas. Prevention and control with the aid of one health is the only solution to address the issue.

ZBC-05

TRADITIONAL MEDICINES FROM WILD ANIMAL RESOURCE *VIS-À-VIS* ITS CONSERVATION STATUS

Sharma, G.
Department of LPM, College of Veterinary Science & Animal Husbandry,
Navsari Agricultural University, Navsari 396450 Gujarat, India
gautami.sarma@gmail.com

Wildlife has been integrated into human society from time immemorial through medicinal, cultural, religious contributions. Wild animals constitute an essential element in traditional medicine, a component of "zootherapy". Although traditional medicine is practiced in many parts of the world, mostly remains supernatural. But such practices can be a threat to the conservation of wild population. Many species like tiger, rhino, elephant, bear etc. have declined in population due to their illegal poaching and international trade in black markets. These innocent creatures are killed and smuggled as whole animals or their parts like skin, bones, horn, ivory, flesh, scales, oil, bile or other internal organs. They are known to be used against diverse ailments including cardiovascular disorder, tuberculosis, syphilis, cancer and many other conditions. Wild animals are also used due to its aphrodisiac properties especially tiger genitalia, cobra blood, turtle eggs etc. Traditionally animals have been an important part of pharmacopeia, even mentioned in historical books like Ayurveda and CharakaSamhita. So far little research has been done to prove the claimed efficacy, though it is valued as raw material in preparation of modern medicines. Now WHO (World health organization) is also planning to include traditional medicine in its medical compendium for proper integration with modern medicine. In remote areas there is limited availability of institutionally trained medical practitioners whereas the traditional healers become easily accessible. Therefore, suitable alternatives like herbal substitute for animal-based medicine need to be found out to protect these threatened wildlife species.

ZBC-06

MONITORING THE DISPERSAL OF TIGER (*Panthera tigris*) FROM KALMESHWAR-KONDHALI BLOCK, NAGPUR TO POHRA-MALKHED FOREST RANGE, AMRAVATI

Kundan Hate[1] and Dhanusha Kawalkar[2]
[1]Corresponding author- [1]Member – State Wildlife Advisory board , Maharashtra State,
[2]Senior Research Biologist, Division of Conservation Ecology, Sálim Ali Centre for Ornithology and Natural History (SACON), Anaikatty P.O., Coimbatore, Tamilnadu, India – 641108
kundanhate@gmail.com

Post release monitoring of wildlife is an essential part of effective wildlife conservation. Monitoring through various ways such as tagging, radio-collaring, micro-chipping, scat analysis, camera trapping and other, allows us understand how well the animal has adapted to its new environment/habitat. The Katlabodi tigress was successfully rescued and released in the Kalmeshwar forest range of the Nagpur district in the year 2011. Subsequent to her release, camera trapping method and indirect sign surveys was used to monitor the tiger population in the Kalmeshwar - Kondhali Block. As, tigers are identifiable on the basis of their stripes (natural marks), we used capture-mark-recapture method to recognize them. One of her litters (n=4) of 2015 comprised of three cubs which were identified using their unique strip pattern (2F, 1M). Using the same protocol, the male of the same litter (T4, also called as Nawab) was identified to be dispersed from the Kondhali forest range to the Pohra-Malkhed range. The tiger T4 was also observed in the Kondhali forest range. T4 approximately covered around 200kms during this dispersal. Based on this finding we conclude that the Kalmeshwar forest range is a breeding habitat and Kondhali forest range is an extended critical tiger habitat for the Katlabodi tigress and her cubs. Understanding this we recommend the use of camera trapping method for monitoring visually differentiable species. Further, tracking of the adults born in non-protected areas (such as Kalmeswar-Kondhali Block) will help us understand species behavior and their habitat requirements. Moreover, the information can be used for prioritizing critical tiger habitats outside protected areas.

ZBC-07

INVESTIGATION ON THE POTENTIAL OF *IN VITRO* GAS PRODUCTION TECHNIQUE FOR ASSESSING THE NUTRITIVE VALUE OF FEEDS CONSUMED BY ELEPHANTS

Nandana Chandrasekhar[1], K. S. Ajith[1], K. Ally[1], A. Deepa[1], T. S. Rajeev[2]
[1]Dept. of Animal Nutrition, College of Veterinary and Animal Sciences, Mannuthy, Thrissur, Kerala, India[2]Dept. of Veterinary & AH Extension, College of Veterinary and Animal Sciences, Mannuthy, Thrissur, Kerala, India
nandanachandrasekhar@gmail.com

The intricacies in the digestion and metabolism of nutrients are less understood and it is very difficult to assess the nutritive value of feed offered to elephants in wild as well as in captivity. Elephant being a hind gut fermenter, a novel technique was adopted to investigating the potentiality of using *In vitro* gas production technique (IVGPT) to study the digestibility of organic matter and metabolizable energy content in the feed fed to elephants under captivity using elephant dung as inoculum. IVGPT was carried out as per standard method suggested by Menke *et al*., 1979. The gas production of samples was recorded after 24, 48 and 72 hours of fermentation. *In vitro* organic matter digestibility and metabolizable energy obtained was higher for concentrates and lower for roughages. *In vitro* organic matter digestibility and metabolizable energy respectively of grass, palm leaves, straw, jack leaves, plantain stem, maize and ragi were 25.74, 28.60, 14.72, 27.95, 30.54, 67.87 and 55.37 per cent respectively, and 3.75, 4.15, 2.08, 4.06, 4.52, 10.26 and 8.35 MJ/kg DM respectively. Further studies are necessary to evaluate the efficiency of utilizing elephant dung as source of inoculum to predict nutritive value of feeds fed to elephants.

ZBC-08

PARASITES IN WILD LIFE AND FREE-LIVING OF JAMMU REGION

Sanku Borkataki, R.Katoch and Ankur Sharma
Division of Veterinary Parasitology, FVSc & AH,R.S.Pura ,SKUAST-Jammu,181102.
borkataki_sanku@rediffmail.com

A Rat snake- (*Ptyas korros*), one small Indian mongoose- (*Herpestes auropunctatus*) and five domestic rat (*Rattus rattus*) caught lying dead nearby the ground of Faculty of Veterinary sciences &Animal Husbandry, R.S.Pura. Rat snake most frequently found in agricultural land and strongly associated with rice field. Domestic rat widely found in urban areas, villages, agricultural fields and forest edges. They cause a great deal of economic damage by destroying food stores and are important reservoir of many rodent borne diseases. The small Indian mongoose is a small animal with short leg found in Northern India from Kashmir to Bengal, Orissa, Assam up to Burma. They are

fall under the order Carnivora and family *Herpestidae.* They mostly feed on insect, crabs, fishes, frogs, earthworm, lizard, rodent, spider, scorpions, snake and even fruits also. Beneficial effect of mongoose is that they can control snake in agricultural area. They also act as vector and reservoir of rabies and leptospirosis. All the dead animals were collected in different times and post mortem were performed immediately after collection. The parasites were collected from different organ from different animals and then fixed and processed and permanent mounts were prepared for morphmetric identification. Description of the parasite identified based on the morphology revealed- *Xenopharynx sp*.- a trematode found from the gall bladder and *Kallicephalus* sp.-a nematode found from the small intestine as well as an *Acanthocephala* sp. - form the mucosa of small intestine of Rat snake. Cyst found in the liver of rodent was identified as *Cysticercus fasciolaris and* a trematode identified as *Hymenolepis diminuta* from small intestine and *Syphacia sp.* from colon. The treamtode *Artyfechinostomum sufrartyfex* was identified from the small intestine of Indian Mongoose is important from public health point and put on record of it occurrence in wild host like Mongoose.

ZBC-09

CREATING DATABASE FOR ANIMALS USING CLOUD ONLINE FOR CARE OF WILD ANIMALS

Shourya Gupta[1] and Devender Kumar[2]
1. Vellore Institute of Technology, Chennai, India
2. Evaluation and Monitoring Officer, Central Zoo Authority,New Delhi
shourya.gupta2019@vitstudent.ac.in

In recent days, wild animals in distress, rescued due to man-animal conflict or suffering in the times of calamity are fond not to be rehabilitated and to be housed in life time care facilities has been increasing. There is a rapid decline in endangered wildlife around the world. Our proposed system tackles the problem by developing a website using cloud database, it gets the details of animal species in every state & housed in ex situ facility in India, including count of animals in each facility, which can be flashed on the website and other animal life time care facility if they need. Also, the wild animals that are in distress, including injured, orphaned, abandoned, or those who have come across natural disasters like flood, cyclone, earthquake etc. can be given to those animal facilities that can take care of it. Adoption of such animals by nature/animal lovers, and contribution of money for them can be provided to the organizations who are working for the welfare of the animals in the field. An online portal will ensure safety, and transparency in the system, making it more efficient. Also, it is much required in today's world as populations of endangered wildlife is shrinking day by day.

ZBC-10

BEHAVIORAL STUDY OF ROYAL BENGAL TIGER AFTER APPLYING COGNITIVE ENRICHMENT

Suvarna Kawale, Bawaskar,S. S. and Motghare, A. B.
Maharajbag Zoo, College of Agriculture, Nagpur
survarna.kawale86@gmail.com

To engage the wild animals in captivity "Enrichment activities" are very effective tool. Present study is based on the cognitive enrichment of female Royal Bengal Tiger of Maharajbag Zoo. Captive environment are generally deficient of challenges which provides them optimum psychological, physical stimuli and exercise. Enrichment program is designed considering above factors under continuous monitoring and observation. Without enrichment most of the day time she spent in Roaming around in the enclosure then takes some rest under shade and again same routine she followed.

Cognitive enrichment is anything new or challenging that will make the animal think, be challenged, or become curious. The natural objects such as gunny sack, dried leaves and coir rope are used for the cognitive enrichment of Royal Bengal Tiger. Gunny sack filled with the dried leaves was hanged on the bamboo tree with the help of coir rope which was swinging after getting jerk. When tigress came near the hanged sack it tried to identify the present material by smelling it, taken a look of enclosure for presence of any other things, came back to bag and started pulling it but failed; after 10-15 minutes again tried to pull and succeeded then picked up the bag and ran towards the water pool and played with it.

When she observed new object in her enclosure its facial and body expressions changed. Her tongue was out and tail was moving in upside direction. It is observed that tigress loved playing with new item which she discovered in enclosure. Tigress engaged with the gunny sack throughout the day. This cognitive enrichment got success in engaging the Tigress and helped to improve its mental and physical health.

ZBC-11

FEEDING ENRICHMENT OF SLOTH BEAR (*Melursus ursinus*) AT MAHARAJBAG ZOO

Suvarna Kawale, Bawaskar, S. S. and Motghare, A. B.
Maharajbag Zoo, College of Agriculture, Nagpur
survarna.kawale86@gmail.com

Free roaming wild animals spend their most of the time in searching and processing of food, finding mates, defending territories, building nests, protecting herds,

avoiding predators etc. However, in captivity they have lots of free time because all the things are readily available for them. To engage them in captivity "Enrichment activities" are very effective tool. First step for enrichment of captive animal is selection of the natural behavior to be encouraged. During this study animal selected for enrichment activity is Sloth bear, after researching the literatures and observations of sloth bear findings are Sloth Bears are dreadful wild animal, excellent climber, swimmer and digger.

Enrichment schedule is followed for applying enrichment activity on the animal. Enrichment program is designed so as to provide the optimum psychological and physical stimuli and exercise to sloth bear which is generally deficient in captive environment. Feeding enrichment is the type of enrichment selected to study the Natural behavior like digging and climbing. To encourage its natural digging behavior whole watermelon, carrots, sweet lime buried deep in the soil at various places in the enclosure and closed the holes. Exiting wooden logs till its highest peak was smeared with the honey to encourage its climbing behavior.

Generally sloth bear gets its feed in the feeder which gets finished quickly within 10-15 minutes. When applied enrichment activity it was observed that - (1) it spent 12-15 minutes in licking the smeared logs. (2) Climbed at the highest peak over the logs to get the honey. All around it takes near about 20 minutes for honey licking only. (3) It roams around in the enclosure and sniff for the fruits smell and once it got the smell it started digging and get its food. During this activity it spent a day in search of food.

The enrichment program includes continuous observation and monitoring of the sloth bears behavior. On the basis of observations it is concluded that feeding enrichment activity with smearing honey and hiding fruits is succeeded as sloth bear were found engaged throughout the day in search of food, its natural behavior is very well encouraged. This will help to improve its physical as well as mental health by avoiding boredom and stereotypic behavior.

ZBC-12

TEMPORAL OVERLAP IN CARNIVORE COMMUNITY OF KANHA TIGER RESERVE

Anup Pradhan, Ujjwal Kumar, Jayant Bora, Neha Awasthi, Shravana Goswami, Qamar Qureshi and Yadvendradev V Jhala.
shuvapradhan@gmail.com

Ecology of tiger and leopard are well studied in Kanha (Schaller 1969, Pawar 1972 and ongoing study by Jhala *et.al*. 2005-2013), however very little information are available on other two large carnivore i.e., Sloth Bear and Wild Dog and meso carnivores like Jackal and Jungle Cat. These Non-pantherine carnivores (NPC) are important and constitute a viable carnivore community along with pantherine carnivores in Kanha Tiger reserve. We studied temporal interaction of carnivore community in Kanha Tiger Reserve. We deployed 1022 camera traps in Kanha tiger reserve during 2014. Camera traps were placed in 1 km^2 grid at the best possible locations such as animal trails, forest road and nallah where the chances of getting carnivore photo-capture were maximum. Each photograph was stamped with the date and time of photo-capture along with the location id and extracted for understanding temporal activity pattern. To ascertain independence in the activity data, we used 15 min interval between the previous photographs at the same location. We used overlap package in R programming environment to analyse the temporal activity pattern of overlap between the animals. We found that tiger, leopard, sloth bear and jungle cat were nocturnal while wild dog was diurnal in nature. We found that tiger and leopard had high overlap ($\hat{d}_4 = 0.86$) in their time of activity, however tigers were highly active during night time while leopard activity was high during evening hours. The activity overlap between wild dog and tiger was minimal ($\hat{d}_4 = 0.24$). This reflects the niche separation between tiger and wild dog. Activity overlap between jackal and tiger was moderate ($\hat{d}_4 = 0.55$). Jackal are known to scavenge on the tiger kill and predate on chital fawn hence they were more active during morning. This study is important in relevance to conservation and management of Non Pantherine Carnivores as they hold trophic positions below tiger and leopard influences the community structure and resource sharing between species in Kanha.

ZBC-13

CAPTIVE RED JUNGLE FOWL (*Gallus gallus*) PREFERRED WILD HABITAT IN CAPTIVITY

Sanjit Kumar Saha
Office of the DFO, Cooch behar Division, East Kameswari Road, P.O. & Dist. Coochbehar-736101, Directorate of Forests, Government of West Bengal,
sanjitwbfs@gmail.com

Rasikbeel Mini Zoo, Cooch behar, West Bengal received 4 Red Jungle Fowls (2 adult Male and 2 adult female birds) from Padmaja Naidu Himalayan Zoological Park

(PNHZP), Darjeeling as on 13th July, 2020. As on 08th December adult female (Hen) of Red Jungle Fowl gave birth of 3 Chicks in captivity of Rasikbeel Mini Zoo, Cooch behar Division, West Bengal. It is the 1st incidence of hatching of female Red Jungle Fowl in Rasikbeel Mini Zoo, Cooch behar. Animal attendants are new to this experience. At first we separated the mother and chicks from the other male and female birds with the partition of Agro net shed with the objective to protect the chicks from the other male bird. We have observed mother hen in captivity is taking care of the offspring like wild. We have facilitated artificial brooding house like poultry birds with artificial lights (electric bulbs) and basket to provide warm atmosphere. Side by side we have facilitated thick ground cover with dry leaves in the natural enrichment of bamboo clusters. Mother hen chose the portion of natural enrichment of dry leaves in the enclosure for giving warmth to her chicks. As per our observation whole day the mother hen is roaming and foraging with the association of chicks. After the sunset at around 05:30 pm mother hen giving natural brooding (warmth) taking underneath the chicks centering in dry leaves bed in the bamboo cluster up to the sunrise of next day. Phenotypic expression is the result of interaction of genotype and environment and here phenotypic preferences of near natural brooding habitat still maintain wild nature of the species in captivity.

ZBC-14

FEEDING ENRICHMENT IN SLOTH BEARS EXPERIMENTS AND INTERVENTIONS

Kolangath S.M., Pawshe M.D.,Shalini A.S., Upadhye S.V., and Dhoot V.M.
Wildlife Research & Training Centre, Gorewada, MAFSU, Nagpur
brosujit@gmail.com

Feeding enrichments is a routine practice in captive wild animal management. Sloth bears (*Melursus urisinus*) are extremely active and voraciously enjoy enrichment in their enclosures. Experiments with Roasted Grams and Green Coconuts was undertaken to study the utility and participation of sloth bears. Roasted grams were included in the food items and provided with the regular food items. Gradually the gram was spread in the entire night shelter encouraging the bears to explore. Gradually the gram was spread in the enclosures and bears were monitored for feeding through CCTV. Green coconuts were initially provided by slicing them into two parts, after a week whole green coconut were provided to bears either in night shelters or in enclosures. The bears could feed on whole green coconuts without any difficulty. The average time adult bears consumed to explore roasted gram from a 100 Sq. ft. area was 45 minutes, while a green coconut kept an adult bear engaged for 30 minutes. Some adults were found to continuously engage

with the remnant for over 1 hour. A few others buried the remnant of the green coconut. The observation is encouraging as these feeding enrichments are easily available and can be utilized to engage sloth bears in captivity.

ZBC-15

BAMBOO PLANTATION AS A NATURAL ENRICHMENT IN LEOPARD *(Panthera pardus)* ENCLOSURE

Kolangath S.M., Pawshe M.D.,Shalini A.S., Upadhye S.V., and Dhoot V.M.
Wildlife Research & Training Centre, Gorewada, MAFSU, Nagpur
brosujit@gmail.com

Wild captured leopards (*Panthera pardus*) are brought to Rescue Centres across the country on account of permanent disability, conflict with humans, old age, sickness etc. Shifting wild captured felids to small enclosures inflict stress and hinder their natural behaviour and instincts. In an attempt to provide dense canopy to leopards, enclosures of leopards were enriched with bamboo plantations. Over a period of one year the bamboo plant grew 4 meters tall and arched to provide a dense canopy to the leopards. The leopards were found to utilize the bamboo plantation for resting during the hot hours of the day. Few others were found to bring the offered food to the canopy and enjoy a meal. The bamboo tress was also used as scratch poles by leopards. The observations are encouraging as bamboo plantations can be used in tropical regions to provide a thick canopy to leopards along with a natural insulation against hot climate of the tropics. Utilization of bamboo trees as a natural enrichment has application in leopard captive enrichment without potential hazard probabilities.

ZBC-16

NEW RECORD OF COMMON BANDED PEACOCK (*Papilio crino)* IN SEMINARY HILLS, NAGPUR, MAHARASHTRA, INDIA

Chhapekar S.D.[1*], Shendge A., Chichkhede K.H.[2], Kolangath S.M.[3]
Gorewada International Zoo, Fetri, Nagpur[1]
Forest Development Corporation of Maharashtra Ltd., Nagpur[2]
Wildlife Research & Training Centre, Gorewada, Nagpur[3]
Gorewada International Zoo, Nagpur[4]
schapekar7@gmail.com*

Butterflies are one of the most conspicuous species of Earth's biodiversity. Being extremely responsive to any changes in their environment, namely, temperature, humidity, light, and rainfall patterns. These insects are identified as useful bio indicators. Common Banded Peacock' (*Papilio crino* Fabricius*)* is a gorgeous black butterfly with

green bands on its wings belongs to the family Papilionidae. A long-tailed butterfly comes under the family Papilionidae. *Papilio crino* Fabricius was found in India and Sri Lanka. This butterfly can be seen in the moist and dry forest but the population can be quite higher in scrub jungles and plantations. This butterfly is common in the Vidarbha region except the Nagpur region but sighting of this butterfly in the Nagpur region after the year 1931 by D'abreau indicates the presence of habitat. The Seminary hills area is rich in *Chloroxylon swietenia* which belongs to the family Rutaceae. For the study, three regions have been selected to know the habitat range of the *Papilio crino* butterfly namely, Seminary hills, Ambazari park, Gorewada International Bio-park. During the sighting, the area was less dense, sunny and some records were of flying and basking. We recommend further studies in this species in and around the Nagpur region at the earliest opportunity. Also, we insist on the protection of habitat is an important aspect in the conservation of such species.

ZBC-17

IMPACT OF ANTHROPOGENIC PRESSURE ON WILD UNGULATES IN NAGARJUNSAGAR SRISAILAM TIGER RESERVE, ANDHRA PRADESH

Ashok Kumar[1]*, Yadvendradev Vikramsinh Jhala[1] & Qamar Qureshi[1],
[1]Wildlife Institute of India, Dehradun, Uttarakhand, India
ashok.elephas@gmail.com

Human driven disturbances in a forested area such as encroachment, cattle grazing, fodder, and fuel wood collection by the local communities reside inside the forested area alter not only the species behavior but also their activity. In the Eastern Ghats landscape, Nagarjunsagar Srisailam Tiger Reserve (NSTR) forms a part of Nallamalla hills in the Andhra Pradesh state. In this study, we used photographic capture data to calculate the relative abundance indices for the wild ungulates in NSTR. We quantified the activity patterns and the temporal overlap of six wild ungulates in response to disturbance factors like the presence of humans, dogs, and livestock. We found that sambar and mouse deer are mostly nocturnal, whereas chital and wild pig showed a bimodal activity. Nilgai showed a cathemeral activity, and Chousingha was found to be active during the morning hours, whereas all human disturbance factors were mostly diurnal. Like humans, dogs and livestock were primarily active during the daytime. We removed all photo captures after 1800 – 0600 hours (night data) from the overlap analysis. To understand if human activity alters the diurnal activity of ungulates, we found the highest temporal overlap of disturbance factors with chousingha, which showed a clear overlap with human disturbances, followed by Nilgai, chital, and wild pig showing peak activity in the early morning and Sambar and mouse deer showing

nocturnal behavior avoiding the human disturbance mostly. The present study is the first of its kind in this landscape to look at the impacts of anthropogenic pressure on the temporal behavior of ungulates. The results of this study will be helpful in prioritizing management actions in the disturbed parts of NSTR for the conservation of these important ecological species.

ZBC-18

ASSESSMENT OF WATERBIRD COMMUNITY IN WADANDRA LAKE OF UMRED TEHSIL IN NAGPUR DISTRICT OF MAHARASHTRA (INDIA)

Ashish Kumar Jha and Jagruti Roy
Department of Zoology, Hislop College, Nagpur- 440001, India
ashishkumarjha@hislopcollege.ac.in

The fresh water wetland is rich in floral and faunal biodiversity. Among the faunal diversity, the waterbirds play an important role not only in pollination, dispersal of seeds, predatory on insects as scavenger, food chain balancing but also in the indication of changes in the quality of water due to wetland disturbance and degradation because of their ability to respond quickly to such changes. The present study on waterbird community of Wadandra lake in Umred Tehsil in Nagpur District of Maharashtra (India) was carried out during January 2018 to December, 2019. The methodology followed was mainly observation using binocular and collected information with the help local bird watcher of those particular wetlands. A total 85 species of birds, belonging to 6 orders: *Pelecaniformes, Ciconiiformes, Anseriformes, Gruiformes, Charadriiformes,* and *Coraciiformes* were recorded from the area during the period. The waterbird families were grouped on the basis of foraging behavior as follows: 1) surface and aerial diving birds (*Phalacrocoracidae, Alcedinidae, Meropidae*), 2) wading birds (*Ardeidae, Ciconiidae, Threskiornithidae, Recurvirostridae, Charadriidae, Scolopacidae*), 3) ducks (*Anatidae*), and 4) marsh birds. Red-crested Pochard, Cotton Pygmy-goose, Little Egret and Little Cormorant were common, while the globally-near threatened Black headed Ibis and 15 species of local or regional conservation concern were also observed. Seasonal variation in waterbird assemblage structure reflected the arrival and/or passage of migrants, highest number of birds was recorded in mid-month of November to Post January, and few species were present between May and August. Further studies are required to uncover the factors contributing to the observed seasonal variations in bird assemblage within Wadandra lake, Umred.

ZBC-19

FEEDING ENRICHMENT (USING BAMBOO) TO ASSESS THE WELFARE AND ACTIVE BEHAVIOR IN CAPTIVE SLOTH BEARS

[1]Sameena Iza, [2]Sujay, [3]Mukundachandra B., [4]Ranganatha B. and [5]Divya
[1].Education Officer [2]Assistant Director [3]Executive Director [4]Animal keeper [5]Volunteer
Tiger and Lion Safari, Shimoga
izashaik55@gmail.com

In the wild, Sloth Bear spends a large proportion of the day engaged in foraging and eating. In captive environment, this foraging activity will be reduced to an extent due to easy feeding in captive condition This increases the inactive behavior in captive animals.

Two Sloth Bears of the zoo (Tiger and Lion Safari)were given feeding enrichment which is made up of bamboo ,bamboo is tightly stuffed with some of the favorite food of the sloth bears (honey ,dates ,fruits etc.),this activity increases the feeding time and also keep them better involve with object which is provided for feeding. They also involved with the object by playing with provided enrichment material even after the feeding is done. During normal days these bears usually go to sleep after easy feed by the keepers.

1.During the Test session one (Normal day), recorded the time and type of interaction inside the bear enclosure.

2.During the Test session two (Enrichment day) recorded and compared the time and interaction by the sloth bears during the activity hours.

According to the study their feeding and playing time increases with the enrichment activity rather than the normal days, can also see the level of decreased inactive behavior among the sloth bears during the activity hours.

The main aim of the study is to reduce the inactive behavior and to keep them up with good physical and mental condition of the captive animals.

This concludes that to enhance their level of activity, enrichment should be a part of their captive lives.

ZBC-20

DIVERSITY AND DISTRIBUTION OF SPIDER FAUNA (FAMILY - *Araneidae*) IN AND AROUND KARANJA SOHOL WILDLIFE SANCTUARY, INDIA

*Amrita Shirbhate[1]and Milind Shirbhate[2]
Head, Department of Zoology, Mahatma Phule Arts and Science College, Patur Dist, Akola, Maharashtra, India Department of Zoology, Shankarlal Khandelwal Arts, Science and Commerce College, Akola, Maharashtra, India
amritavyas2008@gmail.com

A study on the diversity and distribution of spider fauna (Family- *Araneidae*) in and around the Karanja Sohol Widlife Sanctuary, India was conducted during February

2018 to November 2020. A total 11 genus and 23 species of family *Araenidae (Arachnida: Araneae)* were recorded. The generic diversity is in the order of *Neoscona* (6), *Cyclosa* (3), *Larinia* (2), *Cyrtophora* (2), *Eriovixia* (2), *Poltys* (2), *Araneus*(1), *Argiope* (1), *Chorizopes*(1),*Gasteracantha (1),Zygiella* (1). The present investigation and checklist will help the forest officials regarding fauna and flora record of the sanctuary in future.

ZBC-21

COLOUR PERCEPTION AND ATTRACTION STUDY IN CAPTIVE SLOTH BEARS (*Melursus ursinus*)

Prajakta Rao[1]&Arun A Sha[2]
[1]Wildlife Data Analyst, [2]Director- Research and Veterinary Operations
[2]Wildlife SOS, Bannerghatta Bear Rescue Centre, Bangalore, 560083
prajakta@wildlifesos.org

The sloth bear is a myrmecophagous bear species with their good sense of smell but eyesight has not been studied much. It is considered that they have an equivalent eyesight as humans; however, based on the number and position of the rods (interpret light) and cones (interpret colour) in their eyes they may not see colours the way humans do. On the other hand, animal coloration studies have been highly researched and the way wild animals mimic and camouflage themselves for their survival, hunting and mating with the functional significance of the color pattern.

An interesting study was conducted to examine whether there is any particular colour attraction in sloth bears which will help to encourage sloth bears in captivity with enclosure enrichments. The quantitative analysis was completed over the period of six months with the sample size of 60 sloth bears from semi-captive environment of Bannerghatta Bear Rescue Centre of Wildlife SOS, Bangalore. The age group between 3 to 28 years, of both the gender (30:30) was studied. We used six colours (Blue, Pink, Green, Yellow, Orange, Red) i.e. 2 colours from each spectrum of colour wavelength (high, medium, low). Outliers were kept at minimum to obtain more accurate data. The results suggest that sloth bears showed a significantly higher attraction at 0.05 confidence interval level towards the colour yellow (for humans) among all the six colours tested. This research could be further undertaken to examine the ability of sloth bears to differentiate between the shades of colours.

ZBC-22

IMPACT OF FEEDING CHICKEN MEAT OVER BEEF MEAT WITH BONE ON GASTROINTESTINAL PARASITES IN CAPTIVE INDIAN LEOPARDS (*Panthera pardus fusca*) – A REVIEW

Nikhil S. Bangar[1], A. Sha Arun[2], Mahendra B. Dhore[3]
[1]Wildlife Veterinary Officer, Manikdoh Leopard Rescue Center, Wildlife SOS [2]Director – Research and Veterinary Operations- Wildlife SOS
[3]Assistant Veterinary Officer, Manikdoh Leopard Rescue Center, Wildlife SOS
nikhil@wildlifesos.org

Leopards (*Panthera pardus*) are the most widespread group of wild felids. However, their population is decreasing in a similar range to other large carnivores and has been classified as vulnerable by the International Union for the Conservation of Nature (IUCN) and recognized the nine subspecies. An observational study was conducted from August 2010 to August 2020 in two phases, i.e. phase 1 (August 2010 to August 2015) and phase 2 (September 2015 to 2020). A total of 532 fecal samples (266 from phase 1 and 266 from phase 2) were collected from captive leopards to assess the impact of feeding on gastrointestinal parasites provided with different feeding patterns on these two phases. During study period of Phase I their diet mainly consists of only beef meat with one day off in a week and in Phase II was fed only on chicken meat with two days off in a week. The prevalence of parasitic infection in the conducted study phase one was 29.69% (79/266), and that of phase two was 8.65% (23/266), with an overall prevalence of 19.17% (102/532) from the total sample studied. Results indicate that leopards suffered from more types of parasites when was fed on beef meat than chicken meat and in both phases of study leopards mostly infected by nematodes preferably *Toxocara* spp. Therefore, it is observed that the chicken meat has some advantage over beef meat with respect to gastrointestinal parasites, so this factor could be considered when the feeding formulation for captive leopards are designed, as ruminants preferably serve as intermediate host for most of the parasites.

ZBC-23

VERTICAL STRATIFICATION OF BIRD SPECIES FROM A HERONRY IN THRISSUR KERALA

Ambika Nandini R Menon[1]and K Syamala[2]
1.Dept. of Environmental Science, Central university of Rajasthan
2. College of Veterinary and Animal sciences, Mannuthy
iamambikanandini@gmail.com

Heronries are communal nesting colonies of waterbirds. They breed during the onset of the southwest monsoon to avoid competition with other migratory birds. The

present study was conducted to survey the heronries located in the collectorate campus of Thrissur district, Kerala to understand the vertical stratification of horonaries and location of nesting. The heronries were found close to the areas where the human settlements were there. Four different species of birds (Oriental darter, Pond heron, Night heron, Indian cormorant) were observed to occupy the trees namely, Casuarina, Euclayptus, milk fruit tree, Neem and the Flamboyant tree. In trees where all the four were nesting, the bird with higher body mass was found to nest in the higher strata and the bird with lower body mass was found to nest in lower strata. The main purpose of these bird colonies is to combat predation pressure to avoid their natural predators like crows and Brahminy kites. Hence they usually nest in the urban landscapes. The conservation of heronries is essential because they include birds whose global IUCN status is Near-threatened and needs to be conserved.

ZBC-24

HIGHLIGHTS OF AN ANIMAL KEEPER WORKING IN A LEOPARD ENCLOSURE OF TIGER AND LION SAFARI, SHIMOGA

Nagendra Naik[1], Ranganatha B[1] and Sujay Suresh[2]
[1]Animal Keeper, Tiger and Lion Safari, Shimoga
[2]Veterinary Officer, Tiger and Lion Safari, Shimoga
sujay.18july@gmail.com

Nagendra Naik, Aged 43, has been working in Tiger and Lion Safari, Shimoga for about 24 years in a temporary pay roll. He started his carrier as a bear keeper and then moved on to leopard keeper 19 years ago and still continues to do his duties taking care of 18 leopards. At a point he used to single handedly take care of 27 leopards housed in the zoo. With limited holding houses he used to pair them based on their social behavior during the nights and feeding time. He has shown keen interest in making a garden around his enclosure in his personal time. He actively participates in the enrichment activities and also comes up with his own designs during implementation. It is very difficult to keep an over crowed enclosure clean and he makes sure that the enclosure is cleaned regularly. His keen interest lies in hand rearing and nursing of orphaned or neglected cubs and has worked day and night for the same. His favourate animal is leopard Rani, 8 yrs and had reared and spends lots of time with her and she reciprocates the same. Basic positive reinforcement skills have been taught to her by him for veterinary examination. He has also taken care of our melanestic leopard cub which was born in captivity. He has actively participated in rescue operations with veterinarian of gaurs, bear, leopards, tigers and snakes.

From the past 6 years another animal keeper has been assigned to him, Ranganatha, 35 yrs and had experience working s an assistant keeper in the tiger enclosure. Ranganatha also works as a compounder in the Zoo hospital and as knowledge of basic dressing and emergency drugs and veterinary procedures.

Improved salary structure and higher risk allowances are something which they feel has to be implemented. The duo manages our leopards and upkeep of the enclosure which involves potential life threatening risks every day and every moment of their lives.

ZBC-25

CRITICALLY ENDANGERED INDIAN VULTURE VERGE OF EXTINCTION

Akriti Ballabh
College of Veterinary & Animal Sciences,
G.B. Pant University of Agriculture and Technology, Pantnagar-263145
akritibs161241@gmail.com

The Indian vulture (*Gyps indicus*) is an Old-World vulture native to India, Pakistan and Nepal. India is most favourable region for Vultures but it has been listed "Critically Endangered" by Bird Life International, as the population severely declined. These declines are continuing and are due to abnormally high rates of both nesting failure and adult, juvenile and nestling mortality. Affected birds exhibit signs of illness (neck drooping syndrome) for approximately 30 days prior to death. Epidemiological observations are most consistent with an infectious cause of this morbidity and mortality. Significant post-mortem findings included visceral gout, enteritis, vasculitis and gliosis. Although the causative agent of the declines have not identified, the results of pathological studies are most consistent with those for an infectious, probably viral, aetiology. Vultures which are exposed to diclofenac and other NSAIDs through scavenging on the carcasses of largely ruminants that have been treated with the drugs prior to death and left for scavengers to consume they are unable to process diclofenac and other vulture-toxic NSAIDs that causes renal failure and death. The drug was banned for veterinary use in India from March 2006. A replacement drug was quickly developed and proposed after tests on vultures in captivity: meloxicam which affects cattle the same way as diclofenac but harmless for vultures. Many vulture safe zone and Vulture Restaurants are established in various states of India to provide them healthy and safe food. Proper conservation efforts are still in needed to be planned in well-organized manner for preventing this menace.

ZBC-26

STUDY OF AVIFAUNAL DIVERSITY IN AND AROUND MANDATUKUM LAKE OF MUL TEHSIL, DIST. CHANDRAPUR

G. A. Chaudhari[1]& Shashikant Sitre[2]
[1]. Research Scholar, CHLR,
[2].Department of Zoology,N. S. College of Science and Arts Bhadrawati,Dist- Chandrapur,(MS)
gurugayatri12@gmail.com

Birds are excellent bio-indicators and it is useful for studying a variety of problems in the environment. Study about avifaunal biodiversity of Mandatukum Lake of Mul Tehsil, District-Chandrapur prevailing water condition and environmental biodiversity of the region was observed along with the avifauna present in the region. The study was carried out from January 2019 to January 2020 in which 64 species of birds were recorded.

ZBC-27

RARE SIGHTING: DUSKY EAGLE OWL (*Bubo coromandus*) IN NAGPUR TERRITORIAL FOREST RANGE, MAHARASHTRA

Vinit Arora
Shrusti Paryavaran Mandal
W park Road, Dhantoli, Nagpur-440012
vinitarora75@gmail.com

Nagpur district in Maharashtra have photographic documentation of about 11species of owls from the family of Strigidae. I would like to register the first photographic record of a pair of Dusky Eagle Owl (*Bubo coromandus*) from Nagpur district from Paoni range of Nagpur territorial forest, Nagpur, Maharashtra. There has been single record of this species from Chandrapur district of Maharashtra only apart from a few in Madhya Pradesh.

ZBC-28

SENSITIZING THE ANIMAL CARE STAFF FOR THE IMPORTANCE OF ENVIRONMENTAL ENRICHMENT FOR THE BETTER QUALITY OF LIFE IN CAPTIVE WILDLIFE

Saddam Husen[1], G M. Vishwanath[1]and Prakash G P.[1]
[1]Bear care staff, Wildlife SOS, Bannerghatta Bear Rescue Centre, Bangalore 560083
bbrc@wildlifesos.org

Wildlife SOS has played an important role in rescuing Sloth bears (*Melursus ursinus*) in India, Bannerghatta is the world's second largest Bear Rehab Centre for sloth

bears. The rescued sloth bears are accommodated here in a semi-captive environment. In captive environment, enrichments are creatively designed by veterinarians, biologists and animal care staff to ease the transition of getting them used to live in their natural habitat.

Enrichments can be of five types social, occupational, physical, sensory and nutritional. These types of enrichments are regularly being used to reduce the stress in captive wildlife. These wild animals often develop stereotypy like pacing, regurgitation, head weaving, head rotation etc., which are indicative of boredom and distress. It indicates that these wild animals are deprived or left with little opportunities to express their natural behaviors or facing stress. Various structural enrichment like hammocks, elevated platforms, swings, see-saws, puzzle feeders, wobble tree, tree houses, resting dens, etc. have been installed to improve their physical activity. Sloth bears are very good problem solvers and explorers therefore, lot of puzzle feeders, tender coconuts are given to engage them both physically and mentally, hiding feed items in different places to encourage the animals to use their olfactory senses and also to initiate the foraging behavior that would push them more towards their primal instincts.

ZBC-29

DIVERSITY AND HABITAT PREFERENCE OF PRAYING MANTIDS IN GOREWADA RESERVE FOREST, NAGPUR, MAHARASHTRA

Chhapekar S.D.[1*], Kolangath S.M.[2], Chichkhede K.H.[3], Sawant D.[4], Pawshe M.D.[5], Shalini A.S.[6]
Gorewada Rescue Centre, Fetri, Nagpur[1]
Wildlife Research & Training Centre, Gorewada, Nagpur[2, 5&6]
Gorewada International Zoo, Nagpur[4]
Forest Development Corporation of Maharashtra Ltd., Nagpur[3]
schapekar7@gmail.com*

India is one of the 18 mega diversities in the world. 21 % of the geographical area is under forest cover. The tropical climate of the country provides a conducive environment for many life forms to thrive and grow. There are 63,880 species of insects in India which is 5.97% of the total population of insects in the world. Mantidae family consists of 434 genera and 2300 known species around the world. They are commonly referred to as 'praying mantises owing to the prayer posture of the forelegs. A study was carried out from September 2018 to September 2019 at Gorewada Reserve Forest which is located 8 kms from Nagpur city. The geographical location of the study area is 21°11'N 79°2'E located 336 m above sea level. The study area of 19.14 Sq. Km. was surveyed and attempts to locate mantids were made. Visual encounters were recorded to

prepare the checklist. Photographic documentation was done using a digital camera (Model Canon 1100D) and a mobile camera (Redmi Note 3). The sites were visited in the morning, noon & evening hours to locate mantids, the records of species, date, time, location, and habitat were accordingly maintained. For the species identification reference books, experts and publications were referred. During the study, no collection was performed. Based on the current study a checklist of common species of mantids found in Gorewada Reserve Forest was prepared. A total of 9 species were identified belonging to 9 genera and 5 families.

ZBC-30

BIOMASS-BASED FUEL TO MAKE PORRIDGE FOR RESCUED SLOTH BEARS

Allauddin[1] and Dada peer[1]
[1]Bear Kitchen in charge, Wildlife SOS, Bannerghatta Bear Rescue Centre, Bangalore 560083
bbrc@wildlifesos.org

Sloth bears are native to the Indian subcontinent. Wildlife SOS is an organization known for eradicating a 400-year-old “dancing bear” practice in India and providing lifetime care facilities for all these rescued sloth bears. These sloth bears are situated in world’s second largest sloth bear rescue centre of Wildlife SOS, in Bangalore. Having witnessed brutal acts of the kalandar community for the initial period of their life, they have lost their canines. Therefore, the semi-liquid diet is provided to maintain their eating habits and health. Their nutritive diet includes porridge made up of Ragi, Jowar, Bajra, Soya as a main ingredient along with Honey, vegetables, eggs, milk and fruits. The food preparation takes three hours for one-time meal and it’s been done twice a day in the eco-friendly bear kitchen. Each meal would be around 800 to 900 litres of porridge made at one go in a giant cooking vessel for 72 rescued sloth bears. This initiative aims at reducing green-house emission by disseminating biomass based improved cooking stoves and biomass-based water boiler for cooking bear food. Biomass briquettes are nothing but agricultural and animal waste. The idea is to replace LPG (a fossil fuel) which was used for cooking purposes. Considering LPG is replaced by a biomass cooking stove each year we reduce emissions by approximately 196 $_{t}$CO2. This green kitchen not only reduces emissions but also encourages use of biomass as a sustainable energy resource and prevent fire wood utilisation and deforestation activity.

ZBC-31

A STUDY ON BIOLOGICAL RHYTHMS OF HIMALAYAN YAKS

Mohd Iqbal Yatoo, Mir Shabir, Syed Shafat Kubrevi, Rukhsar Ahmad Dar, Kunzes Angmo, Maheshwar Singh Kanwar, Riyaz Ahmad Bhat, Muheet and Oveas Raffiq Parray
Sher E Kashmir University of Agricultural Sciences and Technology of Kashmir, Shalimar, Srinagar-190006, India,
iqbalyatoo@gmail.com

This study explores biological rhythms in Himalayan yaks. Indicators of reproductive, physiological rhythms and health were evaluated in 26 representative yaks from as many yak herds in 26 villages/hamlets of Changthang Ladakh (India). Average life span (20.57 ± 0.39 years), body weight (200–650 kg), age of puberty (2.1–2.9 years), oestrus period (21.1 ± 0.29 days), oestrus duration (16.9 ± 0.7 h), and gestation length (259.73 ± 1.48 days) was recorded. Seasonal breeding (spring/summer) with parturition cycle starting in spring season, was noticed. Single calving and singlet births were noted. Migration starts in April–May and returns in September–October. Common feeding practice includes pasture grazing. Hemoglobin (g/dl), packed cell volume (%), total erythrocytic count ($x10^6$) and total leucocytic count ($x10^3$) ranged from 12.29-14.56, 36.88-43.7, 7.28-7.79, and 8.43- 7.15 during summer and winter, respectively. Rectal temperature (◦F) was 99.78-101.13, respiration rate (breaths per minute) was 34.23-65.38 and heart rate (beats per minute) was 68.65-99.04 during winter and summer, respectively. Seasonal cyclicity of common infectious and non-infectious diseases was noted. In conclusion, this study provides baseline data of biological rhythms of yaks and elaborates their seasonal variation with emphasis on future management prospects.

ZBC-32

CONSERVATION OF PREDATORS AND PARASITOIDS OF COCONUT BLACK HEADED CATERPILLAR (*Opisina arenosella)* WALKER IN ARSIKERE REGION OF KARNATAKA STATE

G.S. Chandrashekar*, Prasad P. S*, H. P. Maheswarappa**, R. Siddappa*, and Vishnuvardhana***
*AICRP on Palms, HREC, Arsikere, University of Horticultural Sciences, Bagalkot, Karnataka, India. **ICAR-Central Plantation Crop Research Institute- Kasargodu, Kerala, ***RHREC, Bengaluru, UHSB, Karnataka,
chand10sekar@gmail.com

The coconut palm is infested by a number of insect pests. Among them, *Opisina arenosella* Walker causes the severe damages to the foliage, depriving the palm of its photosynthetic area and thus, directly affecting the yield. The black headed caterpillar is one of the serious and endemic pests of coconut in India. Caterpillars of this oecophorid

prefer to live in a gallery of frassy material and they feed on leaf chlorophyll matter. It is attacked by many entomophagous insects during its developmental stages. Among them, *G. nephantidis* is a gregarious larval parasitoid and responsible for the reduction in the population pest under field conditions. A roving survey was conducted at Horticulture Research and Extension Centre, All India Co-ordinated Research Project on Palms, Arsikere, Hassan district, Karnataka state during the year of 2018-19 and 2019-20. Field observations were conducted in four geographically similar locations within Arsikere, twice each year. The recorded list of natural enemies against this caterpillar comprised of *Brachymeria nosatoi* (Hymenoptera: Chalcididae), *Bracon Brevicornis* Wesmael (Hymenoptera: Braconidae). *Bracon hebetor* (Hymenoptera: Braconidae), *Apanteles taragamae* Viereck (Hymenoptera: Braconidae),*Xanthopimpla* sp. (Hymenoptera: Ichneumonidae), Among insect predators, *Cardiastethus exiguus* Poppius, (Hemiptera :Anthocoridae), *Parenanigro lineata* (Chaudoir). (Coleoptera: Carabidae), Birds, ants, spiders, grasshoppers, mites and some other species of Anthocoridae, Reduviidae and Carabidae have been recorded feeding on *O. arenosella*. The parasitoids were able to self-perpetuate successfully and managed the pest population in all the black headed caterpillar-affected gardens in the villages of Arsikere Taluk. The larval parasitoids *G. nephantidis* (47.12 %)and *B.brevicornis* (21.54 %)were found more efficient in reducing black headed caterpillar population with higher per cent parasitization compared to other parasitoids and predators. The process of biological control is a cost-effective and environment-friendly method that does not introduce pollutants into the environment and is the best alternative to the chemical or the mechanical control methods. The bio control response showed the happiness among the farmers about the role of bio-agents in suppressing the pest without application of chemical pesticides. So there is need to conserve the predators and parasitoids on pests of coconut without spraying of harmful chemical insecticides in the field.

ZBC-33

RANGING AND MOVEMENT PATTERNS OF ELEPHANTS IN NORTHERN CHHATTISGARH

Ankit Kumar, N. Lakshminarayanan, Bivash Pandav and Ankush Dubey
Wildlife Institute of India, Dehradun, Uttarakhand
drankush.dubey@gmail.com

There are just over two to three hundred elephants in the state and they currently occur in vast swathes of forests spanning several districts in Surguja, Bilaspur and Raipur forest circles and yet, there is intense conflict between people and elephants culminating into a major social, economic, political and conservation problem. In response to prevailing conflict situation, a long-term study was initiated in response to understanding

of elephant conflict situation by focusing on patterns of dispersal and ranging behavior of elephants. During this period, three elephants CGM001 (Behradev), CGF010 (Gautami) and CGM003 (Pyare) were fitted with satellite cum VHF collars. These three satellite-collared elephants provided valuable details on how elephants use the mosaic landscape in Surguja circle. CGF010 (Gautami) and its group have also provided valuable insights on the inter-state movement of elephants as well. Home range of Behravdev, Gautami and Pyare were estimated to be 1170.80 km², 2337.50 km² and 997.00 km² respectively (using Minimum Convex Polygon approach – 95%). Utilization distributed (95%) were also estimated to be 280 km², 334.70 km² and 235.10 km² for Behradev, Gautami and Pyare respectively. In addition to collared elephants, some individually recognized elephants were monitored to understand their ranging patterns using a re-sighting approach. In particular, we have observed elephants CGF002 (Torn Ear) and CGF003 (Wave Ear) and their herds for a longer duration and computed their home ranges using a Minimum Convex Polygon (MCP) approach. Home range for Torn Ear and Wave Ear were estimated (MCP – 95%) to be 8484.46 km² and 385.49 km² respectively. The individually recognized elephants have also helped us in understanding the patterns of recent range expansion of elephants from Chhattisgarh into Bandavgarh and Sanjay Tiger Reserves in Madhya Pradesh.

ZBC-34

STUDY OF ECOLOGY AND DIVERSITY OF AM FUNGI ASSOCIATED WITH TEST PLANTS

Mohd.Irfan
Department of Botany, ChamanLal Mahavidhyalya, Landhaura, Haridwar-247664
irfanclm17@gmail.com

Diversity of AMF attempts the coexistence of both symbiotic partners. Several mechanisms of interaction are involved between AMF, plants and the soil environment, which can further influence plant species coexistence and the maintenance of biodiversity within plants communities. Methods for studying AM fungal diversity and the ecology of the symbiosis have been wholly reliant on the morphology of the spore phase. The spores after isolation can be separated under a stereoscopic microscope based on the characters such as colour, size, shape etc. Study of arbuscular mycorrhizae (AM), involves association of anatomical structures like: arbuscules and vesicles of mycorrhizae fungi found within the root cortex to various physiological or ecological processes.

AM fungi are found repeatedly in different part of the world, in diverse environments, like; semi–arid site in Australia and also occurred in a species rich

meadow in the north of England where completely different kinds of soils, vegetation and climate in the two ecosystem. Due to some physico-chemical properties of soil at different sites, AM fungal species show different adoptability in the soil and colonization in the roots of plants. Many species were recorded in poor numbers with low frequency.

Present study concludes that it will be beneficial to isolate the indigenous AM fungi associated with the host plants and use them as bio-inoculants to improve the cost of production as they have ability to exploit the conditions prevailing in the rhizosphere of host plants.

ZBC -35

SUCCESSFUL HAND REARING OF NINE NILGAI CALVES

Pawshe M.D., Shalini A.S., Upadhye S.V., Dhoot V.M., Kolangath S.M. and Patil M.S. and Gawande A.P.
Wildlife Research and Training Centre, Gorewada, Nagpur
Opp. Hindustan Lever Godown Square, Mahurzhari Road, Fetri, Nagpur 441501
drmayurpawshe@gmail.com

Nine orphan Nilgai calves between 15 to 20 days were brought to Wildlife Research and Training Centre, Gorewada, Nagpur. The calves were fed with cow milk, concentrates and greens in increasing proportions as per their requirement. The weight gain and milk intake on weekly basis is reported. Food supplements viz., multivitamins and mineral mixture were also given deworming and Vaccination were done as per the schedule.

ZBC -36

NESTING BEHAVIOR OF BIRD SHIKRA (*Accipiter badius*) ON NEEM TREE

Pandurang S. Pakhale and Dnyneshwari P. Pakhale
Range Forest Officer, Gorewada Project,Nagpur.
pspakhale@gmail.com

The shikra is a small bird of prey in the family Accipitridae found widely distributed in Asia and Africa. In the month of February 2020 a pair of shikra started collecting nesting material and building nest on Neem tree (*Azadirachta indica*) at a height of 20-22 meters. Strangely this pair was also building another nest on the Saptapari (*Alstonia scholaris*) tree just 20 meters away from the Neem tree. We were surprised to see that single pair is building two nests at the same time. Reasons may be many this year summer season might be much harsher, so when the neem tree shed its

leaves the pair may prefer to move to other nest built on the evergreen tree. Another reason may be chances of storm or heavy rainfall so for safety built another nest. Male was very active in collecting the nesting material i.e. twigs and small tree branches. We observed that in the month of March male was more vocal and frequency of mating has increased. Male used to make loud mating call. Before mating male use to offer kill to female. He used to mount on female even while she was busy in eating the kill. Male used to visit nearby tree and break a twigs by its beak some time hold its beak and even in its feet. We observed that each time male used to visit different tree for collection of twigs. The bird collected nesting material (from dried branches)from trees of Jamun, Copper-pod (*Peltophorum pterocarpum*), Subabul (*Leucaena leucocephala*), Ashoka (*Saraca asoca*), Neem (*Azadiracta indica*), Mango (*Magnifera indica*) etc. While building nests many a times twigs were felling down, but this fallen material was never used for nesting by the shikra pair. Each time it use to visit different trees and collect the twigs. In the month of May we found that three chicks were hatched in the nest which was built on the Neem tree.

ZBC -37

COPROPHAGY (ALLOCOPROPHAGY) IN BIRD RED-VENTED BULBUL (*Pycnonotus cafer*)

Pandurang S. Pakhale and Dnyneshwari P. Pakhale
Range Forest Officer, GorewadaProject,Nagpur.
pspakhale@gmail.com

I was observing the nest of Red-vented Bulbul (*Pycnonotus cafer*), three chicks were chirping in the nest. Nest was built on Hivar tree (*Vachellia leucophloea)* barely at a height of 10 feet from the ground. This place was very busy and full of tourists and visitors. Adult bulbul pair was very busy in feeding the chicks. Adult bulbul used to bring number of insects and feed their chicks. I observed unique behavior by the adult Bulbul; as soon the chick is fed, it immediately pooped and the adult bird hold it in a beak engulf it. I observed this nest for 50 minutes, and found that this activity was repeated for 3-4 times almost with all the chicks. On 13th October 2019 at 11:03 hrs the adult bird fed its chick and engulf poop immediately after feeding.

This behavior of Coprophagy (allocoprophagy) in adult Red-vented Bulbul (*Pycnonotus cafer)* might be to avoid the wastage of the food material which is hard earned.

ZBC -38

SOCIAL STRESS INDUCED ANOREXIA IN A FEMALE MUGGER CROCODILE

Vanishree[1], Nikita Salian[2] and Sujay CS[2]

1. Veterinary Officer, Sri Atal Bihari Vajpayee Zoological Park, Kamalapur, Hospet,Karnataka.
2. PG Scholar, MVSc Wildlife, Veterinary College Hebbal, Bangalore
3. Veterinary Officer and Incharge Assistant Director, Tiger and Lion Safari, Shimoga.

The well enriched crocodile enclosure at ABVZP, Kamalapur, had a group of 13 mugger crocodiles, among which a pair of crocodiles were showing dominant behavior. On contract to this a 10 year old female mugger was submissive and was always being attacked by the dominant male. The submissive animal was reported to be anorectic for more than a month. On examination, general condition of the mugger was weak with prominent visibility of occipital bone and vertebrae. Animal was not active and scutes was rough and pale. Fecal sample examination was clear and blood sample examination couldn't be performed. Animal was treated symptomatically with long acting ceftiofur and oral liver supplements for about a month, but, there was no improvement in health condition. The sick animal was isolated from the group and shifted to another enclosure. After a week of isolation animal started to consume meat. Over a period of month, overall condition of the animal improved and it was shifted back to it's original enclosure. However, the crocodile started showing similar signs of anorexia and weakness upon reintroduction into the group. Again the health of and condition of the animal improved after isolation without any treatment and supplements. Social stress is also a contributor factor for health of the crocodiles.

ZBC -39

STUDY ON EFFECT OF LOCKDOWN ON BIRDS, BREEDING, MIGRATION, LAKES & ITS HABITAT IN NAGPUR DISTRICT (M.S.), INDIA.

Avinash Londhe[1], Pooja Surkar Thakre[2], Minal Bhusari[3], Sanket Dharashivkar[4] and Harish Dhumal[5]

[1] Bird Researcher & Professional Photographer, Owner of Devashri Photographic Services,[2]Bird Researcher & Ecologist, [3] Bird Watcher, Wildlife enthusiast & Preparing for Competitive Examination. [4] Bird Watcher, Wildlife enthusiast & Photographer, Property Development Expert in Systra MVA Consulting India Pvt. Ltd. [5] Bird Watcher & Wildlife enthusiast & Owner of Seva Medical

aslondhe.ngp@gmail.com

The aim of the study was to scientifically observe the lockdown effect on birds, there migration, breeding behaviour lake area including its habitat in Nagpur District of Maharashtra, India.

The observations were conducted in the study area between 1st June 2020 to September 2020 in First Phage & from 1st October 2020 to 31st January 2021 in Second Phage, adequately covering two breeding seasons i.e. Summer & Winter. The observation of foraging, pair formation, courtship display, mating, nest site selection, nesting, incubation, rearing of chicks and parental care were recorded. The events were recorded from a hide constructed in ipomoea reeds as well as from the ground or by sitting in a four wheeled vehicle. Condition of Lakes & its Habitat by photographic and notes on the same. All readings and timings of visits, rains, nesting and other observation were recorded. Inter and intra-species reactions with birds were monitored and recorded during all activities. Reaction of Ground Nesting Birds to grazing animals, ungulates, stray dogs and also occasional passing bullock carts, tractors etc. were also noted.

The observations in the study area were conducted by 4 persons, including the authors, for a minimum of 9 hours per day once or twice in a week during the months of June to September during morning to evening. However, during incubation the observations of nest were recorded 3 hrs in the morning & 3 hrs in evening for the entire day. For the purpose of observation two 8x40 and 12x50 binoculars, three DSLR cameras of reputed make were used.

All precaution taken during the study for Covid-19. We follow all the instructions given by the Nagpur Forest Department & Government of Maharashtra indicated in the permission letter.

Following conclusions were drawn on the basis of above observations.

1. The Birds breeds in dried up lake bed of an inland lake surrounded by forest or forest like area is increases and succeeded than last 7-8 years in all species recorded.
2. The birds in the breeding were comfortable as there is no disturbance in lake area.
3. Dried-up cow dung is used for effectively camouflaging nests, eggs and nestlings. As species do nesting on ground does not use additional material for making nest, it probably makes difficult for predators to locate the nest.
4. Local & Other migration of Birds for breeding in study area seen is large in number recorded than previously recorded.
5. Habitats of Lakes are flourishing nicely in lockdown as no disturbances seen.

ZBC -40

SARS-COV-2 SPILLOVER FROM WILD ANIMALS: DECIPHERMENT AND MITIGATION OF ZOONOSIS

Priyanka
Independent Researcher, 07, Type IV Quarter, College of Veterinary Sciences and Animal Husbandry,
Central Agricultural University (I), Selesih, Aizawl-796015, Mizoram, India
priyanka7malik@gmail.com

As the world stands devastated by the coronavirus disease 2019 (COVID-19), the importance of identifying the root cause should be at par with the efforts to overcome this pandemic. In the past few years, the wild animals have been linked to the transmission of severe zoonoses such as Severe Acute Respiratory Syndrome (SARS), Ebola, Middle East Respiratory Syndrome (MERS), Human Immunodeficiency Virus (HIV) infection, rabies, and leptospirosis. The COVID-19 outbreak has been traced to the wet markets of Wuhan, China, which resulted due to the jumping of the species barrier for severe acute respiratory syndrome coronavirus 2 (SARS-CoV-2) as a result of the close proximity between wildlife and man. Factors such as high rate of mutations in receptor binding domain of spike and genetic recombination cause emergence of novel coronaviruses (occuring backstage in a wide variety of wild animals) with wide host range and altered pathogenicity and transmissibility. Research studies have speculated the involvement of bats and pangolins in SARS-CoV-2 transmission. Wild animal species such as pangolins are used in traditional medicine and pose a grave public health risk. High genetic similarity (96 percent) of SARS-CoV-2 to bat CoV indicates that bats may have been the source of this spillover to humans whereas, the pangolins have been suggested to be the intermediate host apart from the investigations pointing to ferrets, snakes, etc. Conclusively, as the efforts are underway for the confirmation of wildlife species involved in the emergence of COVID-19, the global authorities should take lessons from this pandemic as well as the previous zoonotic outbreaks which originated from wildlife and implement stringent laws concerning the ban on the wet wildlife markets, exclusion of wildlife from traditional medicine and regulation of wildlife trade.

ZBC -41

STUDIES ON DIVERSITY OF GASTROINTESTINAL PARASITISM INFECTION IN WILD HERBIVORES

Bhaydiya Nilesh, Rokde Amol, Singh K. P. and Sharma Gurudatta
School of wildlife Forensic & Health, NDVSU, Jabalpur, MP,
amolrokde@gmail.com

Wild animals are integral parts of biological world. Continuous monitoring of wild animals is necessary to access the impact of wild animals on natural environment

and human. Fluctuation in population size of particular wild animal species may alter the balance of ecosystem in nature. Parasitic diseases have become a major concern in conservation of endangered species as they can lead to mortality, dramatic population decline, and even contribute to local extinction events. The Wildlife interface regions, adjoining regions of forests serve as potential marker zones that serve to intermediate buffer zones that provide the viable ecology for the transit of various parasites between domestic and wild animals sharing the same landscape. In animals living in natural state unconfirmed parasites are always present but usually in small numbers with balanced system, but change in environment, stress, nutrition and water intake level might increase sensitivity of animal with parasite infection. The present study conducted on gastrointestinal parasites surveillance in Satpura Tiger Reserve was undertaken. The total 270 faecal samples were collected from three different part of Tiger Reserve. Out of 270 faecal samples of wild herbivores 47.03% comprising were positive for parasitic infection. The prevalence of Strongylus spp. was maximum (16.29%) followed by Amphistomes spp. and Moniezia spp. (8.88%), Coccidia spp. (8.51%), Strongyloides (5.92%), Trichuris spp. (5.18%) and Fasciola spp. (2.96%). Out of 90 Chital (53.33%), 90 Sambar (46.66%) and 90 Gaur (41.11 %) were positive for mixed parasitic infections. The prevalence of Strongyle was highest in all three species namely chital (18.88%), sambar (15.55%) and gaur (14.44%). During rainy seasons prevalence rate recorded in chital was highest (73.33%) followed by Sambar (63.33%) and Gaur (50%). The Overall EPG/OPG of Strongyles and Coccidia spp. in Chital was highest (188.8+49.06).

ZBC -42

FEEDING GUILDS OF AVIFAUNA OF NAVEGAON NATIONAL PARK, MAHARASHTRA, INDIA

Chinchkhede K.H. and Kedar G.T.
Dept. of Zoology, Govt. of Maharashtra's Ismail Yusuf College,
Jogeshwari (e), Mumbai.
kalpcrfo6184@gmail.com

Birds play their immensely important part in the ecosystem perfectly. Out of more than 9,000 bird species of the world, the Indian subcontinent contains 1300 species or over 13% of the world's bird species. The present study deals with the feeding guilds of the various species of birds recorded in Navegaon National Park, Maharashtra. A sample study area of 32.398 sq km of the National Park that lies to the South Western region of the Park was selected for the purpose of intensive study. The study area was visited on a monthly basis for a period of 3 years from Jan 2010 to Jan 2013. Binoculars (Olympus 8X40) were used for collecting the data on the feeding habits of the present avifauna.

Digital camera of the brand SONY model-DSC-H7 was used for photographic evidences. "Point-count" method was used for the present study. Local bird experts were interviewed regarding the feeding habits and other details of the avifauna.

We recorded 167 species in the study area. Out of these, 142 species could be observed feeding. The feeding guilds were codified and divided into 8 categories, viz., Insectivore (In), Omnivore (Om), Carnivore (Cv), Herbivore (Hr), Piscivore (Pi), Frugivore (Fr), Granivore (Gr) and Nectarivore (Ne). Most of the species preferred more than one food type and showed wide range of feeding guilds, and so they were placed in multiple feeding guilds. Majority of birds preferred insects (58.45%), followed by carnivores (26.06%), frugivores (19.01%), granivores (18.31%), omnivores (13.38%), piscivores (12.68%), nectarivores (9.15%) and the lowest number of species were grouped as herbivores (2.11%). The study area supports a wide range of species with varied food preferences and thus helps to maintain a healthy avifaunal population.

ZBC -43

OPPORTUNISTIC PATHOGENSREPORTED IN RESCUED WILD ANIMALS

R V Jadhav, A G Dubey, N K Nighot
Director, Rajiv Gandhi Zoological Park and Wildlife Research Center Pune
drankush.dubey@gmail.com

Rajiv Gandhi Zoological Park and Wildlife Research Center Pune, has establish wildlife rescue and rehabilitation center to look after injured, sick and abandoned wildlife from free range conditions. While number of animals from different species with various health problems are admitted to the rescue facility most of the cases found to be animals with traumatic injuries. While deciding treatment modalities Antibiotic sensitivity test and isolation and identification of organism from wound discharge is usually practiced for the effective treatment. Some of the common pathogens isolated are Citrobacter freundii Complex, Klebsiella oxytoca, Acinetobacter iwoffii, Enteriobacter aerogenes, Proteus mirabilis, Pseudomonas aeruginosa, Serratia marcescens. These pathogens are opportunistic and can potentially transmit the infection in humans. Serratia marcescens is reported less in animals but infection may acquire through Nosocomial infection while handling wild animals for clinical procedures.

Antibiotic Sensitivity Test help make choice of antibiotic for effective treatment. A study conducted on rescued reptilian species reported common pathogens like Citrobacter freundii Complex, Klebsiella oxytoca, Acinetobacter iwoffii, Enteriobacter aerogenes, Proteus mirabilis, Pseudomonas aeruginosa. Many of this organisms are

opportunistic pathogens of humans and may affect urinary system, respiratory system, and biliary system, piperacillin, Tazobactam, cefotaxim, Amikacin, Gentamicin, Cefeprime, are some common antibiotics found for treatment.

ZBC -44

SUCCESSFUL HAND REARING OF ALEXANDRINE PARAKEETS

Pawshe M.D., Upadhye S.V., Dhoot V.M., Kolangath S.M., Shalini A.S., Gawande A.P., Patil M.S., Bhadane B.K. and Khante G.S.
Wildlife Research & Training Centre, Gorewada, Nagpur
Opp. Hindustan Lever Godown Square, Mahurzari Road, Fetri, Nagpur - 441501
drmayurpawshe@gmail.com

Alexandrine Parakeets (*Psittacula eupatria*) Nos. 219 were seized by the Department of Forest at Deori Dist. Gondia. The parakeets were sent to Wildlife Research & Training Centre, Gorewada, Nagpur for care and hand rearing. The birds were of varied age, most of them were two – three weeks old. The birds were received at WRTC, Nagpur and following examination were housed in groups of 25 birds in cages of appropriate sizes. The birds were initially provided sugar and Vitamin C through water using feeder tubes. Moong dal paste and commercially available food was fed using customized cone feeders. The birds were provided brooding care and were kept in draft free environment. The birds were examined daily for signs of distress. The birds were exposed to sunlight in the early morning hours. After the birds were one month old, fruits like apple, pomegranate, guava, maize, green peas etc. were provided. The birds were transferred to the large enclosures for flight training. Artificial perches, feeders and waterers were arranged. The birds were kept under care until they were found fit to be released in the wild.

ZBC -45

EMERGENCE OF ZOONOTIC DISEASES DUE TO HUMAN INTERVENTION IN FOREST ECOSYSTEM - A CASE STUDY OF LYME DISEASEOUTBREAK IN WAYANAD, KERALA

Muhammed Asif M.[1*] and Gayathri S. Lal[2]
[1]MVSc Scholar, College of Veterinary and Animal Sciences, Mannuthy
Kerala Veterinary and Animal Sciences University, Pookode, Wayanad, Kerala-673576
[2]Research Scholar, LPM Section, ICAR-NDRI, Karnal, Haryana-132001
asifmasifvet @gmail.com

The enhanced interaction between the wild animal ecosystem and humans has resulted in the ever-increasing development of re-emerging and emerging zoonotic

diseases. Some of the major reasons for the augmented emergence of zoonotic diseases include the increasing demand for animal protein, agricultural intensification unsustainably, increased poaching and trade of wildlife leading to the enhanced interaction with wild flora and fauna. Lyme disease, caused by the spirochete *Borrelia burgdorferi*, is a tick-borne disease, the global distribution of which corresponds to the distribution of *Ixodes* tick that transmits the organism. *Borrelia burgdorferi* is normally carried by mice, squirrels, birds and other small animals. Ticks become infected while feeding on the infected animal and thus transmit the disease to humans. Lyme disease is a multisystem inflammatory disorder with a wide spectrum of skin manifestations. In 2013, there was a Lyme disease outbreak reported inhuman settlements inside the Wayanad wild life sanctuary, Kerala. The disease took the life of a 50-year-old woman and four others are infected. It was suspected that the deer population contributed which is likely a factor in other areas as well.

SESSION - V

CONSERVATION BIOTECHNOLOGY & FORENSICS

CBF-LP 1

ROLE OF DNA FORENSICS IN FIGHT AGAINST WILDLIFE CRIME AND ILLEGAL TRADE IN INDIA

Dr. Ajay Gaur
Senior Principal Scientist (Conservation Genetics) & In-Charge (Wildlife Forensics)
Laboratory for the Conservation of Endangered Species (LaCONES)
CSIR-Centre for Cellular and Molecular Biology, Hyderabad
agaur@ccmb.res.in

The rich biodiversity of our country is seriously threatened and largely exploited through incessant poaching and illegal trade of endangered wild animals and their body parts. Although in India, we have the Wildlife Protection Act (1972) for protection of wild animals, compliance to this act is difficult to monitor. Therefore, wildlife forensics has emerged as a major tool in keeping a check over crimes related to wildlife. Today, wildlife forensics employs modern molecular genetics techniques to resolve wildlife crimes based on the fact that DNA is present in all life-forms from viruses to the biggest of the mammals. Further, DNA is species-specific, unique to an individual of a species, identical in all cells of an individual and related to its parents and siblings. Thus, DNA is the basis of modern wildlife forensics and has the power not only to establish the identity of a species but also to establish genetic relationships between individuals (Shivaji and Gaur, 2010). Wildlife forensics can bring awareness and speed up reporting of crime involving poaching, illegal hunting and trade, thereby, accelerating justice process and directly contributing to conservation of endangered Indian species.

The Centre for Cellular and Molecular Biology (CCMB), a pioneering CSIR institute in biological research, is playing a crucial role in DNA-based forensic investigation over the last two decades, providing scientific evidences for species identification, individual identification, tracing geographic origins of smuggled consignments, paternity and maternity determination, and sex assessment (Verma et al. 2003; Singh et al. 2004; Gupta et al. 2005; Gaur et al. 2006; Singh et al. 2012; Gaur et al. 2013; Modi et al. 2015).The “Universal Primer” technology developed and patented by CSIR-CCMB allows identification of a biological specimen of unknown origin and delineates its utility to the level of family, genus and species (Verma and Singh, 2003). In last two decades, CSIR-CCMB has received more than 2400 wildlife crime cases, which includes variety of biological samples such as meat, cooked meat, bones, faeces, skins, ivory, hair, nails, snake venom, blood stains, horns, antlers and even live individuals (e.g. Indian star tortoises). Biological specimens are received from all over the country confiscated and forwarded by state forest, judiciary, police and custom departments. This

effort has significantly helped in increasing awareness amongst forest departments, police departments and judiciary regarding the usefulness of this technique and also in inculcating a sense of fear amongst poachers.

CSIR-CCMB has published a SOP (Standard Operating Procedures) for generating knowledge and awareness about sample collection and preservation, DNA technology and its application in the field of Wildlife Forensics for accurate species and individual identification in crimes involving wild animals and their body parts (Gaur and Reddy, 2017).CSIR-CCMB also works towards generating awareness/creating skilled resources through regular lectures, in-house hands-on Skill Development Programs (SDPs) on trainings/workshops about the importance and use of molecular approaches towards wildlife conservation. Eight SDPs in Wildlife Forensics have been conducted biannually and attended by 80-90 forest officers, police officers, field &zoo biologists, veterinarians, university faculties and students.

1. Gaur A. and Reddy P. A. (2017). DNA techniques in wildlife forensics (Animals): Standard Operating Procedures (SOP). CSIR CCMB, Hyderabad, 37p, (e-portal.ccmb.res.in/lacones/docs/sop_072019.pdf).
2. Gaur A., Reddy A., Annapoorni S., Satyarebala B. and Shivaji S. (2005). The origin of Indian Star tortoises (*Geochelone elegans*) based on nuclear and mitochondrial DNA analysis: a story of rescue and repatriation. *Conservation Genetics*, 7: 231-240.
3. Gaur A., Singh C.S., Srinivas A. and Singh L. (2013). DNA-based identification of a snake in a wine bottle: A case of mistaken identity. *Forensic Science International* 214: e51 – 3.
4. Gupta S. K., Verma S. K. and Singh L. (2005). Molecular insight into a wildlife crime: the case of a peafowl slaughter. *Forensic Science International* 154: 214-217.
5. Modi N., Sreenivas A., Tabasum W. and Gaur A. (2016). DNA tools to establish species and individual identity of confiscated biological samples in wildlife related crime: A case report. *Journal of Forensic, Legal and Investigative Sciences* 2: 006.
6. Shivaji S. and Gaur A. (2010). Clues in the strands. *Biotech News* 5: 186 – 190.
7. Singh A., Gaur A., Shailaja K. and Singh L. (2004). A novel microsatellite (STR) marker for forensic identification in big cats in India. *Forensic Science International* 141: 143-147.
8. Singh C.S., Gaur A., Srinivas A. and Singh L. (2012). Species identification from dried snake venom confiscated from a hotel in Kerala: a case report. *Journal of Forensic Sciences* 57: 826-8.
9. Verma S. K. and Singh L. (2003). Novel universal primers establish identity of enormous number of animal species for forensic application. *Molecular Ecology Notes*, 3:28-31.
10. Verma S. K., Prasad K., Nagesh N., Sultana M. and Singh L. (2003). Was elusive carnivore a panther? DNA typing of feaces reveals the mystery. *Forensic Science International* 137: 16-20.

CBF-LP 2

ASSISTED REPRODUCTION IN WILD ANIMAL SPECIES

Pierre Comizzoli
Smithsonian Conservation Biology Institute, National Zoological Park, Washington DC
comizzolip@si.edu

Introduction - The role of reproductive sciences in wildlife conservation. Many of these wild animal populations are small and fragmented in their habitat with little or no genetic exchange which increases homozygosity and inbreeding that, in turn, leads to a bad adaptive capacity to environmental changes and fertility problems (Comizzoli *et al.* 2019). In addition to protecting species in their natural habitat (*in situ* conservation), it is critical to maintain viable populations in captivity (*ex situ*) for eventual reintroductions. However, reproduction fitness may be impaired in captivity by small space, health and husbandry problems, non-adapted diets, modified sexual behavior or infertility (Comizzoli *et al.* 2009). Therefore, conservation breeding can be optimized with assisted reproductive techniques (ART) to overcome the issues listed above. These approaches have been widely promoted over the past decades for enhancing breeding management and sustaining small populations of rare species (Holt *et al.* 2014; Comizzoli *et al.* 2019). Besides the techniques of artificial insemination (AI), embryo transfer (ET), and in vitro fertilization (IVF), a wide range of methods and tools have been developed (Brown 2018). These include non-invasive hormonal assessments for accumulating fundamental knowledge in diverse species (e.g., ovulatory mechanisms, seasonality, pregnancy, infertility) and manipulating the reproductive activities (e.g., super-ovulation, estrous synchronization). Among these critical tools, germplasm cryobiology also has played a key role to establish biorepositories for capturing extant genomic diversity (Comizzoli and Holt 2014). However, critical knowledge of reproductive traits is first needed before developing ARTs. Unfortunately, we know very little about species biology (reproduction in only 250 species has been properly described) with our efforts still remaining mainly concentrated on mammals and birds (Herrick 2019).

Even though this is not the aim of this article, it is also important to keep in mind that one of the biggest challenges facing zoos or some natural habitats is overly abundant populations. Zoo's genetic management programs dictate the breeding of the most valuable individuals, but also help to ensure that animals of unknown origin or those already well represented are not reproducing. Separate individuals into same-sexed groups is fraught with problems, especially severe aggression among adults housed together, thereby requiring significant additional space to place 'excess' individuals. As a result, there is an urgent need to develop safe and effective reproduction control measures relevant to the management of wildlife. This requirement extends beyond the zoo world

to wild habitats, where native landscapes are being destroyed by overabundant or invasive species (Garside *et al.* 2014).

The objective of the article is to review (1) existing reproductive biotechnologies to preserve the fertility of wild species populations and (2) emerging technologies associated with the need to change the paradigm that also are critical to solve conservation issues.

2. Recent advances in Assisted Reproductive Techniques for Wild Animal Species

2.1. Artificial insemination with fresh or frozen-thawed semen. For the past 20 years, major progresses in wildlife reproductive science have been made with the help of non-invasive endocrine monitoring (measuring fecal or urine steroid metabolites) to either (1) study reproductive traits such as ovarian cyclicity or seasonality of testicular activity (2) monitor pregnancies (3) assess the stress though cortisol level or (4) design the best protocols to enhance fertility or induce ovulation (Brown 2018). Prior to AI or ET in herbivores, for instance, ovulation may be induced (Thongphakdee *et al.* 2017). In felids, the induction of ovulation is possible with injections of eCG followed by hCG or LH administration (Brown 2018; Crosier *et al.* 2020). Unfortunately, as in domestic species, ovarian response is highly variable and the oocyte quality may be impaired by the exogenous hormones.

AI is currently the most extensively applied ART. Initial successes were achieved in bovids because of the significant development of ARTs in the cattle production. AI has been successfully applied to produce live offspring in non-domestic bovids and cervid species (Thongphakdee *et al.* 2017; Herrick 2019). However, AI is not integrated in the routine management of endangered ungulates yet. Too few zoos actually possess the facilities or expertise to permit animals to be safely handled for administration of exogenous hormones to control the ovarian activity. In wild carnivore conservation, the progress in AI is best illustrated by the basic research on ferret reproduction seasonality, semen cryopreservation methods, and laparoscopic AI (Howard *et al.* 2016). Many of the individuals produced by AI have subsequently reproduced and some of their offspring have been reintroduced into the wild.

2.2. Embryo transfer

2.3. ARTs in non-mammals – Example of amphibians

2.4. Germplasm cryopreservation and Genome Resource Banking efforts representing a direct example of how ARTs have tangibly contributed to a successful species recovery program. Since 1987, more than 8,000 black-footed ferrets have been produced and more than 3,000 of these have been released into prairie dog colonies across North America. The genetic management of giant panda population also is using AI as a really powerful tool with 25-50% of success after AI and the significant production of panda cubs derived from fresh or frozen-thawed semen (Comizzoli 2020). However, AI in other carnivore

species (mainly felids) is far from being routinely used and still has a really poor success rate (Tipkantha *et al*. 2017; Thongphakdee et al. 2020).

Early emphasis on embryo technologies in the 1980s as well as in the 1990s (Lasley *et al.* 1994) was then followed by a strong interest in somatic cloning and more recently in genomic approaches for "rescuing" or even resurrecting extinct species. However, major technical and ecological challenges remain for their application in conservation (Monfort 2014b). Thirty years after the first successful interspecies embryo transfer in a wildlife species, there is not a single example of genetic management based on that technique (Monfort, 2014). Successes related to the transfer of embryos produced by IVF also remain limited even though this technique (from the oocyte recovery through the IVF with fresh or frozen-thawed semen to the in vitro culture of embryos) is in theory the fastest and most efficient way to propagate small populations. For instance, significant but still anecdotal successes in IVF and ET have been recently reported in cheetahs (Crosier *et al.* 2020). But the technical complexity associated with the high procedural costs is limiting the development and implementation in conservation programs. In addition, the scarce knowledge on the kinetics of embryo development and foeto-maternal recognition also leads to many losses of pregnancies.

Amphibian unique reproductive patterns and mechanisms, key to species propagation, have only been explored in a limited number of laboratory models. The development of applied reproductive technologies for amphibians has been useful for a few threatened species only. These include non-invasive fecal and urinary hormone assays, hormone treatments for induced breeding or gamete collection, and artificial fertilization (Kouba *et al.* 2013; Clulow and Clulow 2016; Della Togna *et al.* 2018). The hormonal control of reproduction in amphibians has hardly been studied in comparison with fish and mammals. The use of injectable gonadotropin preparations, especially when coupled with egg and sperm collection for artificial fertilization is effective. Currently administered to a wide variety of anuran species are hCG and eCG, sometimes given in combination to maximally stimulate gonadal function. Regardless of the gonadotropin preparation chosen, much work remains to determine optimal species-specific injection protocols, given the large variations in responses to gonadotropins.

Genome resource banking (GRB) refers to the collection, processing, storage and use of germplasms (sperm, eggs, embryos, ovarian and testicular tissues) and other biomaterials (blood products, DNA samples) that can be used for understanding and sustaining biodiversity. If used properly in association with ARTs, GRBs have the potential to decelerate the loss of gene diversity in captive populations by reintroducing original genetic material (without removing genetically valuable individuals from the wild) and decrease the interval between generations

(Comizzoli and Holt 2014) The number of GRBs has grown over the past decades but the integration and significant roles into the management of captive populations are still limited. Fertility preservation strategies using cryopreservation have enormous potential for helping sustain and protect rare and endangered species. However, wide-scale applications currently are difficult because of the significant physiological variations among species and a sheer lack of fundamental knowledge in germplasm cryobiology. The best examples (mentioned above) can be found within the conservation programs of the giant pandas and black footed ferrets (Comizzoli and Holt 2014). Cryo-studies have been conducted in more species (mainly vertebrates) in the recent years but a vast majority still remains un-studied.

3. The Need for More Fertility Preservation Approaches

Even though the results are not satisfactory using classical ARTs, more fertility preservation options are necessary to save species. It also is worthwhile thinking beyond systematic characterizations and considering the application of cutting edge approaches to universally preserve the fertility of a vast array of species (Comizzoli and Wildt 2017). Regardless of the specific technology to be explored, new tools will require the significant use of 'models' (usually domestic animals) for comparable wildlife species. This need has been recognized and adhered to for three decades (Comizzoli and Holt 2019). It is essential to consider the practicality of initial testing and application, which will likely require exploration first in a taxonomically related 'model'. Even then, if a certain technique works efficiently in the model, it may require further modifications to be used effectively in the species of interest.

Genomics tools (next generation sequencing of the DNA) enable scientists to better understand the origins and patterns of biological functions. Biodiversity genomics will soon be yet another tool to add to the ART toolbox. However, without a parallel effort in reproductive science and ART development, bio-genomics applications will only continue to attract attention disproportionate to their potential for sustainably managing reproduction in endangered species. Whether it is the successful application of AI or the use of cloning to sustain an endangered living species or even 'resurrect' an extinct one, success will always depend on knowledge of a species biology, ecology, social structure, reproductive cycle, seasonality, embryo implantation, placentation, gestation, parturition, maternal behavior, neonatal care, nutrition, disease susceptibilities, and causes of endangerment. These important physiological traits are still poorly understood and monitored (like pregnancy for instance).

4. Filling the Gap between Technology and Animal Conservation

As already emphasized, success in producing new individuals with the help of ART requires, as a first step, a greater knowledge in the basic aspects of reproductive

biology and cryobiology. The complexity and diversity of reproduction in the animal kingdom was vastly underestimated, and we have certainly overestimated our ability to develop and apply ARTs that can be used to aid reproductive management and contribute to biodiversity conservation (Comizzoli and Holt 2014). As seen above, the barrier to the successful application of ARTs is not a shortage of new techniques, but rather a fundamental lack of "conservation capital"—trained scientists, sufficient numbers of research subjects, funding, and appropriate facilities designed specifically to study and manage nondomestic species. The zoo community has been too slow to recognize that current management paradigms are insufficient for sustaining hundreds of species across diverse taxa (Herrick 2019). Likewise, conservationists have often minimized the role of zoos and resisted biotechnology when their own efforts to stem the loss of biodiversity and wild places have fallen short. Reproductive technologists, zoo professionals, and conservation biologists all have the same goal - to save species and the ecosystems they require for survival. Success will require collective efforts to identify extant limitations and fundamental gaps in knowledge, both intellectual and practical, and joint efforts to secure long-overdue improvements.

Aligning technological capability with good animal management and sound conservation principles will make it increasingly possible to apply ARTs to increase reproductive efficiency; to readily transport gametes (sperm, eggs, embryos), raw DNA or genomes to overcome increasingly onerous international animal importation restrictions; to facilitate zoo-to-zoo animal exchanges (e.g., elephant AI already serves this purpose); and eventually to permit the routine exchange of genetic material between zoo and wild populations (Holt and Lloyd 2009). As Monfort (Monfort 2014a) clearly highlights: 'The justification for a return to building basic knowledge boils down to this: what is the ultimate value of using ARTs to produce endangered animals, or even resurrect extinct species, if we lack the capacity to manage and sustain these species in the first place? If we cannot now sustainably manage an oryx, Eld's deer or cheetah with or without ARTs, then what chance do we have of sustaining resurrected woolly mammoth, quagga or dodo in the future? Our strategy and focus must change or the true potential of ARTs for managing endangered species will never be fully realized'.

Conclusion

The application of reproductive biotechnologies for the preservation of endangered mammalian species is limited by several factors. Obtaining a healthy and genetically valuable offspring after AI or IVF/ET depends on the existing knowledge of the reproductive physiology of each particular species and little is known about the physiology of most wild animals. Captivity and poorly available biological material (often in disparate locations) also increase obstacles for research progress. The role and relevance of ARTs for contributing to species conservation is inextricably linked to whether or not zoos and conservation centers invest in developing an improved

understanding of overall species' biology, and reproduction, in particular. Reproductive biotechnologies combined with sound husbandry and management, appropriate facilities, and parallel efforts to sustain wild populations and places, offers the best chance for conservation success. Zoos and conservation centers must adopt such holistic conservation strategies or they risk becoming living museums exhibiting relic species that no longer exist in nature.

References :-

1. Brown JL (2018) Comparative ovarian function and reproductive monitoring of endangered mammals. *Theriogenology* **109**, 2–13. doi:10.1016/j.theriogenology.2017.12.004.
2. Clulow J, Clulow S (2016) Cryopreservation and other assisted reproductive technologies for the conservation of threatened amphibians and reptiles: bringing the ARTs up to speed. *Reproduction, Fertility and Development* **28**, 1116. doi:10.1071/RD15466.
3. Comizzoli P (2020) Birth of a Giant Panda Cub After Artificial Insemination with Frozen-Thawed Semen: A Powerful Reminder About the Key Role of Biopreservation and Biobanking for Wildlife Conservation. *Biopreservation and biobanking* **18**,. doi:10.1089/bio.2020.29076.pjc.
4. Comizzoli P, Brown JL, Holt W V. (2019) Reproductive science as an essential component of conservation biology: New edition. 'Adv. Exp. Med. Biol.' pp. 1–10. (Springer New York LLC) doi:10.1007/978-3-030-23633-5_1.
5. Comizzoli P, Crosier AEAE, Songsasen N, Gunther MSS, Howard JJGG, Wildt DEDE (2009) Advances in reproductive science for wild carnivore conservation. *Reproduction in Domestic Animals* **44**, 47–52. doi:10.1111/j.1439-0531.2009.01373.x.
6. Comizzoli P, Holt WVW V (2014) Recent advances and prospects in germplasm preservation of rare and endangered species. *Advances in experimental medicine and biology* **753**, 331–56. doi:10.1007/978-1-4939-0820-2_14.
7. Comizzoli P, Holt W V (2019) Breakthroughs and new horizons in reproductive biology of rare and endangered animal species. *Biology of Reproduction*. doi:10.1093/biolre/ioz031.
8. Comizzoli P, Wildt DE (2017) 'Cryobanking biomaterials from wild animal species to conserve genes and biodiversity: Relevance to human biobanking and biomedical research.' doi:10.1007/978-3-319-55120-3_13.
9. Crosier AE, Lamy J, Bapodra P, Rapp S, Maly M, Junge R, Haefele H, Ahistus J, Santiestevan J, Comizzoli P (2020) First birth of cheetah cubs from in vitro fertilization and embryo transfer. *Animals* **10**,. doi:10.3390/ani10101811.
10. Garside D, Gebril A, Alsaadi M, Ferro VA (2014) Fertility Control in Wildlife: Review of Current Status, Including Novel and Future Technologies. pp. 467–488. (Springer, New York, NY) doi:10.1007/978-1-4939-0820-2_18.
11. Herrick JR (2019) Assisted reproductive technologies for endangered species conservation: developing sophisticated protocols with limited access to animals with unique reproductive mechanisms. *Biology of Reproduction*. doi:10.1093/biolre/ioz025.

12. Holt WV, Brown JL, Comizzoli P (2014) 'Reproductive science as an essential component of conservation biology.' doi:10.1007/978-1-4939-820-2_1.
13. Howard JG, Lynch C, Santymire RM, Marinari PE, Wildt DE (2016) Recovery of gene diversity using long-term cryopreserved spermatozoa and artificial insemination in the endangered black-footed ferret. *Animal Conservation* **19**, 102–111. doi:10.1111/acv.12229.
14. Kouba AJ, Lloyd RE, Houck ML, Silla AJ, Calatayud N, Trudeau VL, Clulow J, Molinia F, Langhorne C, Vance C, Arregui L, Germano J, Lermen D, Della Togna G (2013) Emerging trends for biobanking amphibian genetic resources: The hope, reality and challenges for the next decade. *Biological Conservation* **164**, 10–21. doi:10.1016/j.biocon.2013.03.010.
15. Lasley BL, Loskutoff NM, Anderson GB (1994) The limitation of conventional breeding programs and the need and promise of assisted reproduction in nondomestic species. *Theriogenology* **41**, 119–132. doi:10.1016/S0093-691X(05)80057-3.
16. Monfort SL (2014a) 'Mayday Mayday Mayday', the Millennium Ark Is Sinking! 'Adv. Exp. Med. Biol.' pp. 15–31 doi:10.1007/978-1-4939-0820-2_2.
17. Monfort SL (2014b) 'Reproductive Sciences in Animal Conservation.' (W V. Holt, JL Brown, and P Comizzoli, Eds.). (Springer New York: New York, NY) doi:10.1007/978-1-4939-0820-2.
18. Thongphakdee A, Berg DK, Tharasanit T, Thongtip N, Tipkantha W, Punkong C, Tongthainan D, Noimoon S, Maikeaw U, Kajornklin N, Siriaroonrat B, Comizzoli P, Kamolnorranath S (2017) The impact of ovarian stimulation protocol on oocyte quality, subsequent in vitro embryo development, and pregnancy after transfer to recipients in Eld's deer (Rucervus eldii thamin). *Theriogenology* **91**,. doi:10.1016/j.theriogenology.2016.12.021.
19. Thongphakdee A, Sukparangsi W, Comizzoli P, Chatdarong K (2020) Reproductive biology and biotechnologies in wild felids. *Theriogenology* **150**, 360–373. doi:10.1016/j.theriogenology.2020.02.004.
20. Tipkantha W, Thuwanut P, Maikeaw U, Thongphakdee A, Yapila S, Kamolnorranath S, Siriaroonrat B, Comizzoli P, Chatdarong K (2017) Successful laparoscopic oviductal artificial insemination in the clouded leopard (*Neofelis nebulosa*) in Thailand. *Journal of Zoo and Wildlife Medicine* **48**,. doi:10.1638/2016-0287.1.
21. Della Togna G, Gratwicke B, Evans M, Augustine L, Chia H, Bronikowski E, Murphy JB, Comizzoli P (2018) Influence of extracellular environment on the motility and structural properties of spermatozoa collected from hormonally stimulated Panamanian Golden Frog (Atelopus zeteki). *Theriogenology* **108**,. doi:10.1016/j.theriogenology.2017.11.032.

Abstracts

CBF 1

HOST-PARASITE INTERACTION WITH REFERENCE TO SEASON IN NILGIRI TAHR (*Nilgiritragus hylocrius*) IN WESTERN GHATS

Biju S.
Assistant Professor, College of Veterinary and Animal Sciences, Kerala Veterinary and Animal Sciences University, Mannuthy, Thrissur, Kerala -680651
drbijuyes@gmail.com

Nilgiri tahr (*Nilgiritragus hylocrius*) is anungulate endemic to the tropical mountains, and is distributed in the Western Ghats, and the species is listed in the endangered category. The inter-specific relations of a species are important in the long term sustenance of a species, and the study wason the parasite interaction in tahr across different seasons in its habitat. The overall incidence of parasites observed in the study was 38.9 per cent, and both mixed and single type infections were observed. The incidence of strongyle in the study was 34.3 per cent followed by coccidia (15.5 %)and the incidence of other parasites like *Moniezia*, *Trichuris*, *Capillaria* and *Strongyloides* were low. There was significant difference in parasitic incidence between seasons, with higher share in monsoon (58.9%) followed by summer (40%) and post-monsoon (17.8%). Eggs per gram of parasites in the faecal pellets also observed significant seasonal difference with higher count in monsoon (360.64±39.36) followed by post-monsoon (232.81±61.35) and summer (114.29±23.83). The degree of infection was assessed to be mild as the eggs per gram were below 1000 in all samples. There observed significant difference in the faecal cortisol metabolite level between parasite infected (488.411±36.48ng/g) and non-infected (393.242±22.57 ng/g) animals, that indicated the stress due to parasitism. But the body condition scores ranged from 3.0 to 5.0 which indicated that the herds were healthy across all seasons. The study identified the significant presence of parasites in Nilgiri tahr population and indicated the equilibrium of host-parasite relationship as influenced by the climate.

CBF 2

COMPARATIVE GROSS MORPHOMETRICAL STUDY ON APPENDICULAR SKELETON OF MALE AND FEMALE LION *(Panthera leo)*

Jyoti Saini, P. L. Dhande, V. D. Shankapal and S. A. Gaikwad
Mumbai Veterinary College, Parel, Mumbai
dr.vds@rediffmail.com

The comparative morphometrical studies of appendicular skeleton were conducted on two lions (one male and one female). The general plan and arrangement of

appendicular skeleton of lion resembled to that of leopard and tiger. The femur was the heaviest and longest bone in male (417 g and 35 cm) and female (345 g and 32.5cm) respectively. Single digit of hind limb (1338.43 g) was slightly heavier than the corresponding digit of hind limb (1031.30 g) in both males and females. All the bones in male were longer and heavier than female. The current study showed that the osteology of the lion were similar to those of other mammals. The information is important for taxonomic affiliation and wildlife forensic as well as to help the zoo veterinarians to manage clinical bone diseases in this species.

CBF 3

ASSISTED REPRODUCTIVE TECHNOLOGY IN WILDLIFE

Megha. B. Ambalkar and Chaitanya H. Pawshe
Department of Animal Reproduction, Gynaecology and Obstetrics
Post Graduate Institute of Veterinary and Animal Sciences, Akola
(Maharashtra Animal & Fishery Sciences University, Nagpur)
ambalkarmegha10@gmail.cpm

In wildlife, extinction currently is occurring at a much higher rate than speciation because of detrimental human activities, such as habitat destruction, overhunting/fishing, and poaching. Animal conservation aims at understanding and sustaining biodiversity because the disappearance of even a single species can compromise the functioning of entire ecosystems. The International Union for Conservation of Nature (IUCN) estimates that 25% of mammals, 12% of birds, 20% of reptiles, 30% of amphibians, 20% of fishes, 30% of invertebrates, and 55% of plant species are threatened with extinction. Therefore, conservation breeding can be optimized with assisted reproductive techniques (ART) to overcome the issues. *These approaches have been widely promoted over the past decades for enhancing breeding management and sustaining small populations of rare species. Besides the techniques of artificial insemination (AI), embryo transfer (ET), and in vitro fertilization (IVF), a wide range of methods and tools have been developed. In* past 20year major progresses in wildlife reproductive science have been made with the help of non-invasive endocrine monitoring to either 1) study reproductive traits such as ovarian cyclicity or seasonality of testicular activity, 2) monitor pregnancies, 3) assess the stress though cortisol level, or 4) design the best protocols to enhance fertility or induce ovulation. *For the future generation, conservation of rare wild species is important otherwise these species are kept as a clay model or pictures in the museum. Assisted Reproductive Technology is very important for the conservation of germplasm of endangered species for balancing of ecosystem.*

CBF 4

TUBERCULOSIS: AN UNDERLYING THREAT TO THE WILDLIFE HEALTH

Nidhi Rajput[1], Nitin Gupta[2], Himanshu R. Joshi[3] and Amol Rokde[1]
[1]School of Wildlife Forensic and Health, Nanaji Deshmukh Veterinary Science University, Jabalpur, Madhya Pradesh
[2]Bandhavgarh tiger reserve, Umaria, Madhya Pradesh
[3]Wildlife Conservation Trust, Mumbai
nidhi3rajput@gmail.com

Tuberculosis has been reported in a number of wild animals both in captive and free range. In free-range wild animals, biological sampling is practically difficult as it requires restraining and often chemical immobilization. Even so, tuberculosis surveillance programs in wild animal population can effectively be conducted by screening the scientifically collected-preserved faecal samples. Modifications and amendments to validate the laboratory techniques for the diagnosis of tuberculosis in susceptible wild animal species are being practiced by various researchers. At School of Wildlife Forensic and Health, screening of tuberculosis is being carrying out in the susceptible species of wild animals such as big cats, sloth bears, elephants, Indian bison, deer species and non-human primates. This includes biological sampling from both the live animals opportunistically as well as from the carcasses as and when observed. There is an array of assay for the diagnosis of tuberculosis in the biological samples such as traditional acid-fast staining, immunoassays and also DNA based detection assays. In the current screening program, samples are being screened mainly through traditional technique as well as PCR based detection using the IS6110 insertion sequence of *Mycobacterium tuberculosis* complex. Large scale surveillance is always required with an ultimate aim to manage the health of affected as well as susceptible wild animal species. Hence, diagnostics and surveillance should be considered the key to benefit the development of long-term approaches to the management of tuberculosis in an ecosystem inclusive of human population.

CBF 5

MOLECULAR DETECTION OF *Panthera pardus* AND *Panthera tigris* USING NON-INVASIVE SCAT SAMPLES

Pooja Acharya[1], Prabhakar Tembhurne[*1,3], V M. Dhoot[3] G R. Bhojane[3], Vijay Ingle[1], S.W. Bonde[4], Dr. M.S.Patil[3], Ajay Gawande[3], S.V.Upadhye[3], Nandkishor Kale[5], N. Rambabu[6], A S Bannalikar[1,3]

[1] Department of Veterinary Microbiology and Animal Biotechnology, Nagpur Veterinary College, Nagpur-44006, India ; [4]Department of Biochemistry, Nagpur Veterinary College, Nagpur-44006, Maharashtra, India; [3]Wildlife Research and Training Centre (WRTC), Gorewada, Nagpur-440013;[5]Divisional Manager, Gorewada Project, Wildlife Rescue Centre, Gorewada, Nagpur-440013, India ;[6]Managing Director, Forest Development Corporation of Maharashtra, Limited, Nagpur-440036, India

prabhakar.tembhurne@gmail.com

In India, Vidhrabha region is highly blessed with forest and wildlife consisting of tiger reserve as well as sanctuaries where Human Wildlife Conflict has been reported. In the area of wildlife forensics and wildlife monitoring, powerful molecular method for detecting the origin and identification of endangered species is required. The sample availability or collection is always remains the trickiest part in wildlife investigation. The scat samples can be easily obtained even the confiscated scat samples that can be explored for such investigations. In the present investigation, analysis of the scat samples with multiplex PCR using mitochondrial cytochrome b gene specific primer have been carried out and representative amplicons were further confirmed using sequencing and its phylogenetic analysis. The 24 scat samples including three confiscated scat samples from Wildlife Research and Training Centre (WRTC), Gorewada, Nagpur, India have been analyzed. Amongst 24 scat samples tested, 19 samples revealed as expected *Panthera pardus* specific 156 bp and one sample showed a *Panthera tigris* specific amplicons of 271bp. Further sequencing confirms the species identification and phylogenetic analysis shows cladding with specific species groups. The present study confirms the utility of scat samples for accurate species identification in wildlife and forensic research.

CBF 6

DEVELOPING A MOLECULAR SEXING TECHNIQUE FOR CAVE-DWELLING SWIFTLETS (FAMILY: APODIDAE)

Sanjeev Kumar Sharma, Prathamesh Gurjarpadhye, Shirish S. Manchi, Ram PratapSingh
Sanjeev Kumar Sharma, Sàlim Ali Centre for Ornithology and Natural History, Anaikatty (Post), Coimbatore – 641108, Tamil Nadu, India.
Prathamesh Gurjarpadhye, Sàlim Ali Centre for Ornithology and Natural History, Anaikatty (Post), Coimbatore – 641108, Tamil Nadu, India.
Manchi Shirish S, Sàlim Ali Centre for Ornithology and Natural History, Anaikatty (Post), Coimbatore – 641108, Tamil Nadu, India.
Ram Pratap Singh, Central University of South Bihar, Gaya, Bihar, India.
sksbreeder@gmail.com

Sex identification is essential for the effective management and conservation of birds. In monomorphic bird species, the male and female birds cannot be identified based on phenotypic traits. Therefore, molecular techniques were used for reliable sex differentiation. The polymerase chain reaction (PCR) based methods have been widely used in molecular sexing of birds, using sex-linked markers. In the present study, initially, we used existing methods for sex identification in the monomorphic Edible-nest Swiftlet (ENS) (*Aerodramus fuciphagus inexpectatus)* & Plume-toed Swiftlet (PTS) (*Collocalia affinis)*. We followed three different protocols; primer pairs 2550F/2718R, P8/P2, and multiplexing of 2550F/2718R and P8/P2 sets of primers in a single reaction for sex identification.

CHD1 gene of ENS and PTS were successfully amplified using 2550F/2718R primer pair with ENS female samples, but it could not be amplified with male samples. CHD1 gene was successfully amplified using P8/P2 primer pair with males and female ENS samples and yielded single-band using agarose gel electrophoresis. This PCR product was subjected to expensive and prolonged PAGE analysis, which yielded double band for the female and a single band for the male ENS sample. As to overcome from PAGE limitations, we invented multiplexing PCR method using the primer pair 2550F/2718R and P8/P2. We observed two bands for females and a single-band for males after running the multiplex PCR product on 2% agarose gel, which identified males and females. This newly developed, simple, cost-effective, less time-consuming, high-throughput applicability of bird sex identification technique has implications for understanding the population dynamics of birds.

CBF 7

DETECTION OF MYCOBACTERIUM TUBERCULOSIS IN A CAPTIVE SLOTH BEAR BY MOLECULAR ANALYSIS

Sidharth Shaji[1], GS Ajithkumar [2], S Nandakumar [3], Jacob Alexander [4], Baby Joseph [5]
1. BVSc&AH scholar, Mumbai Veterinary College 2. Veterinary Surgeon, Division of Biotechnology & Centre for Wildlife Sciences, SIAD, Govt. of Kerala.3. Disease Investigation Officer, Centre for Wildlife Sciences, SIAD, Govt. of Kerala.
4. Assistant Director, Zoological Gardens, Thiruvanathapuram, Kerala
5. Chief Disease Investigation Officer, SIAD, Govt. of Kerala.
(Authors 1&2 are equally contributing authors)
jacobalexander2000@gmail.com

Tuberculosis is an infectious disease with significant mortality in captivity as well as wildlife. The disease is often caused by Mycobacterium tuberculosis or bovis or avium. Post mortem examination of the debilitated and emaciated 10 year old female sloth bear at Thiruvananthapuram zoo, Kerala revealed whitish caseated nodules in the lungs. Histopathological examination of the lung was suggestive of tuberculosis. PCR analysis was done at State Institute for Animal Diseases, Kerala for both Mycobacterium tuberculosis and bovis. Results revealed the presence of Mycobacterium tuberculosis only. DNA sequencing of the 389 base pair region of the obtained PCR product also supported the PCR result of the presence of Mycobacterium tuberculosis. There were previous reports of incidences of tuberculosis in sloth bear from India such as from Maharaj Bag Zoo, Nagpur (Hedau, M and Kambdi, BP, 2016), Kamala Nehru Zoological Garden, Ahmedabad (Fefar, DT *et al*, 2012) and from Thiruvananthapuram zoo, Kerala itself (Unpublished data). But none of the research articles have presented any conclusive evidence for the presence of Mycobacterium tuberculosis ruling out the Mycobacterium bovis species. In this case study, we have used the PCR analysis and followed by sequencing of the PCR product to confirm the presence of Mycobacterium tuberculosis in a sloth bear ruling out the Mycobacterium bovis. This study also points out for a detailed investigation for human to animal or animal to human transmission of the disease that has a serious zoonotic implication.

CBF 8

PATHOLOGY OF LEPTOSPIROSIS IN WHITE TIGER

K. Sujatha*, Dr. D. Raniprameela, Dr. Arun, Ch. Srilatha and A. Nasreen,
Department of Veterinary Pathology, College of Veterinary Science,
Sri Venkateshwara Veterinary University, Tirupati – 517502
karamalasujatha@gmail.com

Leptospirosis is a zoonotic contagious bacterial disease of animals affecting both humans and animals including wild animals. One and half years old white tiger was died

in Sri Venkateshwara zoo park, Tirupati and conducted postmortem examination. Clinically, for eight days completely off feed and not responding to treatment. On external examination of carcass revealed slight yellowish discoloration of oral mucosa and conjunctival mucosa. Petechiae to ecchymotic hemorrhages were noticed on oral mucosa. On internal examination subcutaneous tissue showed light yellow colour. Liver was enlarged with rounded boarders with multiple pale areas with hyperemic boarders were noticed on the surface. Kidneys were enlarged and bulged out in appearance and removal of capsule was easy and smooth cortex. On section of kidney revealed dilated renal pelvis and atrophied and necrosis of renal calyx's and renal pyramids and loss of some amount of cortex was noticed. Lung shows congestion and areas of collapse and emphysema. The stomach mucosa was congested and contained few erosions. Representative tissue samples were collected in 10% formalin for HP examination and urine sample for dark field examination. Histopathologically, liver revealed necrotic areas with infiltration of mononuclear cells and individualization of hepatocytes. Kidney shows severe degenerative changes in renal tubules with desquamative changes and interstitial nephritis. Dark field examination of urine sample revealed leptospiral organisms. Based on the gross and histopathological findings and dark field examination the present case was diagnosed as leptospirosis in a white tiger.

CBF 9

MOLECULAR AND MORPHOMETRIC APPROACHES FOR IDENTIFICATION OF *Canis* TAXA IN INDIA: CONSERVATION AND FORENSIC PERCEPTIVE

Yellapu Srinivas & Yadvendradev Jhala
Wildlife Institute of India, Dehradun, India
sriramadncs@gmail.com

Reliable identification of elusive, rare and sympatric carnivores using non-invasive samples at the species level is crucial in wildlife management, conservation biology and forensic science. Non-invasive samples including hair, feces, saliva, urine, scent marks and illegally trafficked animal parts (skins, bones, and skulls) have proved to be efficient in studying sympatric carnivores without even the need to capture the animals. India is home to four genus *Canis species*: Indian wolf, Himalayan wolf, Jackal, and domestic dog. In most of their distribution ranges, *Canis* species are sympatric and an approach for accurate identification to species level is crucial for further studies.I compared morphological (hair, cranial, and external characters) and molecular approaches (mtDNA, y-chromosomal, and nuclear microsatellites) for identification of

Indian *Canis* species and tested the efficiency of these methods in accurate identification of species for its use in conservation and forensic use. Medulla and cuticular patterns of guard hairs failed to distinguish among the *Canis* species with only difference observed in medullary thickness. Analysis using cranial and external characteristics clearly separated jackal from other wild wolves but no significant difference observed between the wolves. Variations were mostly observed in molecular data of *Canis* species making the approach to be most useful one in differentiating the species. This study provides the most exhaustive description of morphological and molecular variables between *Canis* species which can be used to identify the unknown samples belonging to *Canis* species to accurate species level and contributes to existing data on Indian *Canis* species.

CBF 10

Tachygonetria robusta (PINWORM) INFESTATION CAUSING INTESTINAL IMPACTION IN AN INDIAN STAR TORTOISE (*Geochelone elegans*)

C Purnima[1], Aparna Sandeep[2] and Jacob Alexander[3]*

[1] Senior Research Fellow, ICMR, Division of Experimental Pathology, Biomedical Technology Wing, Sree Chitra Tirunal Institute for Medical Sciences and Technology, Thiruvananthapuram 695012, India.[2]Masters Scholar, Royal Melbourne institute of technology, Victoria, Australia 3000[3] Senior Veterinary Surgeon, Zoo Veterinary Hospital, Zoological Garden, Thiruvananthapuram-695033, India.

zoovettvm@gmail.com

A four-year-old male Indian star tortoise reared in colony in a terrarium was undergone detailed postmortem investigation following death. Copious amount of frothy nasal discharge and bumpy carapace were noticed on external examination. Moderate gastro-enteritis, severe impaction of large intestine, moderately distended urinary bladder with abundant greenish deposits, moderate pulmonary edema and congestion were the major gross lesions. Detailed examination of the impacted large intestine revealed about 50-100 white nematodes with approximately 0.5 mm in length. On microscopical examination, female worms had wide head attached to the thick, stout body through distinct transverse folds, when compared to males with thin body. Oesophagus was short in females with pyriform bulb, while narrow in males. Males had short needle shaped spicule. Based on the characters observed, worms were identified as *Tachygonetria robusta*, commonly called as pinworms. Histopathological evaluation revealed chronic enteritis with severe infiltration of mononuclear inflammatory cells, mild to moderate gastritis and severe chronic pneumonia. The cause of death was attributed to nematodiasis. A course of fenbendazole was given to all testudines in the colony. Even though pinworms are common in tortoises, reduction in gastric motility along with severe worm infestation leading to impaction can cause mortality.

CBF 11

SAMPLES AND SAMPLING- A KEY TO DIAGNOSIS OF ELEPHANT ENDOTHELIOTROPIC HERPES VIRUS (EEHV) INFECTION

GS Ajithkumar[1], S Nandakumar[2], CS Jayakumar[3], PR Prathiush[4]
[1] Veterinary Surgeon, Division of Biotechnology & Centre for Wildlife Sciences, SIAD, Govt. of Kerala.
[2] Disease Investigation Officer, Centre for Wildlife Sciences, SIAD, Govt. of Kerala.
[3] Assistant Director, Department of Animal Husbandry, Govt. of Kerala.
[4] Veterinary Surgeon, Centre for Wildlife Sciences, SIAD, Govt. of Kerala.
ajithnairgs@gmail.com.

EEHV infection in elephants is a serious health concern for elephants since the case fatality rate is too high in young animals. Adult elephants often act as asymptomatic carriers and enhance the transmission and spread within and between herds. It has significant implications on the future population of elephants. EEHV-1, EEHV-3/4 & EEHV-5 are the major types that affects Asian elephants. Out of the total number of 290 samples received at SIAD, tissue samples (post-mortem samples) were found to be more ideal for confirming EEHV infection followed by trunk wash and blood by real time PCR analysis. All positive samples were sequenced and analysed. 95 samples were received from a total of 30 elephants (both captive and wild) and among them 17 were found positive for EEHV-1 and 13 are negative for the same. This figure is alarmingly high (56.6%) when compared to other diseases in elephants. Trunk washes and blood samples were collected from the elephant camps in the state as part of the annual disease screening programs. Blood samples are found to be positive only in two instances and reliable only at the peak of viraemia.

Type of samples tested for EEHV by real time PCR analysis: Total samples: 290 [Tissue: 108 ; Trunk Wash: 68 ; Blood: 114]. Samples PCR positive and negative respectively: Tissue: 65 & 43; Trunk Wash: 68 & 4; Blood: 2 & 112. So the trunk washes are most reliable for screening of the disease. Proper sampling of the trunk washes is the critical factor for diagnosis in live animals, which delineate false negative results.

CBF 12

VETERINARY FORENSIC IMAGING – APPLICATION OF CT IMAGING IN DETECTION OF CHIP AND ITS SURGICAL RETRIEVAL IN A FALCON (*Falco berigora*)

Sakar Palecha[2,3], P. Bishnoi[1], Satyaveer Singh[2], Mahendra Tanwar[2] , Himanshu Vyas[4], Narendra Singh[4]
1-Associate Professor; 2- Assistant Professor; 3- Principal Investigator; 4- PG Scholars
Centre for Studies on Wildlife Management and Health
Department of Veterinary Surgery and Radiology, CVAS, Bikaner
Rajasthan University of Veterinary and Animal Sciences, Bikaner, Rajasthan, INDIA
sakar.palecha@gmail.com

A Falcon (*Falco berigora*) captured by BSF from the international border area was brought by Bikaner Zoo officials suspecting a chip inside the body of the falcon. On official request, a survey radiograph was taken which revealed presence of a cylindrical radiopaque metallic foreign body embedded in the pectoral muscles. After proper permission from the Department of Forest and Wildlife, CT scan was performed under general anaesthesia with ketamine (30 mg/kg) to confirm the shape, size and location of the metallic foreign body. Multiplanar CT images were taken which revealed the presence of a cylindrical foreign body of size 11 mm length and 0.8 mm diameter. Immediately after CT examination, the metallic foreign body was surgically retrieved. The foreign body was identified as chip like thing encapsulated in a cylindrical glass which was handed over to the Zoo and BSF officials for further forensic investigations. The wound was sutured and postoperative antibiotics and analgesics were administered for 3 days. The falcon recovered uneventfully.

CBF 13

FORENSIC INVESTIGAION OF AN ELEPHANT DIED DUE TO ELECTROCUTION

Manjunatha, S.S., Jayaramu, G.M. Kavitha Rani, B. and Vinay, S.
Department of Veterinary Pathology,
Veterinary College, Shivamogga
Karnataka Veterinary Animal and Fisheries Sciences University (KVAFSU),
Karnataka, India-577204
drssmanjunatha@gmail.com

A Postmortem investigation of Wild Asian elephant approximately aged around 26 years died due to electrocution in a Mudigere forest range, Chikkamaglur district, Karnataka, India was carried out. The elephant was subjected to detailed necropsy and

external examination revealed lateral recumbency of the animal with dilated pupil, congestive changes in conjunctival and oral mucous membranes, prolapsed of penis and rectal discharge staining surrounding area. In the trunk region burnt wound was noticed with charred appearance of the skin along with the musculature and singing of hairs around the burnt area. There was extensive distension of the abdomen and effusion of serous fluid from the abdominal cavity with ballooned loops of small intestines was noticed. The liver and spleen indicated congestive changes. Serosal surface of stomach and intestine revealed congestive changes. Mesenteric vessels were congested. Hemothorax was noticed. Linear and petechial hemorrhages were noticed on the tracheal mucous membrane. Severe congestive, edematous and hemorrhagic lesions were noticed in lungs. Cardiomegaly and epicardial hemorrhages were also observed. The cause of death in the elephant was attributed to cardiac and respiratory failure because of electrocution based on Post Mortem findings and circumstantial evidences.

CBF 14

A CASE OF EHRLICHIOSIS IN NILGAI

P. M. Sonkusale, N. V. Kurkure and P.A. Tembhurne
Department of Veterinary Pathology
Nagpur Veterinary College, MAFSU, Nagpur
Nagpur-440 006 (M. S.)
drprashantvet@yahoo.com

Ehrlichia bovis is a leukocytophilic rickettsial organism of domestic and wild animals which is transmitted by ticks and multiply within cytoplasm of circulating monocytes and tissue macrophages. The infection is characterized by fever, generalized enlargement of lymphnodes, depression, loss of body condition and some other aberrant clinical signs. A wild Nilgai died naturally within the circle of Ramge Forest office, Mrug Vihar, Nagpur (Maharashtra) with the history of persistent fever, anorexia and heavy tick infestation. Post-mortem examination was carried out in the department of Pathology, Nagpur veterinary college, Nagpur. PM examination revealed nasal discharge, conjunctivitis, enlargement of peripheral lymphnodes with splenomegaly. In addition to haemorrhagic enteritis, liver, heart and lungs were found congested. The blood smear examination revealed presence of Ehrlichia in the cytoplasm of most of the monocytes.

CBF 15

AN INCIDENTAL CASE OF ANTHRACOSIS IN MONKEY

Pratik N. Ingle Patil, P. M. Sonkusale, N. V. Kurkure and P.A. Tembhurne
Department of Veterinary Pathology
Nagpur Veterinary College, MAFSU, Nagpur
Nagpur-440 006 (M. S.)
drprashantvet@yahoo.com

Anthracosis is a condition in which carbon or coal particles are accumulated in lungs. Lungs and associated lymph nodes preserve the inhaled particles which also get lodged in connective tissue in inter alveolar septa, mononuclear phagocytes and epithelial tissue found freely suspended in bronchioles and alveoli. People working in coal mines as well as animals, particularly dogs, horses and mules reared in the vicinity are considered to be at high risk for anthracosis. Reports on the occurrence of anthracosis in a variety of domestic animals are available, while in captivity or free range wild animals are sparse. A dead male rhesus monkey was brought to the Department of Pathology by Gorewada Rescue Center, Nagpur with history of clinical symptoms of anorexia, respiratory distress, prostration and debility before death. The carcass was debilitated. Post mortem examination revealed congestion and widespread black pigmented areas over the surfaces of both lobes of lungs. Histopathological examination revealed deposition of black pigmented carbon particles around the blood vessels, bronchi, bronchioles and in the alveoli. Congestion in the blood vessels, haemorrhages and degenerative changes in alveolar epithelium were also evident. Cytoplasm of macrophages were filled with black pigmented coal particle and showed degenerative and necrotic changes. Bronchopneumonia characterized by hemorrhages, necrosis and infiltration of inflammatory cells along with presence of black pigmented granules in alveoli and bronchi was also noticed. Reports in the monkey are rare; hence present study describes incidental case of anthracosis in monkey from central India.

CBF 16

CONSERVATION OF WILD LIFE SPECIMENS: A CASE STUDY

Leena Zilpe Haate
CEO Heritage Conservation Services
heritageconservationservice@gmail.com

During colonial time in India, hunting of wild animals was a popular sport among the rulers . With the establishment of Van Ingen and Van Ingen firm under the patronage of Mysore Maharaja, stuffing and making trophy of hunted animals skin was on the boom. These wild life specimens are now found in various museums, government offices

and private owners. Such specimens are largely available with the Forest Department, Government of Maharashtra. The Office of Deputy Conservator of Forest, Nagpur Division took initiative in conserving their wild life specimens and conservation work on Tiger and Bison is carrying out by our Heritage Conservation Society. This paper presents a detailed conservation processes on treating Bison as a case study. Heritage Conservation is now established as a profession on a global level based on the standard conservation practices and methodology which involves steps as ; documentation , examination, diagnostic analysis and testing , planning conservation strategy and lastly intervention. Accordingly, Bison (mounted head) was first fumigated enclosing in polythene for 15 days and then examined visually, microscopically as well as digitally photographed from various angles highlighting conservation problems. After thorough documentation, Bison head, heavily ingrained with dust , dirt was cleaned mechanically and using poultices . Jute bags , soils , wood dust used for stuffing were removed and finally, it was then dismounted from the mount. Bison head skin was then cleaned from inside and then treated with British Leather formula. Simultaneously, a dummy of bison head was casted for mounting. The conservation treatment we carried out is durable, long lasting and preserve Bison head for another century if it is kept under specified environmental conditions .

CBF 17

COMPARATIVE GROSS ANATOMICAL STUDIES ON THE MANDIBLE OF BENGAL TIGER (*Panthera tigris tigris*) AND COMMON LEOPARD (*Panthera pardus*)

Abhin Raj, K.P., Sreeranjini, A.R., Maya, S., Sunilkumar, N.S., Lucy, K.M., Leena Chandrasekhar and Sumena, K.B.
Department of Veterinary Anatomy and Histology,
College of Veterinary and Animal Sciences, Mannuthy, Thrissur- 680 651, Kerala.
abhinrajtsy@gmail.com

The study was conducted on the mandible of Bengal tiger (*Panthera tigris tigris*) and Common leopard (*Panthera pardus*). In both species, mandible was the largest bone of the skull and comprised two symmetrical halves, which firmly united at the mandibular symphysis. Each half furnished a body with incisive and molar parts, and a ramus. On each side of ramus there were three alveoli for incisor teeth and one for very large canine tooth. The molar part of body was thick and presented an upper alveolar border with three alveoli for lower cheek teeth. At the junction of incisive and molar parts of body on each side, the lateral surface presented three mental foramina in tiger whereas two in leopard. Compared to leopard masseteric fossa on lateral surface of ramus was

extensive and deep in tiger. Medial surface of the ramus was flat and rough and showed the single large mandibular foramen near its ventral border in both species. The ramus furnished coronoid and condylar processes and angular process. The present study indicated that the anatomical features of mandible were adapted to carnivorous feeding habits with powerful bites and helpful in forensic examinations for veterolegal cases.

CBF 18

DETECTION OF *Mycobaterium Tuberculosis* USING REAL TIME NESTED PCR IN A SAMBAR DEER (*Rusa unicolor*)

Valsarajan Dipika[1*], Powar Komal[1], Tripathi Sanjay A.[1], Sirsat Devanand[1]
[1]Veermata Jijabai Bhosale Udyan & Zoo, Mumbai (V.J.B.Udyan & Zoo)
*Valsarajan Dipika- Veterinary Officer
vjbudyanzoo@yahoo.co.in

Tuberculosis is one of the causes of mortality in captive deer species. Captive deer are more commonly affected by *Mycobacterium bovis,* however, there are also reports of occurrence of *Mycobacterium tuberculosis* (which generally affects humans and primates) in deer. Intradermal Tuberculin Test, bacterial culture and acid fast staining, PCR *etc*. are the different diagnostic tools for detection of *Mycobacterium*. An adult male Sambar deer at V.J.B. Udyan & Zoo was being treated for thoracic abscesses. The course of the treatment included wound dressing, parenteral Enrofloxacin and Meloxicam, oral liver tonic, multivitamin and mineral supplements. Deworming with Fenbendazole and Ivermectin was also completed. The abscesses started to heal, however, weight loss, alopecic patches on the body and general weakness were observed after one and half months. The deer later showed difficulty to walk immediately after standing up and was found on lateral recumbency. It was assisted to sit on sternal recumbency and after treatment the deer was able to stand. On the third day, however, the deer was again found on lateral recumbency and died after the treatment. During necropsy, the gross lesions were indicative of Tuberculosis. Caseous tubercles of varied sizes were present on the lung parenchyma and kidney cortex and medulla. Lymph nodes (LN) were also enlarged with caseous pus. Plenty of acid fast bacilli were detected on Ziehl Neelson stained smears of the LN pus. Further, *Mycobacterium tuberculosis* without resistance to Rifampicin was detected using Real time nested PCR by GeneXpert. GeneXpert MTB/RIF assay is an efficient and sensitive tool to detect *Mycobacterium tuberculosis* and identify Rifampicin resistance.

CBF 19

ANTIMICROBIAL RESISTANCE PROFILES AND MOLECULAR PHYLOGENY OF ESBL DETERMINANT GENES IN *Escherichia coli* IN CAMP ELEPHANTS OF KARNATAKA

Lallianpuii Kawlni[1], Sanath Krishna Muliya[1], Priyanka Dutta[1], Mujibur Rehaman[2], Vishnupriya Kolipakam[1], T.K. Dutta[3], Belinda Vangchhia[4], Kafil Hussain1, Qamar Qureshi[1] and Yadvendradev Jhala[1]

1 Wildlife Institute of India, Dehradun, Uttarakhand - 248 001. 2 Nagarhole National Park And Tiger Reserve, Hunsur, Karnataka – 571201. 3 College of Veterinary Sciences & A.H, Central Agricultural University, Aizawl, Mizoram – 796014.4 Zoram Medical College, Falkawn, Mizoram- 796005

kafilhussain@wii.gov.in

The close association of mahouts with camp elephants and the subsequent interactions of camp elephants with the free ranging wildlife establishes opportunities for cyclical transfer of Anti-Microbial-Resistance (AMR) between wild and captive populations, as well as to humans. Given the ecological implications of antimicrobial resistance, a pilot study was done to look at the antimicrobial resistance pattern and the associated resistance genes at an elephant camp in Karnataka, India. Rectal swabs from 27 elephants were cultured for E. coli using suitable techniques, among which 66.66% showed intermediate resistance to ceftriaxone, 37.03% showed intermediate resistance to ciprofloxacin, 18.51% showed intermediate resistance to gentamycin and 11.11% showed complete resistance to both ampicillin and amoxicillin. A total of 6 (23.08%) isolates were resistant to at least three classes of antimicrobial agents. Double disk diffusion test was done for isolates showing resistance to test Extended spectrum beta-lactamases (ESBL) production. Among the AMR genes, blaCTX-M (7.69%) and blaTEM (3.85%) was found to be the determinant gene and were subjected to sequencing and phylogenetic analyses. This study highlights the possibility of spread of AMR into these three participating entities- human, captive elephants and free ranging animals and may be responsible as the medium for cycling of AMR between human/captive elephants and the environment.

CBF 20

PARASITIC INFECTION IN HILL PRINIA: A CASE REPORT

Rupali Masand

Veterinary Pathology, DGCN, COVAS, CSKHPKV, Palampur

r.masand93@gmail.com

Hill prinia was presented for necropsy examination to the Department of Veterinary Pathology, Palampur in order to access the cause of death. The thorough and detailed

examination of the carcass revealed parasitic ingluvitis and ventriculitis along with roundworms, which disseminated throughout the carcass of the bird. The pulmonary congestion along with peritonitis was also observed on gross necropsy examination. These roundworms were identified as *Acuari subula*. Histopathological examination showed hypertrophy causing thickening of glandular mucosa along with denuded basement membranes and necrotic lesions.

CBF 21

POST MORTEM INVESTIGATION OF DEATHS IN WILD BOARS AT BHADRA WILDLIFE RANGE, KARNATAKA

Manjunatha, S.S., Kavitha Rani, B., Jayaramu, G.M., Kiran H. J. and Vinay, S.
Department of Veterinary Pathology, Shivamogga
Karnataka Veterinary Animal and Fisheries Sciences University (KVAFSU),
Karnataka, India-577204
drssmanjunatha@gmail.com

A Postmortem investigation of Wild Boars died in many numbers in short duration of one month interval at Bhadra wildlife range, Lakkavalli, Chikkamagaluru district, Karnataka, India was carried out. A total of eighteen Wild Boars were died and Post Mortem examination was carried out in six animals. The Wild Boars were subjected to detailed necropsy and external examination revealed congested conjunctival and nasal mucous membranes, erythematous patches over lower abdominal areas, subcutaneous congestive to hemorrhagic patches at multiple areas under the skin and bloated abdomen. Internal examination revealed severe congestive changes in spleen, Liver was hard in consistency with granular surface. Kidneys showed moderate congestive changes along with softening. Serosal vessels over the stomach were congested, mesenteric vessels were congested along with patchy congestive changes over the mucosal surface of the intestine. Urinary bladder was distended with yellowish granular urinary content. Coronary vessels were congested, right ventricular hypertrophy and both epicardial and endocardial hemorrhages were noticed predominantly. Patchy pneumonic changes in lungs involving congestion, edema and hemorrhages were noticed. Female pregnant wild pigs revealed multiple dead foetus in the Uterus with severe hemorrhagic lesions. Based on Post Mortem observation death of Wild Boars were tentatively suspected for generalized septicaemia and relevant samples were sent for microbiological investigation and further confirmed it for *Streptococcal* infection and indicated death of Wild Boars due to bacterial septicaemia.

CBF 22

PATHOLOGICAL FINDINGS IN COLD SHOCK IN A PEACOCK -A CASE REPORT

Aprajita Johri and A.P.Singh
Government Veterinary Hospital, Department of Animal Husbandry, Jaipur
Rajasthan
johriaprajita@gmail.com

Recently, a Peacock of peculiar features with Cold shock was presented to Veterinary Hospital ,Triveni Dham ,Shahpura , Jaipur by Forest Range Officer, Forest Range, Shahpura for complete necropsy. The peacock corpse was opened. Preliminary results and external examination revealed: the body was in Rigor Mortis, Eyes opened, Pupil dilated, Mouth opened, Neck twisted, Legs twisted. The internal Examination showed: Crop was filled with undigested feed, Severe congestion of lungs, Heart was filled with dark unclotted blood, Liver enlarged and hard, Frothy and ballooning of intestine due to acidosis when peacock deprived water in winter season. In Conclusion, Cold Shock is a stress inflicted by a rapid exposure to Low but non freezing Temperatures. Also Knows as Direct Chilling injury, is dependent on rate of cooling; greater injury is caused by more rapid cooling.

CBF 23

HISTOPATHOLOGICAL STUDY IN AILING PIGEONS

Panchbhai C.G., Dhoot V.M., Bhojne G.R., Kalyani Thakur, Kriti Dohre and Sameeksha C.
Department of Clinical Medicine, Ethics and Jurisprudence, Nagpur Veterinary College, Nagpur
checkpunch@rediffmail.com

Over the last few years, several deaths of pigeons have been reported from different parts of the country, however, causes have not been explored. The present histopathological investigation is important criterions to derive data that can be used for disease control and reduce mortality in pigeons. It was carried out in ailing pigeons of the Nagpur city. The succumbed birds were subjected to detailed necropsy examination. On post-mortem examination, grossly liver and lungs showed congestion. Histopathologically, liver showed vacuolar degenerative changes, necrosis of hepatocyte with infiltration of leucocyte. Congestion with pneumonic changes and anthracosis were observed in lungs, however, kidneys showed granular degenerative changes in tubular epithelium with evident interstitial nephritis. The increase in the space of Virchow-Robbin and degenerative changes were recorded in brain tissues. Anthracosis reported in the current study may be due to accumulation of carbon in the lungs due to repeated

exposure to air pollution or inhalation of smoke or coal dust particles which can be a measure that reveals upsurge air pollution in the city.

CBF 24

EFFECT OF PROBIOTICS SUPPLEMENTATION ON FAECAL PROGESTERONE HORMONE IN ASIAN ELEPHANTS

Dharmendra Chharang[1]*, Sheela Choudhary[1],Vinod Kumar[2], Govindhaswamy Umapathy[2], Hemant Joshi[3], Monika Karnani[1] and Manju[1]
[1]Department of Animal Nutrition, Post Graduate Institute of Veterinary Education and Research, Rajasthan University of Veterinary and Animal Sciences, Jaipur 302031, India
[2]Laboratory for the Conservation of Endangered Species, CSIR-Centre for Cellular and Molecular Biology, Uppal Road, Hyderabad 500007, India
[3]Department of Veterinary Anatomy, Post Graduate Institute of Veterinary Education and Research, Rajasthan University of Veterinary and Animal Sciences, Jaipur 302031, India
dchharang@gmail.com

Measurement of faecal progesterone as a non-invasive technique is widely used to monitor reproductive hormones in captive and free-ranging wild animals. A study was conducted to evaluate the effect of dietary probiotics supplementation on progesterone hormone level in faeces of 18 adult captive Asian elephants of 3495 ± 133.34 kg body weight (BW) to observe the results in different groups, i.e., control with no probiotic (T_1) and the other two with probiotics (@ 10^9 CFU/g concentrate per 50 kg BW per day) *Lactobacillus acidophilus* (T_2)and *Saccharomyces cerevisiae* (T_3). The elephants were randomly divided into three groups with six elephants each. They were fed on *ad libitum* green fodder. The faecal samples were collected on 0, 30th, 40th and 50th day of the experimental feeding of probiotics. It's concluded that the mean faecal progesterone values of the elephants of T_2 and T_3 groups were not significantly different from the control group (T_1).

CBF 25

POST MORTEM FINDINGS IN AN INDIAN SPOTTED EAGLE-A CASE REPORT

S Sood, A Sharma, N Nashiruddullah, S Rahman,A Kumar, and S Sharma
Division of Veterinary Pathology, College of Veterinary Sciences and Animal Husbandry, SKUAST-Jammu, RS Pura-181102, Jammu, Jammu and Kashmir
shilpasoo@gmail.com

An Indian spotted male eagle (*Clanga hastata*) was found dead in the campus compound near girl's hostel of Faculty of Veterinary Science an Animal husbandry, SKUAST-Jammu and brought to the Division of Veterinary Pathology for post mortem.

The carcass was in a poor body condition and a thorough post mortem examination was conducted. Salient post mortem findings included an enlarged and congested liver. Testes, brain and kidneys were also severely congested while no obvious lesions were appreciated in other internal organs. Also, no external or internal parasites were found. Tissues were collected in 10% formalin and processed for a routine histopathological examination, which revealed severe dilatation and engorgement of blood vessels in liver, kidneys, testicles and brain. Hepatocytes were degenerated and sinusoids were severely dilated. Multifocally aggregations of lymphocytes were present throughout parenchyma and more prominently around portal triads. In cerebrum, focal neuronal degeneration and gliosis were evident, apart from severely congested blood vessels. Seminiferous tubules in testes and renal tubular epithelium were also found to be severely degenerated. Due to lack of resources further diagnostic tests could not performed. Overall the eagled appeared to have died of a severe systemic infection particularly affecting its brain, liver, kidney and testicles.

CBF 26

MORPHOMETRIC AND RADIOGRAPHIC CHARACTERISTICS OF THE SKULL IN CRESTED SERPENT EAGLE (*Spilornis cheela*) AND BROWN WOOD OWL (*Strix leptogrammica*)

O.P. Choudhary, P.C. Kalita, A. Kalita and P.J. Doley
Department of Veterinary Anatomy and Histology, College of Veterinary Sciences and Animal
dr.om.choudhary@gmail.com

Husbandry, Central Agricultural University (I), Selesih, Aizawl-796015, Mizoram, India. The previously reported information on the morphology of crested serpent eagle and brown wood owl skeleton is meager as compared to the fowl; thus, the present study was designed to provide the morphological features of the skull of both species. The specimens were procured from four crested serpent eagle and brown wood owls, brought from the Zoological Park, Aizawl for the post mortem examination conducted at the Department of Veterinary Pathology, College of Veterinary Sciences and Animal Husbandry, Aizawl, Mizoram. After the post-mortem examination, the collected specimens were macerated by the standard maceration technique and radiographs were taken at the Mizoram Health Centre, Aizawl. The skull of both the species consisted of neurocranium and viscerocranium, which were separated by two large orbital cavities. The neurocranium was composed of single (occipital, sphenoid, ethmoidal) and paired (temporal, parietal and frontal) bones in both the species. The viscerocranium consisted of single bones (mandible, vomer and hyoid) and paired

(quadrate, lacrimal, nasal, premaxilla, maxilla, zygomatic, palatine and pterygoid) bones. The skull of both the species was dolichocephalic as per the cephalic index, which was 52.63±0.04 and 68.56±0.03 in crested serpent eagle and brown wood owl, respectively. The results showed that there were variations in the shape and components of crested serpent eagle and brown wood owl skull bones in comparison with other birds.

CBF 27

GROSS MORPHOLOGICAL AND LIGHT MICROSCOPIC STUDIES OF THE SPLEEN OF MALAYAN SUN BEAR *(Helarctos malayanus)*

P. C. Kalita, A. Kalita, O. P. Choudhary, and P. J. Doley
Department of Veterinary Anatomy and Histology,
College of Veterinary Sciences and Animal Husbandry,
Central Agricultural University, Selesih, Aizawl-796014, Mizoram
kalitapc@yahoo.co.in

Gross morphological and light microscopic studies was conducted on the Spleen of a Malayan Sun Bear brought to the College of Veterinary Sciences and Animal Husbandry Selesih, Aizawl, Mizoram for postmortem examination from Aizawl State Zoo. The spleen of Malayan Sun Bear was located in the left hypogastric region and entirely intrathoracic as the stomach was almost empty. It was purple in color. The spleen was narrow in the middle and wider at either ends, with the ventral end being the widest and often curled inwards. The organ presents parietal and visceral surfaces, with the latter containing the long hilus. The parietal surface faces the diaphragm and left lateral abdominal wall. The visceral surface was divided into gastric face and intestinal face by the ridge like hilus. The hilus contains numerous blood vessels. Histological studies revealed that, the spleen of Malayan Sun Bear was surrounded by a thick connective tissue capsule invested by the peritoneum. The capsule, trabeculae and reticular fibers support the splenic parenchyma composed of a red pulp involved in the storage of red blood cells and a white pulp rich in lymphocytes and active in immune responses. Most of the splenic parenchyma was red pulp, owing its name to the vast amount of blood held within the reticular network. The red pulp was composed of venous sinuses or venules and splenic cords. The Malayan Sun Bear spleen has typical venous sinuses. Dense accumulations of lymphocytes, arranged around central arteries, form the periarterial lymphatic sheaths (PALS). Lymphatic nodules along with PALS, comprise the white pulp. Nodules of the white pulp were B-cell zones and may or may not have germinal centers, depending on their functional state. The PALS were organized along the artery of the white pulp. Within the PALS, T cells were concentrated adjacent to the tunica media of the artery, whereas the peripheral region of the sheaths contains a more diverse mixture of T cells and B cells, macrophages, and dendritic cells.

CBF 28

FOOT AND MOUTH DISEASE SERO-SURVEILLANCE AT BUFFER AREA OF RESERVE FORESTS IN UTTARAKHAND

Sagar A Khulape, J K Biswal, Chandrakanta Jana, Manish Kumar, J K Mohapatra,
Raj Kumar Singh and Bishnu Prasad Mishra
ICAR- Directorate of Foot and Mouth Disease, Mukteshwar
virtualsagar4max@gmail.com

The reserve forests of Uttarakhand cover almost 70% of the total geographical area of the state. These reserves harbour domestic and wild ruminant populations in close vicinity, and these wild ruminant populations act as prey for various inhabiting carnivores in forests. Thus, any disease transmission in the cattle population at the domestic-wild interface may directly impact the ecological food chain of reserve forests. Foot and Mouth Disease (FMD) is highly contagious and infects more than 70 wild and domestic animal species. In this cross-sectional study, a real-time diagnosis of FMD prevalence is made in the domestic ruminant population at the buffer zone of the reserve forest area of Almora and Pithoragarh districts of Uttarakhand. We collected serum samples (n=100 each) from domestic cattle from designated buffer areas of forest reserves of Almora (Binsar) and Pithoragarh (Askote). In-house, Solid Phase Competitive ELISA (SPCE) and 3AB3-NSP DIVA ELISA were used to detect antibodies against Foot and Mouth Disease virus (FMDV). The SPCE test showed <5 % protective antibody titer in serum samples against FMDV for both districts. Similarly, serum samples demonstrated 29.06% and 35.26% 3AB3-NSP antibodies for Almora and Pithoragarh districts, respectively, and are towards the higher side of the national average (21.09%). The results indicate the long-term and extensive exposure of FMDV in the domestic cattle population. The study also stresses the need for a comprehensive vaccination approach against FMD in interface area of reserve forests.

CBF 29

A STUDY ON MORTALITY AMONG CAPTIVE GREEN ANACONDAS (*Eunectes murinus*)

Aparna S[1], Nandakumar S[1], Swapna Susan Abraham[1],
Prathuish PR[1], Sobha S S[1] Jacob Alexander[2] Kalpana B[1]
1. Centre of wild life sciences, State Institute For Animal Diseases, Animal Husbandry Department, Kerala
2. Zoological garden, Thiruvananthapuran
aparnaharidas@yahoo.co.in

A wide variety of pathogens are harboured by cold blooded animals particularly reptiles. They may become infectious and fatal during stress and immunosuppression. Mortality was reported among captive Anacondas, of Zoological garden, Thiruvananthapuram in a span of four months during the year 2019 with symptoms of anorexia, diarrhea accompanied by blood or bile-tinged green mucus, and remnants of intestinal mucosa. Postmortem was done on four Anaconda carcasses for elucidating the cause of mortality at Centre for Wildlife Sciences, State Institute for Animal Diseases Palode, Kerala which revealed similar lesions of varying severities. Necrotising enterocolitis and Ulcerative gastroenteritis were identified as the cause of death. Microscopical examination of intestinal contents revealed trophozoites of *Entamoeba sp*. *Aeromonas hydrophilla* was isolated from heart blood culture. Although many species of protozoans can be found in reptiles, *Entamoeba invadens* is the most clinically important protozoan parasite associated with high mortality in affected snakes and lizards. In captive snakes, *Aeromonas.hyrophilla* is proved to be associated with ulcerative stomatitis which may progress to septicaemia and eventually spread to other organs. Concomitant infection with Entameoba invadens and Aeromonas hydrophila in a captive anaconda was earlier reported by Park *et al*, 2019. Treatment of the surviving Anacondas with similar symptoms in the Zoological garden, Thiruvananthapuram with Metronidazole and Enrofloxacin proved effective.

CBF 30

INCIDENCE OF ELECTROCUTION IN A WILD ASIATIC ELEPHANT (*Elephas maximus*)

Somesh Singh, Devendra Podhade, A.B.Shrivastav, *Sandip Agrawal, Sriram Guntoju
School of Wildlife Forensic and Health, NDVSU, Jabalpur, M.P.
*Kanha Tiger Reserve, Mandla, M.P.
drsomeshsingh2007@gmail.com

Carcass of an Asiatic elephant (*Elephas maximus*) was sighted in adjoining fringe forest area of Jabalpur. The animal was one among the two male elephants being sighted near the city for few days. The carcass was lifted using a hydraulic crane and brought to the Gosalpur Timber Depot, Jabalpur for necropsy. It was a young male elephant of approximately 15-20 years of age. The rigor mortis was present in hind limbs and animal died approximately 8 to 16 hours before necropsy examination. External examination revealed 6 cm deep cut mark on the right side of trunk (at a distance of 16 cm from trunk tip) and presence of a piece of wire adhered to the wound. Sloughing of skin on ventral side of trunk just above the nostrils, and around the cut wound was seen. The

charred marks on the ventro-lateral side of trunk and pinpoint charring marks in footpad of right forelimb were noticed. The mucous membranes were congested. Subcutaneous haemorrhagic areas of varying sizes were observed in trunk and jaw junction, and engorgement of blood vessels at thoraco-abdominal region was seen. Oral cavity was soiled with blood mixed fluid with severe congestion in gums and palates. Muscular haemorrhages were seen in trunk and jaw junction. The diffused blackish discolouration and petechial haemorrhages were observed over the tongue. Extensive congestion was seen in large intestine. The mesenteric lymph nodes were enlarged. The liver was swollen. Nostrils were soiled with blood tinged fluid and extensive petechial haemorrhages were observed in lungs. Haemopericardium and endocardial haemorrhages with severely congested vessels were observed. Heart chambers showed the presence of semi clotted blood. The spleen and kidneys were congested. The external observation and gross lesions were suggestive of electrocution. Meanwhile, the offenders involved in the incident were identified. The young elephants sometimes venture out of the forest areas in quest for food, water and shelter, and misplaced due to loss of natural corridors and become victim of such incidents. Emphasis is needed towards a refined policy for monitoring, protection and conservation of such animals in non protected areas.

CBF 31

ENTOMOLOGY AND ENTOMOTOXICOLOGY AS A POTENTIAL TOOL IN WILDLIFE FORENSICS

G A Dubey, AG Dubey, and CP Sharma
Research Scholar Shri. Sivaji Science College Akola
drankush.dubey@gmail.com

Forensic Entomology is one of the important branches of forensic science, which primarily helps in calculating the minimum Post Mortem Interval (mPMI) from the first day to several weeks by observing stages of decomposition, insect population, pattern of arthropod colony succession, life cycle of particular necrophagous species or estimating the age of stages of arthropods feeding on decomposing carrion. Insects are attracted towards the dead animal within minutes after death and lay their eggs on carrion, preferably on orifices or wound where their life cycles begins. Poisoning of wild animals is quite common in poaching and in retaliatory killing of wildlife in man-animal conflict. Mostly Organophosphate group, which is locally available, used in poisoning of wild animals. Entomotoxicology is a new branch of Wildlife Forensic entomology which helps in detecting drugs and other toxins in decomposing tissues by investigating the presence of poison in insects feeds on carcass. In the absence of tissues and fluids normally taken for toxicological investigation, drug laden insect larvae feeding on the poisoned carcass

can be reliable alternate specimens by extraction from larvae through entomotoxicological methods. It investigates the effects caused by drugs and toxins on arthropod development in order to assist them PMI estimates. With the help of Entomology and Entomotoxicology, time and cause of death of the wild animal in wildlife offense cases providing vital scientific clues in further investigation and prosecution of the offenders.

CBF-32

VAGINAL CYTOLOGY IN A TIGERESS (*Panthera tigris tigris*)

Pawshe M. D., Patil M. S., Gawande A. P., Kolangath S. M., Upadhye S. V., Dhoot V. M., Syed Bilal Ali, Shalini A. S., Patond C.V. and Kate M. R.
Wiildlife Research & Training Centre, Gorewada, Nagpur
Opp. Hindustan Lever Godown Square, Mahurzari Road, Fetri, Nagpur - 441501
drmayurpawshe@gmail.com

To know the stage of oestrus in a two year old female tigress (T2C1) kept in captivity at Transit Treatment Centre, Nagpur, vaginal cytology – a non invasive technique was used without tranquilizing the animal. In this technique, the tigress was restrained in a squeeze cage and after proper conditioning of the animal, vaginal swab was collected by inserting the sterile swab in the vagina. The same swab was rolled on a cleaned glass slide immediately and after drying the smear, it was stained with Leishman's stain. The vaginal swabs were collected sequentially on alternate days for 6 times. The stained slides were observed under the microscope. Epithelial cells transformation from superficial cells to cornified cells concomitant with the behavioral expression of estrus by the tigress was observed.

CBF-33

ROLE OF BLOW FLIES MAGGOTS IN WILDLIFE FORENSICS

Kritika Singh and KP Singh
School of Wildlife Forensic and Health, Nanaji Deshmukh Veterinary Science University Jabalpur
drkpsingh1963@gmail.com

Wildlife forensic is one of the emerging tasks under biodiversity conservation owing to expansion of human communities and narrowing the forest boundaries. Retaliate killing and poaching of endangered species of wild animals needs their scientific investigation leading to collection of evidences for prosecution and conviction of poachers. Besides that, calculation of elapsed time of death is also difficult

task particularly in protected and non protected forest areas because spotted carcass mostly found in decomposed stage. Keeping this view in mind the study was focused for inspection of such type of carcasses and commenced with following the standard protocols for instars identification of maggots through their spiracles and teguments. Overall 40 carcasses were incorporated in the study including carnivores and herbivores. Carcasses of 10 leopards and 8 tigers were studies and from identification of III instars maggot and their spiracles the elapse time of death was estimated. The correlation of rigor mortis and livor mortis as well as liquidification rate of the carcass were also taken into account. Of 18 carcasses, only in two cases, rigor mortis was observed while most of the carcasses seen in putrefied condition and III instars larvae almost eaten the body part. The elapse time of death was calculated and found to be around 96-144 hrs of death in most of the cases. Carcasses of 22 herbivores including Chital Sambar, Barasingha, and Langur were examined and elapse time of death was estimated around 18-24 hrs in those carcasses where rigor mortis was seen while rigor mortis was absent most of the cases and carcasses seen decaying thus the elapse time of death was estimated around 120 to 144- hrs. After 144-166 hrs the maggot's developing in to pupa and starts leaving the carcass. The study is in progress and would be beneficial for wildlife forensics.

CBF-34

CLINICOPATHOLOGY OF HEPATO-RENAL DYSFUNCTION IN A LEOPARD (*Panthera pardus*)

M. S. Hedau, M. P. Kaore, M. D. Pawashe, S. Kolangath and N.V. Kurkure
Department of Veterinary Pathology
Nagpur Veterinary College, MAFSU, Nagpur - 06 M.S. India
drmshedau1@gmail.com

The present case of hepato-renal dysfunction was observed in 8 years old female leopard belonging to Gorewada Rescue Centre, Gorewada, Nagpur. Necropsy was conducted and representative tissues from various organs were fixed in 10% formal saline. Formalin-fixed tissues were processed routinely and stained with haematoxylin and eosin (HE). The BUN, creatinine and potassium levels were high indicating renal damage. The values for AST, ALT and total bilirubin were found increased reflecting hepatic injury whereas decreased values for ALP, glucose and calcium showing damages to other body organs. External examination revealed yellowish discoloration of gums and mucous membranes. There was generalized icterus. On evisceration, the liver and spleen were enlarged and both kidneys were showing yellowish discoloration of pelvis along with haemorrhages. The wall of the urinary bladder was thickened with yellowish

discolouration. There was severe epicardial and endocardial haemorrhages along with serous fluid in pericardial sac. Histopathologically, liver revealed severe degenerative changes with fibrous tissues and haemorrhages. Lungs revealed severe oedematous changes along with mononuclear cell infiltration. Heart revealed degenerative changes along with haemorrhages in muscle fibres. Severe diffuse tubular necrosis with pyknotic nuclei and moderate renal tubular degeneration were also observed.

CBF-35

SUCCESSFUL POSTHUMOUS EPIDIDYMAL SPERM RETRIEVAL FROM SPOTTED DEER (*Axis axis*)

Kolangath S.M., Pawshe M.D., Upadhye S.V., Dhoot V.M., Gawande A.P. and Shalini A.S.
Wildlife Research & Training Centre, Gorewada, MAFSU, Nagpur
brosujit@gmail.com

A Spotted deer (*Axis axis*) was referred to the Wildlife Research and Training Centre, Gorewada with a history of fracture in the right forelimb. The animal succumbed after 3 days of treatment following which the epididymal sperm retrieval was initiated. The Triladyl Egg Yolk (TEY) extender was prepared and filtered through Whatman filter paper 125 mm. The epididymis was carefully dissected to retrieve the sperms by retrograde flow method and re-suspended in TEY extender. The sperms were incubated at 35° C for 30 minutes following which the extended semen was subjected to sperm quality assessment. The retrieved sperms were stored at 4º C for the next 96 hours and were investigated for motility, sperm concentration, acrosome studies, live -dead count, sperm abnormality and Methylene Blue Reduction Time (MBRT)at 0, 24, 48, 72 and 96 hours using standard protocol. The quality of sperm showed gradual qualitative and quantitative deterioration. Post 72 hours there was a significant drop in motility and live count and there was a significant rise in abnormalities and MBRT parameters. The study is a model study for the preservation of posthumously retrieved epididymal sperms from endangered herbivores and has application in wildlife conservation biotechnology.

SESSION-VI
POSTER PRESENTATION

REPAIR OF A LACERATED WOUND IN AN INDIAN COBRA (*Naja naja)*

Ankur Sharma, R.B.Kushwaha, P.Gupta, A.K.Gupta, S. Borkataki and M.S. Bhadwal
Division of Veterinary Surgery and RadiologyFVSc& AH, SKUAST-J, RS Pura, Jammu-181102
ankurvets@gmail.com

An adult Indian Cobra (*Naja naja*), about 5 feet long and weighing 4.5Kg was brought by a snake lover to Teaching Veterinary Clinical complex, FVSc & AH, SKUAST-J, RS Pura, Jammu with the history of injury inflicted by a beer can in which it had hidden to escape being attacked by people. On clinical examination, it was observed that there was a lacerated woundon the ventral scales of the neck region with removal of the ridged scales. The snake was anaesthetized with Ketamine hydrochloride @ 50mg/kg body weight i/m and the wound was repaired using nylon 2-0 in an interrupted suture pattern and bandaged. Post-operatively antiseptic dressing with povidone iodine was advised for 5 days. Skin sutures were removed on 8th post-operative day and the snake was released into the wild after recovery.

POST-2

SUCCESSFUL TREATMENT OF ABSCESS DUE TO FRACTURED TOOTH IN INDIAN PYTHON (*Python molurus*)

[1]Syed Bilal Ali, [1]Mayur R. Kate ,[2]Shubhangi Warke,[3]S.V. Upadhye and [2]Shreelaxmi Nair
[1] Veterinary Officer, Transit Treatment Centre, Nagpur Forest Division, Seminary Hills, Nagpur,
[2]Department of veterinary Microbiology, [3] Department Veterinary of Surgery and Radiology,
Nagpur Veterinary College, Nagpur
drsyedbilalali086@gmail.com

A python (*Phython molurus*) was rescued and presented to Transit Treatment Centre with a history of anorexia since two days. On oral examination, it was observed that, there was soft tissue swelling in an area with a caseous discharge. Culture sensitivity of caseous discharge revealed *Proteous vulgaris* as the isolate. The isolate was sensitive to cefitazidine. The python was treated with inj. Ceftazidime @ 20mg/kg IM, q72h and Meloxicam @0.5mg/kg. Also, regular dressing of wound was undertaken with normal saline and betadine. The condition improved in a week and the swelling totally subsided by 10th day with restoration of appetite and activities. The python was rehabilitated into its natural habitat.

POST-3

SUCCESSFUL WOUND MANAGEMENT OF TIGRESS

[1]Syed Bilal Ali, [2]M.D. Pawshe, [3]C.V. Patond,[1]M.R. Kate, [4]S.V. Upadhye, [5]V.M. Dhoot, [6]G.R. Bhojne

[1]Veterinary Officer, Transit Treatment Centre, Nagpur Forest Division, Nagpur, [2] SMS (ARGO), WRTC, Gorewada, Nagpur, [3]Veterinary Officer, Pench Tiger Reserve, Nagpur, [4]Director WRTC, Gorewada, Nagpur, [5]Deputy Director, WRTC, Gorewada, Nagpur, [6] Assistance Professor, Department of Veterinary Clinical Medicine.

drsyedbilalali086@gmail.com

A female tigress named T2C1 approximately 2 years of age captured from Pandharkawada Division by using chemical immobilization technique. Clinical examination at field revealed perforated wound on the dorsal border scapula. In view of this, the animal was transferred for advanced treatment care and management at Transit Treatment Centre. The wound was about 3inch; long and 3.5 inch deep. The wound having purulent discharge and necrotic debris were oozing out and foul smelling. On palpation, slight crepitation of wound was noted. The tigress was treated with antibiotic, anti-inflammatory and analgesic drugs for fast recovery. The wound discharge was examined for Antibiotic sensitivity Test (AST). The organism of wound showed sensitivity to cefovecin antibiotic. The inj. Cefovecin was administered parenterally @ 8mg/kg body weight. Also, routine biological dressing of the wound was carried out for a month on alternate days. Thus, AST can be easy diagnostic tool for selection of antibiotic which allows fast healing of infected wounds in large felids.

POST-4

ISOLATION AND IDENTIFICATION OF *S.mercescens* FROM MARSH CROCODILE –A CASE REPORT

U.M.Tumlam, M.M.Pawade, C.S.Mote, R.V.Jadhav, S.J.Virshette, S.R.Warke, P.P.Mhase & D.M.Muglikar

Department of Veterinary Microbiology, KNPCVS, Shirwal Dist.Satara (M.S)

uma_tumlam@yahoo.com

A Bacterial cultures and biochemical analyses were performed from Post-mortem tissue of one 40yr Marsh crocodile of Rajiv Gandhi and Wildlife research Centre,Pune with the history of off-feed from last three 3 months.We recovered 2 bacterial isolates from lung tissue sample belonging to the family Enterobacteriaceae. The sample was positive for *E.coli*.and *S. marcescens* was carried out by morphological, biochemical and

cultural characterization. *S.mercesens* has emerged as a serious healthcare-associated pathogen renowned for its ability to exhibit multiple antimicrobial resistance. Further the *E.coli,* isolate were subjected to molecular characterization for the detection of 16SRNA and confirmed by phylogenetic analysis and sequencing. The bacteria isolated represent a potential threat to crocodile health during conditions of stress and a threat to human health through crocodile bites, crocodile meat consumption or carrying out activities in crocodile habitat. We especially warn about the presence of *S.mercescens* which causes urinary tract infections, wound infections, and pneumonia in crocodiles. The risk of bacterial contamination from crocodiles to humans could increase in the future because of the accelerated destruction of crocodile habitat, which could lead to an augmentation of human-crocodile interactions.

POST-5

CONCURRENT OCCURRENCE OF METASTRONGYLOSIS AND GNATHOSTOMOSIS IN A WILD BOAR (*Sus scrofa*)

Devi, S. S[1]., Megha, K. G[1].,Ajith, J. G[1]., Sairam,R[1]., Shabeeba, P.M[1].,Divya, C[1]., Sajitha, I.S.[1] and Asha, R[2].

[1]Department of Veterinary Pathology [2] Department of Veterinary Parasitology
College of Veterinary & Animal Sciences, Mannuthy, Kerala
deviss@kvasu.ac.in

Free living feral pigs are known reservoirs of various pathogens, many of which are transmissible to domestic animals and humans. This abstract communicates the occurrence and risk of infectious agents in wild boars and their potential transmission to livestock and humans. An ailing wild boarwas rescued by forest officials and was brought to University Veterinary Hospital, Mannuthy. The animal had died on its way to hospital and was referred for post-mortem examination in the Department of Veterinary Pathology, College of Veterinary and Animal Sciences, Mannuthy. A detailed necropsy was conducted and gross lesions were recorded. Representative tissue samples were fixed in 10 % neutral buffered formalin for histopathology. Necropsy revealed long slender white coloured worms in the lower trachea and bronchi, multiple abscesses in the cranioventral aspect of apical pulmonary lobes, focal areas of hepatic necrosis and presence of adult round worms seen burrowing into the stomach wall. The worms in the respiratory tract were identified from the Department of Veterinary Parasitology as *Metastronglus sp*. And that from stomach were *Gnathostoma sp*. Both the worms are potentially pathogenic and can cause serious consequences in the host animal. Lung worms predispose the animals to a variety of secondary infections by several viral and

bacterial agents. The abscesses in the lungs could have resulted from secondary bacterial complications and the examination of impression smears from lungs revealed the presence of numerous bipolar organisms and cluster of cocci. Microscopically the lesions in lungs consisted of suppurative broncho pneumonia along with edema and formation of fibrin thrombi. *Gnathostoma spp*. Burrowing deep into the stomach wall can cause cystic cavitations which can ultimately get transformed into tumours. In the present case, the worms had formed small holes/ cavities on stomach walls at places where they penetrate the mucosa. Also larval migratory tracts in the liver could be appreciated as focal white spots on the surface. Histopathological examination of liver also confirmed necrotic and degenerative changes along with areas of fibroplasia. Based on the gross and microscopic findings the cause of death was concluded as suppurative bronchopneumonia which could have resulted from secondary bacterial complications induced by lung worm infection. The findings also indicated the potential risk of humans contracting gnathostomosis by consumption of undercooked meat of feral pigs and *via* cutaneous penetration by larval forms

POST-6

PIROPLASMOSIS IN DONKEY *(Equus asinus)* – A CASE REPORT

Karthika R, Pooja G Mankani, BinduLakshmanan and Devada K.
Department of Veterinary Parasitology,
College of Veterinary and Animal Sciences,
Mannuthy, Thrissur, Kerala
Kerala Veterinary and Animal Sciences University
karthi.arunthi@gmail.com

A total of 25 blood smears of donkey were presented to the Department of Veterinary Parasitology, CVAS, Mannuthy, with a history of pyrexia, anorexia and weakness. Routine blood smear examination revealed the presence of haemoparasites *Theileria equi* and *Babesia caballi*. Out of 25 blood smear examined, 7 were positive for *T. equi* and *B. caballi*. Piroplasmosis in donkeys, caused by *T. equi* and *B. caballi* has been recognized as a serious problem of major economic importance as the affected animals manifest, decreased working capacity and loss of appetite. Transimission of disease occurs from animal to animal through ticks such as *Hyalomma* spp., *Rhipicephalus* spp., and *Dermacentor* spp. The disease condition starts with intermittent fever, listlessness, depression, inappetance, anemia, watering from the eyes and swelling of the eyelids. Donkeys usually remain asymptomatic in low prasitaemia. Early detection and prevention are based on the use of preventive techniques via analysis of animals for

the presence of ticks and routine blood smear examination. Preventive treatment with oxytetracycline and imidocarb@ 5 to 10 mg/ kg body weight for two days was advised to avoid mortality. Detection of asymptomatic animals is essential to avoid the introduction of organisms into nature and to prevent the spread of diseases to healthy wild populations.

POST-7

MYELOGRAPHY IN C*anis lupus* (INDIAN WOLF)

[1]Mayur R. Kate, [1]Syed Bilal Ali, [2]S.V. Upadhye, [2]G.Khante
[1]Veterinary Officer, Transit Treatment Centre, Nagpur Forest Division, Nagpur,
[2]Department of Veterinary of Surgery and Radiology.
mayurkate.kate4@gmail.com

Myelography is the special radiographic technique by which the spinal cord is outlined by a positive contrast medium injected into the sub-arachnoid space. Prompt and accurate diagnosis is the foremost requirement for treating spinal trauma in animals. Myelography performed following plain radiography, aids in confirmation and localization of spinal injury and evaluation of its severity and extent. General anesthesia was administered to the wolf. The back is arched dorsally with wolf in sterna recumbency. A 3-inch 22 G needle with syringe is introduced in the midline just anterior to L6 (i.e. 5th lumbar space). Cerebrospinal fluid 1-3 ml is removed for examination and radiographic contrast medium inj. Iohexol injected slowly and carefully. The spine tilted for some time toward the head (20^0) to encourage cranial migration. In myelography it was observed that, there was shortening and compression at the level of 1st and 2nd Lumbar vertebrae.

POST-8

SUCCESSFUL REUNION OF LEOPARD CUB WITH HER MOTHER

[1]Mayur R. Kate, [1]Syed Bilal Ali, [2]Prabhunath Shukla, [3] K. Hate and [4]V. J. Arora
[1] Veterinary Officer, Transit Treatment Centre, Nagpur Forest Division, Seminary Hills, Nagpur,
[2]Deputy Conservator of Forests, Nagpur Forest Division, Nagpur, [3]Member: Wildlife Advisory Board, Maharashtra State, [4]wildlifer.
mayurkate.kate4@gmail.com

A leopard cub was spotted inside a well in agricultural field at Itanboti village, in Kalmeshwar Range of Nagpur forest Division. The cub was rescued by using snares from

well by local villagers. After reaching the spot, the examination team revealed that, the male leopard cub was approximately of 6-7 months. All physiological parameters was recorded. The rectal temperature was 96.8^0 F and continuous shivering of cub was noted. The cub was stabilized by dryer and kept in warm condition. It was fed with par-boiled chevon. As per, local villagers and forest staff, regular sighting of the female leopard with the cubs in that premises was reported, presumably mother leopard in vicinity of that area. The team decided to attempt reunion in evening hours after analyzing the situation at the same spot from where the cub was rescued. The area was kept isolated and restricted the movement of people to provide the mother leopard, ample opportunity to retrieve her cub and move it to safer place. Trap cameras were adjusted and the cub was placed below the plastic crate with enough weight over it. The area was evacuated with no person in the vicinity. Next morning after reaching the spot the team was delighted to find that the cub was picked up by the mother leopard with sufficient evidence of camera trap photos thus victorious reunion was made for valuable conservation of wildlife.

POST-9

SURVEY OF GASTROINTESTINAL PARASITES OF *Boselaphus tragocamelus* (NILGAI) IN THE KARANJA SOHOL WILDLIFE SANCTUARY, INDIA

Milind Shirbhate*[1] and Amrita Shirbhate[2]
Department of Zoology, Shankarlal Khandelwal Arts, Science and Commerce College, Akola
Head, Department of Zoology, Mahatma Phule Arts and Science College, Patur Dist, Akola, Maharashtra
milindshirbhate2912@gmail.com

To study the prevalence of gastrointestinal parasites of *Boselaphus tragocamelus*, 40 faecal samples were collected from Katepurna Sanctuary during the census period and with the help of forest authorities. Thirty five samples were found to be infected with gastrointestinal parasites and overall prevalence rate was 90%. *Paramphistomum* sp. (25%), *Ascaris* sp. (20%) *Fasciola* sp. (15%),stomach worm (12.5%), hook worm (10%), *Strongyloides* sp. (7.5%), & Mixed type of infections of *Ascaris* sp. was found in 5 different scat samples or droppings.This study provided a first overview on parasites in *Boselaphus tragocamelus* in the KaranjaSohol Wildlife Sanctuary, but to evaluate parasite transmission dynamics much more studies were required on livestock and on wild herbivores.

POST-10

GROSS MORPHOLOGICAL CHARACTERISTIC OF SKULL IN INDIAN EAGLE OWL (*Bubo bengalensis*)

Sridevi P, Rajalakshmi K,SivaKumar M and Karthikeyan A
Department of Veterinary Anatomy and Histology
Rajiv Gandhi Institute of Veterinary Education and Research, Kurumbapet,
Puducherry- 605 009, India.
devisri1890@gmail.com

The present study was conducted with the aim to understand the morphological features of the skull in Indian eagle owl. The Indian eagle owl cadaverbrought for post mortem, Department of Veterinary Pathology, RIVER, Puducherry was macerated using standard maceration technique and various morphological features were recorded.The shape of the skull in Indian eagle owl was very broad.The skullIndian eagle owl consisted of neurocranium and splanchno-cranium separated by two large orbital cavities. The neurocranium composed of single (occipital, sphenoid, ethmoidal) and paired (temporal, parietal and frontal) bones. The splanchno-cranium consisted of single bones (mandible, vomer and hyoid) and paired (quadrate, lacrimal, nasal, premaxilla, maxilla, zygomatic, palatine and pterygoid) bones. Frontal bones were more the largest and were convex and smooth. The bony orbits were located anteriorly, relatively large and sclerotic tube was noticed. The supra orbital process was narrow, triangular and pointed which was directed laterally. The results showed that there were considerable variations present in gross morphology of the skull in Indian Eagle Owl.

POST-11

A CASE REPORT: *Metastrongylus elongates* INFECTION IN WILD BOAR, KERALA

Pooja G Mankani, AshaRajagopal, Karthika R and Devada K.
Department of Veterinary Parasitology,
College of Veterinary and Animal Sciences,
Mannuthy, Thrissur, Kerala
Kerala Veterinary and Animal Sciences University
poojamankani7@gmail.com

The species of the genus *Metastrongylus* are the lung worms of the swine and wild boars. It requires an obligate intermediate host (earthworn) to complete their life cycle and causes a potential risk to both humans and livestock. The *Metastrongylus* infestation is ever-present in wild boar populations. This study reports the lungworm

infestation in wild boar, the numerous lungworms were collected from the wild boar (*Susscrofa*) presented to post-mortem from the Department of Veterinary Pathology, CVAS Mannuthy. The collected worms were processed for the morphological identification of the species and morphometry was done. The worms were slender, whitish to yellow colour, the worms were about 2-4 cm long and females were longer than males. The eggs were ovoid measuring 53 x 40 µ, worms had long spicules bearing a simple terminal barb and more conspicuous copulatory bursa.Wild boars will be infested with several hundreds of worms without any significant harm so, further studies are needed in this area to establish the base line parameters for identification of infection.

POST-12

INTRAMEDULLARY PINNING OF TIBIAL FRACTURE IN AN INDIAN HERON (*Ardeola grayii*)

R B Kushwaha, Ankur Sharma, D K Dwivedi and Pankaj Gupta
Division of TVCC, FVSc& AH, SKUAST-J, R S Pura-Jammu 181102
kushwaharb76@gmail.com

An adult heron bird weighing about 300 gms was found near the pond and unable to walk and fly brought to the Teaching Veterinary Clinical Complex, FVSc and AH, R S Pura Jammu. On clinical examination, there was an abnormal movement in the midshaft of the left tibia, bruise injury in the region of proximal tibia and inability to bear weight. Radiograph of left tibia in two orthogonal views revealed midshaft transverse fracture. The bird was anaesthetized with ketamine hydrochloride @ 40 mg/kg body weight. After aseptic preparation of the left tibia bone, 1.5 mm pin (K-wire) was inserted from the proximal extremity at medial tibial plateau and first passed into proximal fracture fragment and then distal fragment was reduced externally and pin was advanced into distal fragment. The extra pin was cut from the proximal site. Post-operatively, inj. meloxicam @ 0.25 mg/kg body weight and enrofloxacin @ 5 mg/kg was administered intramuscularly. Post-operative follow-up could not be done as bird flew after few days.

POST-13

SUCCESSFUL CLINICAL MANAGEMENT OF DYSTOCIA IN NANITISNAKE

S.S.Pawar and Vende S.S.
Veterinary Polyclinic, Nashik
Maharashtra, INDIA
sspawar339@rediffmail.com

Herpetology is a rapidly growing interest in this country, reptiles being kept both for research purposes and as pets. Breeding snakes for fun and/or profit is becoming common place for reptile enthusiasts. Complications with laying eggs or giving birth to young are common sequelae of breeding snakes. A clinical case of Nanitisnake breed was presented at Veterinary Polyclinic Nashik having symptoms of swelling at anus region and Owner was complaining about the difficulty in free moving of the snake. On clinical examination snake was found with eggs obstruction. After proper diagnosis, decision was made to apply Pendistrin-SH tube for the proper lubrication to remove the obstructed eggs and with this proper lubrication all the eggs were removed gently one by one. After relieving the eggs snake was completely recovered. By viewing this case it was concluded with the thought that the consulting veterinarian should be familiar with the literature on the common methods for initiating breeding activity and cycling, gestation, fecundity, and incubation techniques for the various species of snakes seen in practice.

POST-14

EXTRACTION OF ECTOPIC TOOTH IN AN INCISOR TOOTH IN A MACAQUE MONKEY

Sanjay J. Gaikwad
Regional Joint Commissioner of Animal Husbandry, Aurangabad, Maharashtra
sj66gaikwad@gmail.com

A macaque female monkey was rescued and referred to the clinic. After examination it was revealed that there was ectopic incisor tooth to the left. She was tranquilized using Inj.Ketamine@ 10mg/kg B.W. IM. The head was secured properly and the patient was subjected to radiography to confirm the ectopic tooth attachments. The tooth was extracted. The female recovered after one hour. Post operatively Inj.Tetanus toxide and long acting Inj. Benzathine penicillin 3 Lac were given parentally. The female macaque showed an uneventful recovery. She was released into her natural habitat by the forest department officials after a week of observation.

POST-15

FRACTURE AND WOUND HEALING IN CIVET CAT

Sanjay J.Gaikwad
Regional Joint Commissioner of Animal Husbandry,
Aurangabad, Maharashtra
sj66gaikwad@gmail.com

A female civet cat was presented with burn injuries. Both the hind limbs were burnt. At the level of the hock joints were muscles, bones and ligaments were exposed. Fracture of tibia was noticed. The wounds were washed, cleaned with antiseptic solution and luke warm normal saline. Both the joints worse fixed at 45 degree angle with the help of specially designed wire splints and adhesive tape. Antibiotic Inj.Streptopenicillin was given for five days. Periodically dressing was carried twice a week. After complete healing of wounds the cat was released in its natural habitat after 45 days.

POST-16

ADMINISTRATION OF SALINE IN A PEACOCK

Sanjay J.Gaikwad
Regional Joint Commissioner of Animal Husbandry,
Aurangabad, Maharashtra
sj66gaikwad@gmail.com

A peacock was rescued by forest officials and on physical examination it was comatosed due to severe diarrhea and dehydration.It was given isotonic maintenance saline for three days along with antibiotics and B-complex parenterally. Orally sweet corn extract and fruit juices were provided.Peacock showed marked recovery after three hours. Oral rehydration was continued along with parental injections. Peacock recovered fully to its normal health after a week.Then it was released in the natural habitat after 15 days by forest officials.

POST-17

RECONSTRUCTION OF FRACTURED PALATE IN A MONGOOSE

Sanjay J.Gaikwad
Regional Joint Commissioner of Animal Husbandry,
Aurangabad, Maharashtra
sj66gaikwad@gmail.com

A mongoose was injured in a scooter accident. Due to the injury it was bleeding from the mouth and was in shock. It was brought to clinic and was sedated by Inj. Xylazine 1mg/kg BW and Inj.Ketamine 20mg /Kg body weight. On examination a

fracture of the upper palate was seen. The reconstruction of cleft palate was done by using 4/0 braided nylon and long acting penicillin was given parenterally. Feeding and watering was done regularly. The mongoose recovered eventually. After 15 days it was released by forest officials.

POST-18

REMOVAL OF TWO FISH HOOKS FROM THE INDIAN COBRA MOUTH

Sanjay J.Gaikwad
Regional Joint Commissioner of Animal Husbandry,
Aurangabad, Maharashtra
sj66gaikwad@gmail.com

A cobra presented to clinic with history of engulfing two fishing hooks along with a frog. After examining we located one small hook in the oral cavity anchored in the mucous membrane fold which was removed carefully. But it was very difficult to locate the second hook. It could be palpated in the neck region, but considering chances of tissue tearing we anaesthetized the cobra withInj.Ketamine@20 mg/Kg BW. Soon after effect of anaestheic within 15 min the hook was located and removed with the thumb. The string was pulled slightly, carefully and the point of the hook was pushed left laterally to prevent tracheal puncture and then lifted up. It was pulled through an oesophagotomy incision. The visible pointed U-part was cut with the help of wire cutter. The string and the remaining part of the hook were pulled out slowly through the mouth. This way after removing both the (small and big) hooks the cobra was observed till full recovery. Aseptic precautions were taken during operation. Dressing with Pendistrin SH ointment. Recovery of the cobra was uneventful. It was kept for seven days then; it was released in its natural habitat .This way we could save the Cobra.

POST-19

RESCUE OF A MALE MACAQUE MONKEY

Sanjay J.Gaikwad
Regional Joint Commissioner of Animal Husbandry,Aurangabad, Maharashtra
sj66gaikwad@gmail.com

A male macaque monkey was troubling villagers .He bit more than 50 peoples from the village those who ever passing from the area.As we know the monkey is very clever, cunning and alert species. That was very challenging rescue operation. He was very familiar with one old man and came and sat on his vehicle’s bonnet. Taking

advantage we tranquilized through the vehicle window using Inj.Ketamine 10mg/kg body weight with the help of a blow pipe. After sedation he was caught with the help of a snare and then after recovery released by forest officials.

POST-20

MANAGEMENT OF EVISCERATION IN A SPARROW CHICK

Sanjay J.Gaikwad
Regional Joint Commissioner of Animal Husbandry,
Aurangabad, Maharashtra
sj66gaikwad@gmail.com

A sparrow chick was rescued and brought for treatment. On examination revealed an evisceration.As the chick was very small, local anaesthesia 2percent xylocaine was use. The eviscerated intestinal parts were repositioned and muscle and skin were closed using 5/0 absorbable vicryl and skin sutured with 5/0 nylon. Periodic dressing and oral antibiotic administration was continued for five days. Stitches were removed after 10 days. The chick eventfully recovered completely.

POST-21

RESCUE OF A FOX FROM THE WELL

Sanjay J.Gaikwad
Regional Joint Commissioner of Animal Husbandry, Aurangabad, Maharashtra
sj66gaikwad@gmail.com

An Indian Fox had fallen in the well and was noticed by a farmer as he called out. After reaching at the spot it was seen that the fox was sitting on the side wall. Well walls were uneven so it was very difficult to see the fox from the boundary of the well. It was decided to lift it from the well. The fox was very aggressive so it was given light dose of sedation with the help of blow pipe. As soon as it became quiet we used nylon 5'*5' net and lifted the fox out immediately. The fox was rescued safely and then it was released after complete recovery by the forest officials.

POST-22

RESCUE OF A LEOPARD CUB FROM WELL (SURGANA)

Sanjay J.Gaikwad
Regional Joint Commissioner of Animal Husbandry, Aurangabad, Maharashtra
sj66gaikwad@gmail.com

A leopard cub, 7-8 months old had fallen in a well. It's cries were heard and a rescue team was deployed. Initially it was decided to take it out initially with the help of ladder. As the cub was exhausted it couldn't climb up so we placed a country made bed

tied with rope inside the well. Immediately it came and sat on it. The cub was rested for half an hour and the bed was pulled close to the corner so the cub could climb and jump out easily. The rescue operation was successfully done without any complication, though it took nearly 7-hours

POST-23

ANTI-MICROBIAL SUSCEPTIBILITY PATTERNS OF BACTERIAL AGENTS ISOLATED FROM WOUND AND SOFT TISSUE INFECTIONS IN CAPTIVE ELEPHANTS

S. Sundareshan[1*]., P. Sheela[1] and Vinay. S[2].
[1] Assistant Professor, Department of Veterinary Microbiology, Veterinary College, KVAFSU
[2] Senior Veterinary Ofiicer, Wildlife Division, Dept. of Forest, Shivamogga.
Department of Veterinary Microbiology, Veterinary College,
KVAFSU, Shivamogga – 577 204, Karnataka.
ssundareshan2@gmail.com

Skin wounds including foot ailments are one of the most commonly encountered pathological conditions in captive/ domesticated elephants. In the present study, clinical samples (n=22) of exudates/pus/swabs from skin wounds such as foot ailments, umbilical wound, vulval pustules and dermatitis as well as milk from a mastitis case collected from captive elephants engaged in elephant camp/ temples/ mutts were subjected to isolation and antibiogram studies. Bacterial/fungal isolates were isolated using standard microbiological procedures and identified based on phenotypic characteristics. *Streptococcus* species was the most predominant bacteria obtained followed by *Staphylococcus* species, *E. coli* and *Pseudomonas aeruginosa*. *Serratiam arcescens* and *Klebsiella pneumoniae* each were isolated in single cases. In a dermatitis case, fungal agents *viz*., *Aspergillus* species and *Geotrichum* species were isolated along with *Streptococcus* species. *In-vitro* antimicrobial susceptibility by disc diffusion method using commercially available antibiotic discs revealed that most of the streptococcal isolates were susceptible to enrofloxacin followed by ceftriaxone/cefotaxime and most of them were resistant to amikacin (72%) followed by ampicillin with cloxacillin. The study indicated *Streptococcus* species as the most predominant bacterial pathogen associated with wound and soft tissue infections in captive elephants and the existence of multi-drug resistant bacterial strains in such infections. The data on antibiotic susceptibility/resistance patterns of the bacterial isolates at species level is of immense value for effective therapy and management.

POST-24

AVIAN PROSTHETIC LEG - A NEW ERA IN WILD AVIAN CONSERVATION

Ushma Patel, Chetan Patond, S. V. Upadhye and S.B.Akhare
Department of Veterinary surgery and Radiology, Nagpur Veterinary College.
drushmapatel11@gmail.com

Birds often lose their appendages to kite string entanglement, electrocution and other traumatic injuries. A black kite with an amounted right leg was maintained at the local wildlife rescue shelter and was being treated for ulcerative pododermatitis in the contralateral leg. A prosthetic leg was designed to help the bird bear weight on the amputed leg. The kite recovered after 2 months of antibiotic treatment and now bears weight on both legs. An amputee male golden pheasant in the city zoo was perpetually on sternal recumbency as it could not bear weight on one leg. A polypropylene prosthetic leg was designed and fitted to the bird. The bird started walking around on day 2 of application of the leg. A peacock with malunion of tibiotarsal fracture was presented with no weight bearing on the affected leg. A customized polypropylene splint designed as a support brace was fitted on the affected leg. The bird showed immediate signs of weight bearing. 3D printed leg has been customized and designed for a bird with chronic contracture at the hock joint. The scope of veterinary avian prosthetics is immeasurable.

POST-25

SURGICAL MANAGEMENT OF CLOACAL PROLAPSE IN AN INDIAN FLAP SHELLED TURTLE *(Lissemys punctate sp.)*

Ushma D. Patel, Chetan V. Patond, Yash Bhate and Gautam Bhojne
Department of Surgery and Radiology, Nagpur Veterinary College, Nagpur
drushmapatel11@gmail.com

An adult male Indian flap-shelled turtle was presented with cloacal prolapse. The other important symptom observed was peeling off skin which was attributed to severe dehydration, resultant of the managemental anomalies. The turtle was anesthesized using isoflurane in a closed chamber. The prolapsed mass was cleaned, reduced and repositioned in the vent under general anesthesia with isoflurane in a closed chamber. Simple interrupted sutures using vicryl 3-0 were placed for four days to prevent re-occurrence. Oral enrofloxacin @ 5mg/kg and oral meloxicam @ 0.2 mg/kg were given for three days. Supportive therapy, rehydration, adequate sunlight and proper nutrition led to the fresh water turtle gaining full recovery and was released back in the wild. It could be concluded as the fresh water turtle is amongst the protected wild species of our

country and illegally raising it as a pet may/ can lead to severe life threatening condition due to insufficient knowledge / mis-management/ without understanding their managemental requirement.

POST-26

OPEN REDUCTION AND INTERNAL FIXATION BY PLATING IN A LEOPARD (*Panthera pardus)* AND A BLACK BUCK (*Antilope cervicapra*)

Upadhye, S.V., S.B. Akhare, GauriKhante, V.M. Dhoot, G.R. Bhojne, Tista Joseph and Ushma Patel
Teaching Veterinary Clinical Complex, Nagpur Veterinary College, Nagpur
shirishupadhye@gmail.com

Wildlife surgical cases with special reference to orthopaedic injuries have been on a rise along with the increase in human-wildlife conflict. This includes automobile accidents, illegal poaching snares, man-made structures etc. Although the basic principle of fracture reduction and immobilization remains the same as that of their domestic counterparts, conditions in wildlife requires different approach. The anaesthesia, postoperative care, self-immobilization, etc. are the issues to be addressed. Here two cases of long bone fracture, in a Leopard (*Panthera pardus)* and a Black buck (*Antilope cervicapra*) were operated and open reduction and internal fixation by plating was performed.

POST-27

SUCCESSFUL MANAGEMENT OF CROP LACERATION IN INDIAN ROCK PIGEONS (*Columba livia*) – A REPORT OF TWO CASES

Ushma Patel, Chetan Patond, Mayank Barde and S. B. Akhare
Department of Surgery and Radiology, Nagpur Veterinary College, Nagpur
drushmapatel11@gmail.com

Two Indian rock pigeons were brought in for treatment by voluntary rescuers on different occasions in the same week with similar wound on the neck. The first bird weighed 112 gm and on clinical examination it was observed that the wound was comparatively small but deep and hence required surgical closure. The second bird weighed 96 gm and it was observed that the wound was more extensive with irregularly lacerated deeper layers of crop. It could be inferred in case of both the birds, that the crop injuries were about a week old duration and birds were weak, dehydrated, debilitated with fetid odour and prominent keel bones. The pigeons were anaesthetized using a combination of Inj. Ketamine @ 10 mg/kg body weight and Inj. Diazepam @ 1

mg/kg body weight intramuscularly in a single syringe on the pectoral muscles. During the surgery the bird was restrained in supine position with the neck outstretched. The feathers around the wound were plucked under anaesthesia. The surgical site was prepared aseptically. A flexible crop tube was introduced from the oral cavity till the crop region to identify the lumen and correct apposition of tissues. The wound was freshened; skin was gently undermined and separated from the crop layer to avoid the skin tear. The crop was then sutured using Vicryl5-0 undyed using simple continuous fashion followed by a separate layer of skin. Post operatively the pigeons were kept on tube feeding for 3 days with the frequency of feeding Avian critical care formula five times daily, inj. Enrofloxacin@ 15 mg/kg body weight and inj. Meloxicam @ 2 mg/kg body weight intramuscularly for 5 and 3 days, respectively. Reconstruction of the crop wall by proper apposition and maintaining the patency of the GI tract with the help of flexible crop tube aided the complete recovery of the birds within 10 post operative days.

POST-28

SUCCESSFUL TUMOR REMOVAL IN AN INDIAN ROCK PIGEON *(Columba livia)*

Ushma Patel, Chetan Patond, Shirish Upadhye and S.B.Akhare
Teaching Veterinary Clinical Complex, Nagpur
drushmapatel11@gmail.com

An Indian rock pigeon *(Columba livia)* was rescued and brought to Teaching Veterinary Clinical Complex, Nagpur, with the history of a tumour mass on the lateral face on right side and inability to take flight. Clinical examination revealed a hard mass on it's face below the right eye extending upto the beak on the same side. The crop of the pigeon was not filled hence was operated upon the same day. General anesthesia was achieved using a combination of ketamine : diazepam (2:1) by intramuscular route. The incision was taken on the skin towards the stalk of the attachment and slowly undermined. Hemostasis was achieved using artery forceps and vicryl 4-0 suture material. The mass was completely separated from its attachment to the facial muscles. The muscles were sutured with simple interrupted pattern using vicryl 4-0 followed by skin suturing using simple continuous pattern with vicryl 3-0. The post operative antibiotics (enrofloxacin @ 15mg/kg body weight IM) was administered for five days and analgesics (meloxicam @ 1mg/kg body weight IM) for three days. Daily antiseptic dressing was done. The pigeon recovered uneventfully and was released back in the wild.

POST-29

SURGICAL MANAGAEMENT OF LACERATED WOUND IN A RUSSELL'S VIPER (*Daboia russelii*)

Ushma Patel, Aishwarya Betgiri, Shalaka Salvekar and Chetan Patond
Department of Surgery and Radiology, Nagpur Veterinary College, Nagpur
drushmapatel11@gmail.com

A Russell's viper (*Daboia russelii*) was presented at TVCC, Nagpur Veterinary College, Nagpur with a history of automobile accident. The rescuers handled it with snake tongs followed by the head catching method for thorough clinical examination which revealed presence of elongated laceration along the right side of the cranial ribs. The levator costa, iliocostalis, supracostalis lateralis superior and supracostalis lateralis inferio were found to be intact with slight abrasion while the major injury involved the skin and it's scales. Dirt and debris were flushed out using normal saline from the wound and scrubbed with povidone-iodine. Local infiltration with lignocaine 2% was done. The site was prepared aseptically. Soft tissues were sutured using Vicrylno.0. by simple interrupted pattern. As snake skin is elastic and more in ratio as compared to the anatomy of it's body and hence suture tension is observed to be less.Post-operatively,Inj. Meloxicam @ 0.2mg/kg body weight OD and Inj. Enrofloxacin @ 5mg/kg body weight OD for 3 and 5 days respectively were given. Post operatively, dressing was done for five days with Aluspray.

Immobilization by applying of bandage will interfere with it's feeding habits and it may suffocate snake hence the wound was not bandaged. The reptile recovered completely within 10 days and was released back into the wild with restoration of normal activities of the snake.

POST-30

SURGICAL MANAGEMENT OF FEMUR AND TIBIA FRACTURE ALONG WITH HIP JOINT DISLOCATION IN JUNGLE CAT (*Felis chaus*)

S.S.Jadhav[1], S.D.Sequeira[1], V.Sanghvi[1]
[1]JivdayaCharitable Trust, Ahmedabad, Gujarat
drshashijadhav@gmail.com

An adult jungle cat (*Felis chaus*) was admitted at Jivdaya Charitable Trust, Ahmedabad due to a road traffic accident. Complete clinical and radiographic examination, revealed right coxofemoral joint dislocation, midshaft transverse fracture of the right femur, and distal 1/3rd fracture with a small chip of the right tibia. The cat was

induced with intramuscular xylazine(2mg/kg)-ketamine(10mg/kg)combination and maintained on 1.5% isoflurane throughout surgery. The greater trochanter of the femur head was wired with ileum. Femur fracture was stabilized with titanium intramedullary pin size 3.0mm, while tibia was stabilized with 2.0mm size stainless steel pin by shuttle pinning method. The leg was secured externally with a splint by an aluminum rod. Preoperatively and postoperatively, the cat was maintained on parenteral fluids, tramadol, meloxicam, enrofloxacin, oral clindamycin, and calcium supplement. Postoperative x-rays were taken every fifteen days to assess the bone healing process. Soft callus was palpable on the 20th day. To restrict the movement, the cat was initially kept in a small cage for thirty days and later shifted to a big cage for routine movement and physiotherapy. The feeding and bodyweight of the cat were monitored throughout the period of cage rest. Muscle atrophy was noticed in the affected leg due to cage restriction and splinting, which improved after shifting to a large cage. After eighty days the cat was released back to the wild.

POST-31

FEATHER IMPLANTATION IN SHIKRA *(Accipiter badius)*

S.S. Jadhav and S. Everett
[1]Jivdaya Charitable Trust, Ahmedabad
drshashijadhav@gmail.com

An adult female Shikra *(Accipiter badius)* was admitted to Jivdaya Charitable Trust, Ahmedabad, with 9 of its flight feathers missing due to entanglement in kite string. Feather imping a nearly forgotten falconry technique, mainly for raptors, was used to repair the feathers. The beginning primaries, labelled as P2 to P6 were damaged right above the feather shaft and the secondaries labelled as S1 to S3 were missing from mid-shaft. Donor feathers collected from a dead shikra of the same sex and size were used. The under wing barring pattern was used as reference to set the feather exactly at the spot of breakage and to merge with the pattern and flow of the feather for a smooth flight. Thin bamboo needles were shaped and inserted into the broken end and the donor feather shaft joining them together by superglue. A small strip of paper was placed under the shaft while gluing to avoid damage to the rest of the feathers. Each feather was held in place, allowing it to dry and become secure. Entire process was done under isoflurane gas anaesthesia to allow less stress and restrict movement. After monitoring the take-off, landing and flight pattern in a large free flight aviary the shikra was released after 15 days. Feather imping allows the quick release of wild birds admitted with only feather damage rather than waiting for the feathers to grow back again, which can take upto a year.

POST-32

SUCCESSFUL TREATMENT OF ORGANOPHOSPHATE POISONING IN A PEAFOWL

Sakhare M. P[1]., Siddiqui M.F.M.F[1]., Shafi T.A. [1], Borikar S.T.[2], Sachin G. D.[3]and S. S. Lingayat[3]
1 Assistant Professor 2 I/C Professor 3 MVSc students
Department of Veterinary Preventive Medicine,College of Veterinary and Animal Sciences,
Maharashtra Animal and Fishery Sciences University,Parbhani 431 402(MS)
drmpsakhare@gmail.com

Organophosphate insecticide commonly used to control a variety of sucking, chewing and boring insects and spider mites on cotton, sugarcane, peanuts, ornamentals and tobacco and is extremely toxic to birds and is used as a bird poison. Although application of pesticides is meant for pests only, but non target species such as domestic and wild animals also get exposed to these pesticides. The peacock weighing around 4 kg was referred to department of Veterinary Medicine with history of respiratory distress, open mouth breathing and lateral recumbancy. As per history of farmer the peacock has eaten pesticide treated grains. On detailed clinical examination peacock revealed ataxia, dyspnoea, opisthotonus, muscular weakness, rectal temperature 107.2^{0}F, tachycardia and polypnea. On the basis of history and clinical signs the case was diagnosed as organophosphate poisoning. The peacock was treated Inj. Pheniramine maleate @ 0.5mg/kg BW I/M, Inj. Ceftriaxone @ 30 mg/kg im, Inj. Trivibet 0.3 ml im for 3 days, syrup Neuroquik 0.5 ml BID orally for 5-7 days. The peacock responded well to the therapy with normal appetite, behavior and recovered completely after 4th day of treatment.

POST-33

INVESTIGATION ON FOOT AND EYE PROBELMS IN ASIAN ELEPHANTS AT HAATHI GAON, JAIPUR

M Karikalan, NS Manoharan[1], Arvind Mathur[2], Bhoj Raj Singh*, Prajna Panda[3], Muthamizh Selvan[3] and AM Pawde
Centre for Wildlife Conservation, Management and Disease Surveillance
ICAR- Indian Veterinary Research Institute, Izatnagar 243 122 UP India
*Incharge, Epidemiology Section, ICAR-IVRI
[1] Dr. N.S. Manoharan, Retd. Additional Director, Dept. of Animal Husbandry, Tamil Nadu
[2] Veterinary Officer, Nahargarh Biological Park, Jaipur, Rajasthan
[3] Project Elephant, MoEF& CC, New Delhi Govt. of India
karyvet11@gmail.com

HaathiGaon (or elephant village) designed in 2006 and was established in 2010 at the foothill of the Amer Palace and Fort near Jaipur, Rajasthan to house captive elephants

used for elephant rides at Amer fort registered under the Rajasthan Forest Department. Of the 98 elephants inspected, 42 captive elephants had foot problems, either in the form of mild nail cracks, nail compression or overgrown nails. Few elephants had flat foot pads due to erosion walking on concrete roads. In HaathiGaon, few elephants are kept in '*thans*' (Stall) with rubber mat floorings which are ecofriendly and good for elephant foot condition. A similar approach was advised to adopt in Amer Fort instead of the concrete road used for elephant rides. Deccamali oil (Neem oil- 1 lit, Garlic- 200gm, Camphor- 200gm and Deccamali raisin – 200gm) application is recommended for foot care of elephants. Of the 98 elephants inspected, 22 (22%) captive elephants had eye problems like corneal opacity, cataract etc. In some elephants, the eye problem was irreversible whereas in few elephants the condition was emerging. A total of 16 eye swabs were collected from the elephants having eye problems. All the swabs were subjected to bacterial isolation. The major bacteria identified were *Burkholderia cepacia*, *Staphylococcous intermedius* and *Klebsiella pneumoniae*. However, antibodies were detected only against *B. cepacia* in all the serum samples of same elephants indicating that it may be a cause of eye infection. Antibody titres for *B. cepacia*, ranged between 40 to 800. The bacteria was sensitive to gentamicin,ciprofloxacin, ceftriaxone, cefpodoxime, cefotaxime and imipenum but resistant to other cephalosporins, penicillins, tigecycline, colistin, amoxicillin, tetracycline and chloamphenicol. Eye problems could have been due to old age, trauma or nutritional deficiency. Supplements of Vitamin A and dietary supplements like carrot was suggested to owners. Eye drops and ointments like Sofracort and Ofloxacin eye drops, Chloromycetin eye applicaps, washing with normal saline solution and 1% boric acid solution was suggested depending on the merit of condition and severity of the case.

POST-34

COCCIDIOSIS IN PEAFOWL (*Pavo cristatus*)

Vanishree[1], Sujay CS[2] and Nikita Salian[3]

1. Veterinary Officer, Sri AtalBihari Vajpayee Zoological Park, Kamalapur, Hospet,Karnataka.
2. Veterinary Officer and incharge Assistant Director, Tiger and Lion Safari, Shimoga.
3. PG Scholar, MVSc Wildlife, Veterinary College Hebbal, Bangalore.

vanihiremath44@gmail.com

Coccidiosis is a protozoan disease of digestive track which affects multiple species. Spread of coccidiosis is usually through feco-oral route. Young animals affected with coccidiosis will show bloody diarrhea, weakness, reduced immunity and eventually die. But older animal can withstand the diseases. Peafowls are omnivores can get infection through contaminated food or carrier insects. This case report presents

Coccidiosis in adult peafowl. A healthy peafowl started showing nervous signs and died within 5 minutes. Post mortem examination revealed necrosed liver, mucus filled intestines with mild pin point hemorrhages. Impression smear examination of intestinal content revealed presence of coccidian ocyst. There was another death of 10 days old chick with no history of illness. On post mortem examination, large intestine was filled with mucus and tapeworms. Impression smear examination revealed the presence of coccidiao ocyst. Random fecal examination of asymptomatic birds also showed the presence of coccidiao ocyst (+++).Overall health and appearance of the birds in the enclosure was poor, Stunted growth, roughened feathers was seen. Mass treatment is carried out with amprolium and multivitamin supplements. Enclosure was sanitized. Regular random fecal sample examination monitored. There was improvement in the health of the birds after the treatment. Subclinical coccidiosis in adult birds can affect the growth and performance of the birds. Regular monitoring and treatment for coccidia can improve the overall growth and performance in the peafowl.

POST-35

THERAPEUTIC MANAGEMENT OF CANINE TRANSMISSIBLE VENEREAL TUMOR IN INDIAN GREY WOLF: A CASE STUDY

Ramesh Pandey, Abhijit Bhawal, Vikash Jayswal, Harshita Raghav, Sonu Sharma
National Zoological Park, New Delhi- 110003
harshitaraghav1995@gmail.com

Canine transmissible venereal tumor (CTVTs) is the type of tumor, suspected to have developed thousands of years ago in wolves and wild dogs through a mutation in the basic genetic material of the histiocytes. The most common cause of this tumor is direct contact with an animal with TVT, which includes sexual contact, licking, biting, and sniffing the tumor affected areas. A 6-year-old, male, Indian grey wolf at National Zoological Park, Delhi (NZP) was observedfor growth on penile region. Upon clinical examination, irregular thickening of the tissue and intermittent bleeding was observed. Tissue samples were collected for biopsy and FNAC. It was diagnosed with round cell tumor (TVT). For therapeutic management of CTVT, surgical removal and chemotherapy (Vincristine sulphate at weekly intervals at 0.02mg/kg b.w. I/V Diluted in 300ml DNS given at very slow rate) alongwith Inj. Avil, Inj. Eldervet I/V and Liv 52 P.O. was followed. The recovery was successful. History, Signalment, Tissue biopsy and FNAC are sufficient for making diagnosis and pursue treatment of this tumor for adequate control and management. More studies are required to understand the latent nature of tumor, which, under the presence of certain factor acting as catalyst, showed occurrence. Deciphering possible reasons and delineating managemental intervention required.

POST-36

A LARGE-BILLED CROW WITH BEAK DEFORMITY-A SIGHTING RECORD

Rushikesh R. Sankpal[#]*, Sfurti B. Raut*, Sayali R. Sankpal*
[#]Sinhgad College of Science, Pune
*B-20, Dairy Colony, TatyasoKore Nagar, Warananagar, Dist- Kolhapur
rushisankpal@gmail.com

A Large-billed crow belongs to family Corvidae and is a common bird to India. Reports are available on crows with beak deformities from different parts of the world. Beak deformity can be associated with over growth of keratin layer. It serves as an indicator of underlying environmental health concerns. We report a sighting record of a Large-billed Crow (*Corvus macrorhynchos)* with an abnormally elongated and down-curved upper beak. The crow was sighted on 05thJune 2020 at A/P- Tatyaso Kore Nagar, Warananagar, Tal- Panhala, Dist- Kolhapur, State- Maharashtra of India (16°52'04.7"N 74°13'03.5"E).The photo-documentation was successfully done. The crow was foraging and perching in the rural habitat with human habitation nearby. Beak deformities may affect the life processes of the crow and further studies are needed for understanding the causes of such deformity with respect to sighting place.

POST-37

Ω-3 FATTY ACIDS SUPPLEMENTATION IMPROVED ANTIOXIDANT STATUS, IMMUNITY AND REDUCED STRESS IN CAPTIVE INDIAN LEOPARD FED BUFFALO MEAT ON BONE DIET

S.M. Durge[1,2], Asit Das[2,3], S.K. Saha[2], A.K. Verma[2], Y. Bhardvaj[4] and V.M. Salunke[1]
[1]College of Veterinary and Animal Sciences, (M.A.F.S.U.), Udgir, Latur, Maharashtra- 413 517.
[2]Center for Advanced Faculty Training in Animal Nutrition, ICAR-IVRI, Izatnagar-243 122.
[3]Animal Nutrition Division, ICAR-National Dairy Research Institute, Karnal, Haryana-132 041.
[4]Pandit G.B. Pant High Altitude Zoo, Nainital, Uttarakhand-263 002.
sdurge5@gmail.com

Wild animals meat contains higher amount of ω-3 fatty acids and narrow ω-6:ω-3 ratio compared to domesticated buffalo meat. Indian leopards are being fed buffalo meat in captivity which is poor in ω-3 content. ω-3 fatty acids are well known to reduce risk of coronary heart disease, autoimmune diseases, cancer, hypertension as well as have positive effects on antioxidant status and immunity (Chen *et al*., 1996). A study was conducted at Pandit G. B. Pant High Altitude Zoo, Nainital, where Nine Indian leopards

were randomly distributed into 3 groups, based on replicated Latin square design comprising of 3 treatments, 3 periods and 3 sequences and 3 animals in each sequence. All the animals were fed normal zoo diet of buffalo meat on bone (BMB) at 2.5 kg/d/animal for 6 days a week (Sarode *et al*., 2018). Diets of the animals in group T_1, T_2 and T_3 were supplemented with either 13 g of tallow, 6.5 g of tallow and 6.5 g of fish (4% of total EE), or 13 g of fish oil (8% of total EE), respectively. Supplementation of fish oil did not affected palatability and average daily BMB consumption was similar among the groups. Serum total antioxidant capacity, catalase activity, lymphocyte transformation test index and serum concentration of immunoglobulin were increased ($P<0.001$) in T_2 and T_3; whereas, serum concentration of Malondialdehyde and fecal concentration of cortisol decrease ($P<0.001$) in T_2 and T_3. Hence, concluded that, supplementation of fish oil at 6.5 g would improve antioxidant and immune status and would alleviate stress in captive Indian leopards fed solely on BMB diets. However, supplementation of fish oil at 13 g did not manifest any additional benefits.

GLIMPSES OF WRTC

वन्यजीव संशोधन व प्रशिक्षण केंद्र
गोरेवाडा प्रकल्प, नागपूर

महाराष्ट्र पशु व मत्स्य विज्ञान विद्यापीठ, नागपूर
व
महाराष्ट्र वन विकास महामंडळ, नागपूर
यांचा संयुक्त उद्यम

गोरेवाडा वन्यप्राणी बचाव केंद्र परिसर
हिंदुस्तान लिव्हर गोडाऊन चौक, फेटरी, माहुरझरी रोड, नागपूर - ४४१५०१

WILDLIFE RESEARCH & TRAINING CENTRE
GOREWADA PROJECT, NAGPUR

A Joint Venture of
MAHARASHTRA ANIMAL & FISHERY SCIENCES UNIVERSITY, NAGPUR
&
FOREST DEVELOPMENT CORPORATION OF MAHARASHTRA Ltd., NAGPUR

Gorewada Rescue Centre Campus
Hindustan Lever Godown Square, Fetri, Mahurzari Road, Nagpur-441501
E-mail ID. : wrtchospital@gmail.com, Phone No. : 0712-266 7422

VISIT OF DIGNITARIES

VISIT OF DIGNITARIES

VISIT OF DIGNITARIES

HAND REARING OF ORPHANS

FACILITIES CREATED AT WRTC

RELEASE OF DOCUMENTARIES

TRANSLOCATION

TRANSLOCATION

WEBINARS

Maharashtra Animal & Fishery Sciences University, Nagpur
&
Forest Development Corporation of Maharashtra Ltd., Nagpur
Wildlife Research & Training Centre, Gorewada, Nagpur
International Wildlife Webinar
Dr. Fabiola Quesada
Elephant and Rhino Chemical Immobilization, Capture and Transportation
Date :- 19th June, 2020
Time :- 16.00 IST
JOIN
http://wrtc.in
: Organizing Committee, WRTC :
Chairman & Convener
Organizing Secretary
Co-Organizing Secretaries

Maharashtra Animal & Fishery Sciences University, Nagpur
Nagpur Veterinary College, Nagpur
Department of Veterinary Clinical Medicine, Ethics & Jurisprudence,
Wildlife Research and Training Centre, Nagpur
in association with
Indian Society for Veterinary Medicine(ISVM)
organises
International Webinar on
"Causes of Elephant Calf Mortality"
On the occasion of
International Elephant Day
By
CLICK HERE TO REGISTER
"Elephant Lady"
Dr. Khyne U Mar
Webinar Link : www.evmed.in
Whats app for any query : +91 9881136550
Email : bedmedvet@gmail.com
Webinar date and time : 12th August, 2020, 4.00 pm (IST)
E-certificate will be issued to the participants and sent to their email within fortnight.
Convener & Chairman : Dr. S. V. Upadhye
Chief Organizing Secretary : Dr. V. M. Dhoot, Head
Organizing Secretaries : Dr. G. R. Bhojne, Dr. Shalini A. Chauhan, Dr. C. G. Panchbhai and Dr. Kalyani Thakur

Maharashtra Animal & Fishery Sciences University, Nagpur
&
Forest Development Corporation of Maharashtra Ltd., Nagpur
Wildlife Research & Training Centre, Gorewada, Nagpur
OUR INSPIRATION
International Wildlife Webinar
Emerging Viral Threats From Wildlife & Role of Vets in Preventing Future Pandemics.
DR. PRANAV PANDIT
Ph.D. School of Veterinary Medicine, UC Davis, California (USA)
Date :- 20th August, 2020
Time :- 20:00 IST
JOIN
http://wrtc.in
: Organizing Committee, WRTC :

MAHARASHTRA ANIMAL & FISHERY SCIENCES UNIVERSITY, NAGPUR
FOREST DEVELOPMENT CORPORATION OF MAHARASHTRA LTD., NAGPUR
JOINT VENTURE INSTITUTE
WILDLIFE RESEARCH & TRAINING CENTRE, GOREWADA, NAGPUR
&
INDIAN SOCIETY FOR STUDY OF ANIMAL REPRODUCTION
(MAHARASHTRA CHAPTER)
KNOWLEDGE PARTNER - INTAS ANIMAL HEALTH
JOINTLY ORGANISE INTERNATIONAL WEBINAR ON
"Assisted Reproduction: A Tool for the Conservation of Wild Felids"
- SPEAKER -
Isabel Calisalta Rodriguez
DVM, PhD Wildlife Reproduction Postdoctoral Research Fellow, Mammal Research Institute University of Pretoria, South Africa
- CHIEF PATRONS -
Col. (Prof.) Dr. A.M. Paturkar
Hon'ble Vice- Chancellor
Maharashtra Animal & Fishery Sciences University, Nagpur.
Dr. N. Rambabu
Hon'ble MoFF & Managing Director, FDCM Ltd., Nagpur.
- PATRONS -
REGISTER NOW
- ORGANIZING COMMITTEE -
CHAIRMAN & CONVENER
Dr. S. V. Upadhye
Director, WRTC, MAFSU, Nagpur.
CHIEF ORGANIZING SECRETARIES
Dr. M. S. Patil, Dr. Nitin Bhatia
ORGANIZING SECRETARIES
Dr. S. K. Sahatpure, Dr. A. P. Gawande, Dr. D.S. Raghuwanshi
JOINT ORGANIZING SECRETARIES
Dr. M. D. Pawshe, Dr. Sujit Kolangath, Dr. Shalini AS
Wednesday - 26/08/2020
4.00 PM (IST)

Maharashtra Animal & Fishery Sciences University, Nagpur
&
Forest Development Corporation of Maharashtra Ltd., Nagpur
Wildlife Research & Training Centre, Gorewada, Nagpur
WILDLIFE WEEK CELEBRATION - 2020 (Day - 1)
National Wildlife Webinar
Indian Biodiversity & Conservation
SHAIK HUSSAIN
Freelance Researcher and Conservationist
Date :- 01st October, 2020
Time :- 18:00 IST
JOIN
http://www.wrtc.in
: Organizing Committee :

Maharashtra Animal & Fishery Sciences University, Nagpur
&
Forest Development Corporation of Maharashtra Ltd., Nagpur
Wildlife Research & Training Centre, Gorewada, Nagpur
WILDLIFE WEEK CELEBRATION - 2020 (Day - 5)
International Wildlife Webinar
Dr. Fabiola Quesada
Wildlife Health & the role of Veterinarians in One Health
Date :- 05th Oct., 2020
Time :- 19.00 IST
JOIN
http://www.wrtc.in
: Organizing Committee :

Maharashtra Animal & Fishery Sciences University, Nagpur
&
Forest Development Corporation of Maharashtra Ltd., Nagpur
Wildlife Research & Training Centre, Gorewada, Nagpur
WILDLIFE WEEK CELEBRATION - 2020 (Day - 2)
National Wildlife Webinar
Storytelling of Science and Conservation
PRASENJEET YADAV
National Geographic Photographer and an Explorer
Date :- 02nd October, 2020
Time :- 16:00 IST
http://www.wrtc.in
: Organizing Committee :

Maharashtra Animal & Fishery Sciences University, Nagpur
&
Forest Development Corporation of Maharashtra Ltd., Nagpur
Wildlife Research & Training Centre, Gorewada, Nagpur
WILDLIFE WEEK CELEBRATION - 2020 (Day - 6)
National Wildlife Webinar
Date : 6th October, 2020 I Time : 1600 Hrs. Onwards
Shri. GIRISH VASHISHTHA
Retd. IFO
Topic :
Protection of Wildlife by Law.
Shri. NITIN DESAI
Director, WPSI, Central India
Topic :
Illegal Wildlife Trade (Indian Context)
Shri. VISHAL MALI
IFO (Wildlife), Kolhapur
Topic :
Wildlife Crime Investigation
JOIN
http://www.wrtc.in
: Organizing Committee :

Maharashtra Animal & Fishery Sciences University, Nagpur
&
Forest Development Corporation of Maharashtra Ltd., Nagpur
Wildlife Research & Training Centre, Gorewada, Nagpur
WILDLIFE WEEK CELEBRATION - 2020 (Day - 7)
National Wildlife Webinar
Avifauna of Gorewada : A Virtual Tour
Shri. P. S. PAKHALE
Range Forest Officer Gorewada Project, Nagpur
Date :- 03rd October, 2020
Time :- 16:00 IST
JOIN
http://wrtc.in
: Organizing Committee :

Maharashtra Animal & Fishery Sciences University, Nagpur
&
Forest Development Corporation of Maharashtra Ltd., Nagpur
Wildlife Research & Training Centre, Gorewada, Nagpur
&
Gorewada Project, Nagpur
WILDLIFE WEEK CELEBRATION - 2020
1st to 7th October, 2020
National / International Wildlife Webinar Series
At Microsoft teams
at
http://wrtc.in
: Organizing Committee :
Chairman & Convener
Dr. S. V. Upadhye
Director, WRTC, Nagpur
Chief Organizing Secretary
Dr. V. M. Dhoot
Organizing Secretaries
Dr. A. P. Gawande
Dr. G. R. Bhojne
Dr. M. S. Patil
Joint Organizing Secretaries
Dr. B. K. Bhadane
Dr. S. M. Kolangath
Dr. M. D. Pawshe
Dr. G. S. Khante
Dr. A. S. Shalini

International Veterinary Student Association, Shirwal
celebrates
ANIMAL RESCUE &SHELTER APPRECIATION WEEK
6th November:
Stories of a shelter vet
Dr.Rohit Joseph
Head Vet Of Resq Charitable Trust
Dr.Indrakshi Banerjee
Resq Veterinarian
Nov 6th & 7th , 18:30 IST
Registration link-
https://docs.google.com/forms/d/e/1FAIpQLSf-sz6xqPQADVgtbW1TXs7tQqrw-OxR12d7tkIzTsmpL_i4R/viewform?usp=sf_link
Dr.Sujit Mathew Kolangath (M.V.Sc-Animal biotechnology at Wildlife Reasearch and Training Center,Gorewada, Nagpur)
7th November:
Rescue & Rehabilitation in Wildlife Conservation
YOU CAN'T BUY LOVE, BUT YOU CAN RESCUE IT

Maharashtra Animal & Fishery Sciences University, Nagpur
&
Forest Development Corporation of Maharashtra Ltd., Nagpur
Wildlife Research & Training Centre, Gorewada, Nagpur
INTERNATIONAL WILDLIFE WEBINAR
22nd November, 2020, 09:00 PM (IST)
Care, Management & Welfare of Marine Mammals and Bears
DR. LAURIE GAGE
Animal Care Centre and Big Cat Specialist, USDA, USA.
http://wrtc.in
: Organizing Committee :

HEALTH MANAGEMENT

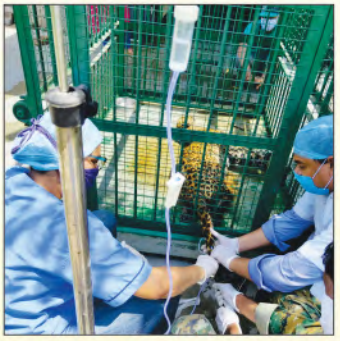




HEALTH MANAGEMENT

HEALTH MANAGEMENT

HEALTH MANAGEMENT

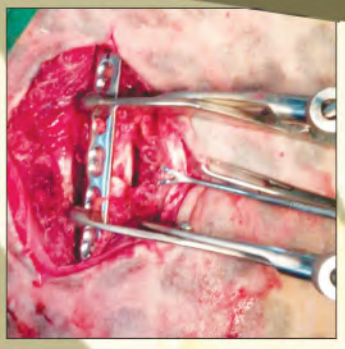

HEALTH MANAGEMENT

TRAININGS

TRAININGS

WILDLIFE WEEK CELEBRATIONS

MEDIA PRESENCE

नागपूर, गुरुवार, २६ नोव्हेंबर २०२०

नागपूर

गोरेवाड्यात वाघासह १५ वन्यप्राण्यांचा मुक्काम

प्राणिसंग्रहालयाचा श्रीगणेशा करण्याच्या हालचाली सुरू; वनमंत्री संजय राठोड यांच्याकडून नियमित आढावा

राजकुमारचे गोरेवाड्यात स्थानांतरण

सोबतीला महाराजबागची ली मिळणार

नागपूर, १० नोव्हेंबर

वाघ हा शिकार करून्च आपले पोट भरतो. पण एक वाघ शिकार कशी करायची हे शिकताच नाही. यामुळे त्याला नैसर्गिक अधिवासात सोडणे धोकादायक ठरू शकते. म्हणूनच अशा राजकमार नावाच्या वाघाचे

अवतीभवती

बचाव केंद्रात आला नवीन पाहुणा

नागपूर, ता. १३ : ब्रह्मपुरी वनविभागातील मेंडकी नियतक्षेत्र चिचखेडा येथे आईपासून विभक्त झालेल्या बिबट्याच्या बछड्याला आज गोरेवाडा प्राणिसंग्रहालयातील बचाव केंद्रात स्थलांतरीत केले. बचाव केंद्रात या बिबट्याच्या बछड्यावर पुढील उपचार केले जाणार असून त्याची काळजी घेतली जाणार आहे. उत्तर ब्रह्मपुरी परिक्षेत्रातील

ब्रह्मपुरी येथून आणलेले बिबट्याचे पिल्ल

या येथे २८ फेब्रुवारी २०१८ रोजी आईपासून ये बछडा आढळून आला. बछड्याला भावा म्हणून वन विभागाने प्रयत्न केले. थापन केली. दुसऱ्या दिवशी सायंकाळी हाणी केली असता आईच्या सहवासात ती

नवभारत

'साहबराव' के पैर का आपरेशन

गोरेवाड़ा बचाव केन्द्र में की प्रक्रिया

शहर संवाददाता

नागपुर. पिछले कई वर्षों से गोरेवाड़ा बचाव केन्द्र में रखे गए साहबराव बाघ के पैर का आपरेशन किया गया. बुधवार को सभी पशुचिकित्सीय डाक्टरों ने 9 वर्षीय बाघ के पैर का आपरेशन किया. दरअसल वर्ष 2012 में साहबराव नामक बाघ का पैर शिकारी के जाल में फंसने से उसकी उंगलियां टूट गई थी. पिछले

अपघातात जखमी अस्वलावर गोरेवाड्यात उपचार सुरू

नागपूर, १५ नोव्हेंबर

चंद्रपूर वनविभागातील मूल-चंद्रपूर राष्ट्रीय महामार्गावर वाहनाची धडक लागून जखमी झालेल्या नर अस्वलाला उपचारासाठी गोरेवाड्यातील वन्यजीव बचाव केंद्रात दाखल करण्यात आले.

चंद्रपूर वनविभागांतर्ग चंद्रपूर राष्ट्रीय महामार्गावर एका वाहनाची जोरदार धड एक अस्वल उडून झाले. अस्वलाला वनविभागाने ताब्यात घेत वैद्यकी करू उपचा टीमने

प्रजनन के लिए भेजा संजय गांधी 'सुल्तान' की दोपहर को मुंबई रवानगी

Separated leopard cub brought to Gorewada

Staff Reporter

ONE-AND-A-HALF month old leopard cub brought to Gorewada Rescue Centre

विदर्भाचा 'सुलतान' मुंबईला रवाना

गोरेवाड्यातील वाघ प्रजननासाठी बोरिवलीच्या राष्ट्रीय उद्यानात र

साहेबराव वाघावर दुसऱ्यांदा शस्त्रक्रिया

तीन बोटे निकामी; न्यूरोमा, संधिवाताचा त्रास

सकाळ वृत्तसेवा

नागपूर, ता. १ : ताडोबा-

'राजकुमार' जू में शिफ्ट

गोरेवाड़ा में दिसंबर के अंत में शुरू होगी इंडियन सफारी

शहर संवाददाता

नागपुर. देरी से सही लेकिन गोरेवाड़ा अंतरराष्ट्रीय प्राणी संग्रहालय में इंडियन सफारी शुरू करने की प्रक्रिया तेज हो गई है. शुक्रवार को पहली बार राजकुमार नामक एक नर बाघ को बचाव केन्द्र से गोरेवाड़ा जू में शिफ्ट किया गया. केन्द्रीय प्राणी संग्रहालय प्राधिकरण नई दिल्ली

तेंदुआ, भालू समेत

नागपूरच्या गुलाबी गारव्यात रुबाबदार 'राजकुमार'ची सैर

तीन वर्षानंतर मोकळा श्वास

3-yr-old tiger Sultan shifted from Gorewada to Borivli for breeding

Nagpur: Three-year-old tiger Sultan was finally shifted from Gorewada to Sanjay Gandhi National Park (SGNP) at Borivli in Mumbai on Tuesday. The tiger will be used for conservation breeding.

SAFE CAPTURE

Sultan (C), the cub of tigress T1, was captured on July 31, 2018, from Sindewahi range under Brahmapuri forest division after officials claimed it killed two villagers in June last year.

The tiger was captured and shifted to Gorewada Rescue Centre

Sultan, the cub of tigress T1, was captured in July from Sindewahi

A formal permission issued by state

TheHitavada

NAGPUR ■ Saturday ■ November 21 ■ 2020 CITY

'Rajkumar' shifted from Gorewada Rescue Centre to upcoming zoo

■ Gorewada zoo may be opened to public from last week of December or January

two male leopards and five leopardesses, six sloth bears -- three male and three female.

Rajkumar was shifted under the guidance of Dr Shirish Upadhye, Director, Wildlife Research and Training Centre, Gorewada Project; and Pramod

गोरेवाड़ा इंटरनेशनल जू

बाघ 'राजकुमार' सहित छोटे ... 15 वन्यजीव

गोरेवाड़ा प्राणिसंग्रहालयात 'राजकुमार' वाघाचे स्थलांतरण

लोकराजाही वार्ता / नागपूर

वन प्राणी बचाव केंद्र गोरेवाडा प्रकल्प येथील नर वाघ 'राजकुमार' याला गोरेवाडा आंतरराष्ट्रीय प्राणिसंग्रहालयात केंद्रीय चिडीयाघर प्राधिकरण नवी दिल्ली, यांच्या मार्गदर्शक तत्त्वांनुसार बछड्याचे स्थलांतरण करण्यात आले आहे.

गोरेवाड़ा जू लाया गया राजकुमार

6 तेंदुए एवं 7 भालू भी स्थानांतरित होंगे

'राजकुमार'चा मुक्काम गोरेवाडा प्राणिसंग्रहालयात

सकाळ वृत्तसेवा

नागपूर, ता. २० :

समावेश आहे

राजकुमार वाघ गोरेवाड्यात शि

डिसेंबरअखेर सुरू होईल इंडियन सफार

PAGE 1 ANCHOR

Surgery begins on a first: Artificial limb for Nagpur tiger

VIVEK DESHPANDE
NAGPUR, OCTOBER 9

A TEAM of experts, including from the Forest Department and the University of Leeds, has begun an operation to fix a prosthetic limb to a tiger in captivity. If all goes well over the next three-four weeks, experts say, this would be the first instance in the world where a tiger would get an artificial limb.

On Wednesday, local veterinarians, and orthopaedics and prosthetic limb expert from the University of Leeds, Peter Giannoudis, carried out a 25-minute surgical procedure to relieve the 7-year old tiger Sahebrao of pain on his left front leg.

Sahebrao had been rescued from a poacher's trap in Gondmohadi village in Chandrapur district in 2012. He had since developed gangrene, and a part of his injured leg had to be amputated in a surgery carried out in Nagpur. Since then, he has been living in captivity at the Wildlife Rescue Centre in Nagpur's Gorewada Zoo.

In 2016, Nagpur-based orthopaedic surgeon Sushrut Babhulkar decided to adopt the tiger. Since then, he had been working on the possibility of a prosthetic procedure to fix an artificial limb for the tiger. Subsequently, Babhulkar engaged with experts abroad, and the University of Leeds became a partner in the initiative.

"We had completed the first phase of the project with a radiographic study of his limb in February. On Wednesday, the second phase of the operation was started. Sahebrao was operated for neuroma and arthritis that was causing neuralgia (pain in the nerve)," Babhulkar told *The Indian Express*.

Sahebrao at the time of his rescue

"Now we will be able to fix the prosthetic limb within 3-4 weeks... the limb will be manufactured in Nagpur. We have taken all the necessary measurements," he said.

"I wish to see him walk normally, like a human being getting a prosthetic leg, for the rest of his life," he said.

Asked if experts from Leeds would come for the final phase of the operation, Babhulkar said: "Yes. There are some experts who have a vast experience of such operations on human beings."

Principal Chief Conservator of Forest (Wildlife) Nitin Kakodkar, Forest Development Corporation of Maharashtra's Managing Director Rambabu and other senior officials supervised Wednesday's operation performed by a team led by Shirish Upadhye.

RECOGNITION BY MEDIA

एनटी-१ नर वाघ गोरेवाड्यात

प्राणिसंग्रहालयात सकाळी सव्वा दहा वाजता आणण्यात आले. डॉ. भाग्यश्री भदाणे, डॉ. सुजित कोलंगथ, डॉ. शालिनी एस, डॉ. मयूर पावशे यांनी

गोरेवाड्यातील वाघ आता ठेवायचे

(पान १ वरून)

काय, हा प्रश्न प्रशासनासमोर निर्माण झाला असता. मध्यंतरी राज्यातील ५० वाघांच्या स्थलांतरणाचा मुद्दा पुढे आला. तेव्हा गोरेवाड्याचाही विचार

Problem tiger NT-1 brought to Gorewada from Talodhi range

10 tigers have been accomodated in Gorewada Rescue Centre, which has capacity to house nine tigers

Special Correspondent

A THREE-YEAR-OLD sub-adult tiger NT-1 that was tranquilised in Govindpur round of Talodhi/Nagbhid Forest Range, Brahmapuri Forest Division in Chandrapur district in evening, was brought to Gorewada Rescue Centre for treatment on Monday morning. This problem tiger had killed three persons in Nagbhid area — one in June and two in July — and created terror among the villagers. The people had seen this tiger roaming near the adjoining area of Talodhi in some days ago, indicating occurrence of man-animal conflict. Forest Department officials had sought permission from Kakodkar, Chief Wildlife Warden, for capturing the beast as it was creating a sense of security among the villagers.

Accordingly, Dr Ravikant Khobragade

preliminary examination after arrival of the tiger and found that the tiger was in sound condition. It was kept in the treatment cage with microchip. The doctors collected blood and other samples and shifted it to quarantine for observation by Dr Shirish Upadhye and his team of Wildlife Research & Training Centre. H V Madbhushi, Assistant Conservator of Forest, Gorewada; R P Bhiwgade, Range Forest Officer; R D Valthare, Forester; Harish Kinkar, R H Waghade, P C Pathrabe, Forest Guards; and otheers were present.

This is the third tiger to be tranquilised in the last one more tiger

गोरेवाड्यात वन्यजीव सप्ताह उत्साहात

नागपूर, ६ ऑक्टोबर

महाराष्ट्र पशु व मत्स्य विज्ञान विद्यापीठांतर्गत असलेल्या वन्यजीव संशोधन व प्रशिक्षण केंद्र, गोरेवाडा येथे वन्यजीव सप्ताह उत्साहात साजरा करण्यात आला. पाचवीच्या वन्यजीव सप्ताहाचे ... सहकार्याने ... या हे होते. ... पक्षी ... पाठ ... पार्थिवांनी ... घेतला. ... जाती.

प्रशिक्षण मार्गदर्शन करताना मान्यवर

... विद्यार्थ्यांना प्रमाणपत्र देऊन संचालक डॉ. शिरीष उपाध्ये यांनी रॅलीला हिरवी झेंडी दाखवली. विद्यालयाच्या ... व्यवसाय यावरून डॉ. विनोद धूत यांनी विद्यार्थ्यांना माहिती दिली. डॉ. गौतम भोजने यांनी बधिरीकरणासाठी वापरण्यात येणाऱ्या विविध उपकरणांबाबत प्रात्यक्षिकांतून माहिती दिली. पाठोळी गोरेवाडा येथे आयोजित कार्यक्रमात अध्यक्षस्थान डॉ. प्रा. आशीष पातुरकर यांनी भूषविले. तर प्रमुख अतिथी म्हणून महाराष्ट्र वनविकास महामंडळाचे व्यवस्थापकीय संचालक डॉ. रामबाबू, गोरेवाड्याचे विभागीय व्यवस्थापक नंदकिशोर काळे उपस्थित होते. गोरेवाड्यातील वन्यजीव सप्ताहाच्या उद्घाटनप्रसंगी गोरेवाडा संचालक डॉ. शिरीष उपाध्ये यांनी केंद्र स्थापनेचा इतिहास, उद्दिष्टे याबाबत माहिती दिली. संचालन डॉ. विनोद धूत यांनी तर आभार डॉ. ए. पी. सोमकुवर यांनी मानले. कार्यक्रमाच्या ... डॉ. निर्मल कुकुरे, डॉ.

'सुलतान' वाघ मुंबईकडे रवाना

संजय गांधी राष्ट्रीय उद्यानामध्ये प्रजननासाठी पाठविले

नागपूर. गोरेवाडा वन्यप्राणी बचाव केंद्रातील 'सुलतान' (सी-१) वाघाची मंगळवारी दुपारी ३ वाजताच्या बोरीवलीतील संजय गांधी राष्ट्रीय उद्यानाच्या रवानगी झाली. मस्तानी

गोरेवाड्यातील वाघ आता ठेवायचे कुठे?

लोकसत्ता खास प्रतिनिधी

नागपूर : गोरेवाडा बचाव केंद्रातील अतिरिक्त बिबट आणि अस्वलांना गोरेवाडा प्राणिसंग्रहालयात हलवण्याची परवानगी मिळाली, पण अतिरिक्त वाघांचा प्रश्न कायम आहे. ब्रम्हपुरी वनविभागातील

दहाही पिंजरे भरले

प्राधिकरणाची परवानगी

वन्यजीव संशोधन व प्रशिक्षण केंद्रात वन्यजीव सप्ताह

प्रतिनिधी, नागपूर

महाराष्ट्र पशु व मत्स्यविज्ञान विद्यापीठांअंतर्गत गोरेवाड्यातील वन्यजीव संशोधन व प्रशिक्षण केंद्रात विविध उपक्रम राबवून वन्यजीव सप्ताह पार पडला.

गोरेवाडा जैवविविधता उद्यानात पक्षी निरीक्षणाने सप्ताह ... दृष्टीने पशुवैद्यकीय महाविद्यालय व मत्स्य विज्ञान महाविद्यालयाच्या विद्यार्थ्यांनी मिरवणूक काढली. वन्यजीव संशोधन व प्रशिक्षण केंद्राचे संचालक डॉ. शिरीष उपाध्ये यांनी रॅलीला हिरवी झेंडी दाखवून सुरुवात केली. रामबाबू यांच्या हस्ते तर शल्यचिकित्सा विभागाचे उद्घाटन प्रा. आशिष पातुरकर यांच्या हस्ते झाले.

डॉक्टरों ने जनजागृति के लिए निकाली रैली

100 विद्यार्थियों को दी महा

धरमपेठ पशुवैद्यकीय कॉलेज से रैली निकालते वेटरनरी डॉक्टर व विद्यार्थी.

Captured tiger KT-1 shifted to Gorewada

Nagpur: KT-1, the problem tiger captured by the forest department from Tadoba Andhari Tiger Reserve (TATR) on Wednesday, was shifted to Gorewada rescue centre on Thursday afternoon. KT-1 had made five human kills in the last four months, including two kills

गोरेवाडा केंद्रात नवा पाहुणा दाखल

प्रतिनिधी, नागपूर

गोरवाडा आंतरराष्ट्रीय प्राणी संग्रहालयातील बचाव केंद्रात आणखी एका नव्या पाहुण्याचे आगमन झाले आहे. हा पाहुणा अवघ्या दीड ते दोन महिन्याचा असून येताक्षणीच त्याने सर्वांना लळा लावला. आईपासून दुरावलेला

मृत आढळून आला. ब्रम्हपुरी वनविभागातील परिक्षेत्र उत्तर ब्रम्हपुरी उपक्षेत्र मेंडकी नियतक्षेत्र चिचखेडा येथे २८ फेब्रुवारीला दुपारी दोन वाजताच्या सुमारास बिबट्याचे पिल्लू आढळून आले. मादी बिबटचा आसपास काहीच पत्ता नसल्याने या पिल्लासंदर्भात निर्णय घेण्याकरिता सात सदस्यांची समिती स्थापन करण्यात आली. एक मार्चला समितीने या पिल्लाची पाहणी केली आणि दोन दिवस मादी बिबट्याची वाट पाहण्याचे ठरवले.

या दोन दिवसात मादी बिबटचा वावर त्या परिसरात आढळला नाही. त्यामुळे चंद्रपूर येथील ट्रान्झिट ट्रिटमेंट सेंटरमध्ये त्याला आणण्यात आले. त्या पिल्लाचे आरोग्य आणि पुढील व्यवस्थापनाच्यादृष्टीने गोरेवाडा वन्यप्राणी बचाव केंद्रात आणण्यासाठी चंद्रपूरच्या प्रादेशिक मुख्य वनसंरक्षकांनी प्रधान मुख्य वनसंरक्षक (वन्यजीव) ए.के. मिश्रा यांना बिबट्याच्या पिल्लाला गोरेवाड्यात आणण्याची परवानगी मागितली. डॉ. खोब्रागडे यांच्या सहकार्याने हे पिल्लू आज, मंगळवारी गोरेवाड्यातील वन्यप्राणी बचाव केंद्रात आणले.

गोरेवाड्यात त्याचा प्रवेश होताक्षणीच पशुवैद्यकीय अधिकारी डॉ. विनोद धूत यांनी त्याची जबाबदारी स्वीकारली. अवघ्या दीड ते दोन

The Hitavada

NAGPUR ■ Wednesday ■ December 25 ■ 2019

Sultan C1 tiger shifted to Sanjay Gandhi National Park

Sultan C1tiger was shifted to Borivali on Tuesday.

■ Staff Reporter

SULTAN C1 tiger was shifted to Sanjay Gandhi National becoming a companion to th

A team of forest officers Barabde, Superintendent, Development Officer, and fie here on Tuesday. The officia Borivali team that took him i

The Chief Wildlife Warden to shift Sultan for genetic excl Park in March. The Central Z for production and transport November 12. Nandkishor K Development Corporation o Dr V M Dhoot, Dr Sujit Kolang A S, R P Bhiwgade, Range For active cooperation.

मानव-वन्यजीव सहजीवनाचा जागर

पशुवैद्यक विद्यार्थ्यांची आज रॅली; विविध उपक्रमांची रेलचेल

सकाळ वृत्तसेवा

नागपूर, ता. ४ : बदलत्या परिस्थितीत मानव आणि वन्यजीवांचा एकदुसऱ्यांच्या निवासक्षेत्रात वावर वाढला आहे. कुणालाही याबद्दल दोषी न धरता आपापल्या सीमारेषेचा आदर बाळगून दोघांनीही आपल्या ग्रीन झोनमधील सहजीवन शांतपणे जगावे, असे माफसूचे कुलगुरू डॉ. आशीष पातुरकर म्हणाले. गोरेवाडा वन्यजीव संशोधन व प्रशिक्षण केंद्रातर्फे १ ते ७ ऑक्टोबर या कालावधीत होत असलेल्या वन्यजीव सप्ताहातील विविध उपक्रमांची ते 'सकाळ'ला माहिती देत होते.

गोरेवाडातील प्रकल्पाबाबत २०१३ मध्ये माफसू आणि एफडीसीएम यांच्यात सामंजस्य करार झाला आहे. या ठिकाणी एक्स रे, सोनोग्राफी, कलर ड्रॉपर, ब्लड टेस्टिंगचे इक्विपमेंट आदी सुविधा असून बायोटेक्नॉलॉजी लॅब उभारली जाणार आहे. या प्रयोगशाळेत अद्ययावत यंत्रांची उपलब्धता असणार आहे.

या प्रकल्पाचा मुख्य उद्देश लुप्त होणाऱ्या वन्यप्राण्यांमध्ये सहाय प्रजनन, उपचारांसह शिक्षण संशोधन व प्रशिक्षणाची उपलब्धता, जीन व डाटा बँकिंगचे योग्य उपयोजन आदी आहेत. यंदा साजरा केला जाणाऱ्या वन्यजीव सप्ताहाची थीम 'लेट अस शेअर दी ग्रीन झोन थ्रू पीसफुल एक्सपेरिअन्स : सहजीवन' ही आहे. याअंतर्गत नागरिकांमध्ये जनजागृती केली जाणार आहे. तसेच विद्यार्थ्यांमध्ये कथा लेखन, चित्रकलेचे आयोजन केले असून शनिवारी (ता. ५) विद्यार्थ्यांची रॅली काढली जाणार आहे.

गोरेवाडा : वन्यप्राणी चिकित्सालय.

जागतिक स्तरावरचा प्रकल्प बनविणार

राज्यातील सर्वात मोठा प्रकल्प म्हणून गोरेवाडा वन्यजीव संशोधन व प्रशिक्षण केंद्राची ओळख आहे. रेस्क्यू सेंटर म्हणूनही केंद्राचे मोठे नाव आहे. या प्रकल्पास आंतरराष्ट्रीय पातळीचा बनविण्यासाठी आम्ही कटिबद्ध आहोत. सरकारचीही आम्हाला मदत मिळत आहे. या प्रकल्पामुळे विदर्भासह राज्याचे नाव जागतिक स्तरावर पोचेल असा विश्वास असल्याचे माफसूचे कुलगुरू डॉ. आशीष पातूरकर म्हणाले.

वन्यप्राणी आणि मानवातील संघर्ष कमी करण्यासाठी विविध उपाययोजना केल्या जात आहेत. ग्रीन झोनची संकल्पना चांगली असून सर्वांनी शांततापूर्ण सहजीवन व्यतीत करावे यासाठी विविध उपक्रम राबविले जात आहेत.
-डॉ. शिरीष उपाध्ये,
संचालक, वन्यजीव संशोधन व प्रशिक्षण केंद्र, गोरेवाडा

वन्यजीवांचे संवर्धन व संशोधनाला चालना देण्याचा प्रयत्न करण्यात येत आहे. याविषयीची जनजागृती आणि इत्थंभूत माहिती बालकांपासून ते ज्येष्ठांपर्यंत पोचणे काळाची गरज आहे.
-डॉ. विनोद धूत,
उपसंचालक, वन्यजीव संशोधन व प्रशिक्षण केंद्र, गोरेवाडा

विद्यार्थ्यांना वन्यजीवांचा सविस्तर अभ्यास व उपचारासंबंधी नवीन तंत्रज्ञान अवगत करून दिले पाहिजे. डाटा बँक, जीन बँकेच्या मदतीने नवीन बाबी अभ्यासता येणे शक्य आहे.
-डॉ. गौतम भोजने,
वन्यजीवतज्ज्ञ, वन्यजीव संशोधन व प्रशिक्षण केंद्र, गोरेवाडा

बाघ 'सुल्तान' की हुई रवानगी

ब्रीडिंग के लिए संजय गांधी राष्ट्रीय उद्यान भेजा गया

नागपुर। 24 दिसंबर। लोस सेवा

गोरेवाड़ा रेस्क्यू केंद्र के बाघ 'सुल्तान'की मंगलवार की दोपहर मुंबई के बोरीवली स्थित संजय गांधी राष्ट्रीय उद्यान के लिए रवानगी हो गई. प्राप्त जानकारी के अनुसार डॉ. एस.वी. उपाध्ये, डॉ. वी.एम. धूत, डॉ. सुजीत कोलगंथ, डॉ. मयूर पावशे, डॉ. शालिनी ए.एस. की टीम द्वारा स्वास्थ्य जांच की गई.

इसके बाद दोपहर 3 बजे बाघ को बोरीवली की टीम एक विशेष एंबुलेंस में लेकर मुंबई के लिए निकली. सुल्तान को नागपुर से मुंबई तक 900 कि.मी. की यात्रा तय करनी है. ऐसी स्थिति में उसे एक विशेष हायड्रॉलिक पिंजरे में रखा गया है. यात्रा के दौरान हर दो घंटे बाद सुल्तान के स्वास्थ्य की जांच की जाएगी. उसे आवश्यकता अनुसार खाद्य भी उपलब्ध कराया जाएगा. करीब ढाई साल पहले ब्रम्हपुरी के बाघ सी-1 यानी सुल्तान को उपद्रव करने के आरोपों के बाद ट्रैक्यूलाइज किया गया था. इसके बाद से उसे गोरेवाड़ा के रेस्क्यू सेंटर में एनक्लोजर में रखा गया था. उधर, संजय गांधी राष्ट्रीय उद्यान बोरीवली में तीन बघिन लक्ष्मी, बिजली और मस्तानी भी बिना साथी के थीं. इसके मद्देजनर केंद्रीय चिड़ियाघर प्राधिकरण के नियमानुसार तीनों बाघिनों के लिए एक बाघ साथी की बोरीवली नेशनल पार्क को आवश्यकता थी. इसे देखते हुए 14 मार्च 2019 में संजय गांधी राष्ट्रीय उद्यान बोरीवली ने पत्र लिखकर गोरेवाड़ा ▸▸ शेष पेज 3 पर...

गोरेवाड़ा के बाघ सुल्तान को बोरीवली स्थित संजय गांधी राष्ट्रीय उद्यान भेजने के लिए इस तरह पिंजरे में कैद किया गया, दूसरे चित्र में घूमता हुआ सुल्तान.

WRTC

WILDLIFE RESEARCH & TRAINING CENTER

Gorewada, MAFSU, Nagpur

www.wrtc.in